

Neurology Publish Ahead of Print

DOI: 10.1212/WNL.0000000000207673

Child Neurology: Anti-Hu Encephalitis in an Adolescent With a Mediastinal Seminoma

Author(s):

Veronica Cabreira, MD^{1,2}; Daniel Ferreira, MD^{1,2}; Cláudia Melo, MD^{3,4}; Joana Rebelo, MD⁵; Jacinta Fonseca, MD^{3,4}; Raquel Sousa, MD, PhD^{3,4}; Mafalda Sampaio, MD^{3,4}

Corresponding Author:

Veronica Cabreira, veronica.cabreira@gmail.com

Affiliation Information for All Authors: 1. Neurology Department, Centro Hospitalar Universitário de São João, Porto, Portugal; 2. Neurosciences and Mental Health Department, Faculty of Medicine, University of Porto, Porto, Portugal; 3. Neuropediatrics Unit, Pediatrics Department, Centro Hospitalar Universitário de São João, Porto, Portugal; 4. Department of Pediatrics and Gynecology-Obstetrics and, Faculty of Medicine, Universidade do Porto, Porto, Portugal; 5. Pediatric Oncology Department, Centro Hospitalar Universitário de São João, Porto, Portugal

Equal Author Contribution:

Verónica Cabreira and Daniel Ferreira are co-first authors.

Contributions:

Veronica Cabreira: Drafting/revision of the manuscript for content, including medical writing for content; Major role in the acquisition of data; Study concept or design; Analysis or interpretation of data

Daniel Ferreira: Drafting/revision of the manuscript for content, including medical writing for content; Major role in the acquisition of data; Study concept or design; Analysis or interpretation of data

Cláudia Melo: Drafting/revision of the manuscript for content, including medical writing for content; Study concept or design

Joana Rebelo: Drafting/revision of the manuscript for content, including medical writing for content

Jacinta Fonseca: Analysis or interpretation of data

Raquel Sousa: Drafting/revision of the manuscript for content, including medical writing for content; Analysis or interpretation of data

Mafalda Sampaio: Drafting/revision of the manuscript for content, including medical writing for content; Study concept or design; Analysis or interpretation of data

Figure Count:

2

Table Count:

1

Search Terms:

[60] All Epilepsy/Seizures, [61] Antiepileptic drugs, [131] All Immunology, [221] Paraneoplastic syndrome, [227] All Pediatric

Acknowledgment:

The authors thank Professor Josef Dalmau at Hospital Clinic, University of Barcelona, for his insight and contribution for this case diagnosis and management; Dr Ricardo Rego at the Refractory Epilepsy Center and Neurophysiology Unit of Centro Hospitalar Universitário de São João (CHUSJ) and Dr María Ángeles Pérez Jiménez at Hospital Infantil Universitario Niño Jesús in Madrid and for multidisciplinary discussions and their contribution to this case management; Dr Manuel Rito and Dr Josué Pereira at Neurosurgery Department of CHUSJ; Dr Jorge Pinheiro and Dr Roberto Silva at Neuropathology Department of CHUSJ; and Dr Cátia Morais at the Neuroimmunology Laboratory of Centro Hospitalar Universitário do Porto.

Study Funding:

The authors report no targeted funding.

Disclosure:

The authors report no disclosures relevant to the manuscript.

Preprint DOI:**Received Date:**

2022-11-21

Accepted Date:

2023-06-06

Handling Editor Statement:

Submitted and externally peer reviewed. The handling editor was Resident and Fellow Deputy Editor Ariel Lyons-Warren, MD, PhD.

Abstract

Anti-Hu antibodies are associated with autoimmune syndromes, mainly limbic encephalitis, encephalomyelitis and painful sensory polyneuropathy (Denny-Brown). We report a case of a 15-year-old boy presenting with *epilepsia partialis continua* (EPC) found to have a right middle frontal gyrus brain lesion without atrophy or contralateral involvement. Following partial resection, neuropathology revealed neuronal loss, reactive gliosis and astrogliosis, as well as perivascular mononuclear inflammatory infiltrate and features of neuronophagia resembling Rasmussen encephalitis. Suboptimal response to antiseizure drugs and surgery prompted further workup with identification of positive serum anti-Hu antibodies and a mediastinal seminoma. The patient was treated with immunotherapy including steroids, IVIG, azathioprine, rituximab and plasmapheresis as well as mediastinal lesion resection. However, he continued to experience EPC, psychomotor impairment along with left hemiparesis and dysarthria. Given clinical progression with failure to respond to immunotherapy and anti-seizure polytherapy, hemispherotomy was attempted and seizure freedom achieved. A review of the literature found only sixteen cases of neurological presentations associated with anti-Hu antibodies in children, confirming the rarity of EPC in these cases. Thus, this report provides a new observation of germ cell mediastinal tumour associated with anti-Hu antibodies in children broadening the spectrum of anti-Hu-associated neurologic disorder in children and highlighting the importance of considering antineuronal antibody testing in children presenting with EPC and brain lesions suggestive of Rasmussen encephalitis.



Anti-Hu antibodies are associated with autoimmune syndromes, mainly limbic encephalitis, encephalomyelitis and painful sensory polyneuropathy (Denny-Brown). We report a case of a 15-year-old boy diagnosed with a mediastinal seminoma presenting with *epilepsia partialis continua* (EPC).

Case report

A 15-year-old typically developing boy with no relevant past medical history presented with focal onset seizures with impaired awareness characterized by clonic movements of the left arm and face. Diagnostic workup included brain CT scan, brain MRI and EEG, which were initially unremarkable. Seizure frequency continued to increase despite treatment with multiple anti-seizure drugs (ASDs), evolving into uninterrupted myoclonic jerks of the left hand, compatible with EPC. A follow-up brain MRI scan 5 months later revealed a hyperintensity signal on T2-weighted and fluid attenuation inversion recovery (FLAIR) in the right middle frontal gyrus, without gadolinium enhancement or increase in relative cerebral blood volume (rCBV) on perfusion imaging, suggesting a low-grade infiltrative lesion (Figure 1A-C). No associated brain atrophy was found. The patient underwent a partial resection of the brain lesion. Neuropathology showed neuronal loss, reactive gliosis and astrocytosis, as well perivascular mononuclear inflammatory infiltrate and features of neuronophagia (Figure 2).

After surgery, he continued to experience myoclonic jerks of the left hand, a mild left central facial palsy and Medical Research Council (MRC) grade 4 left arm motor strength. EEG now showed a focal slowing in the right frontal region with 2-3Hz irregular activity and periodic sharp waves synchronous with the hand movements. Considering symptom persistence and the histological analysis, a comprehensive work-up was performed. CSF analysis showed 3 white blood cells, normal protein level (0.22g/L) and CSF glucose 58 mg/dL with serum glucose 84mg/dL. Systemic autoimmune studies and common infectious causes of encephalitis were unremarkable (eTable). Neuronal antibody testing revealed highly positive anti-Hu antibodies in the blood but was negative for other antibodies (eTable). Given anti-Hu antibodies, the patient was treated with 1g IV methylprednisolone (5-day course) followed by IV immunoglobulin (IvIG) 2g/kg (2-day course), oral prednisone 40 mg with slow progressive tapering and then azathioprine 150mg/daily. However, he continued to exhibit EPC with brachiofacial involvement. ASDs were progressively up-titrated to valproic acid 40 mg/kg, lacosamide 200 mg bid, perampanel 8mg and clobazam 20 mg. Given the suboptimal clinical response, rituximab 375 mg/m² IV was initiated alongside monthly courses of IvIG.

In the context of paraneoplastic screening, a chest, abdomen, and pelvis CT scan were performed and a large thymic mass with 53 x 35 x 90 mm was found (Figure 1F-H). Testicular ultrasonography and serum germinative neoplastic biomarkers (carcinoembryonic antigen, alpha-fetoprotein and human chorionic gonadotropin) were unremarkable. The patient underwent complete resection of the mediastinal mass and pathological analysis confirmed a mediastinal germ cell tumour compatible with a seminoma. Physical rehabilitation therapy was initiated as well as psychological support. Repeat evaluation of serum antibodies revealed a continued positive anti-Hu antibody, although decreased immunohistochemical staining compared with the first assessment. Chest imaging reassessment was negative for neoplastic relapses. After multidisciplinary discussion, disease monitoring with regular imaging was adopted.

Despite a transient initial improvement, nine months after mediastinal seminoma resection the patient's condition started to deteriorate including psychomotor impairment, significant functional impairment of his left hand due to seizures and weakness, and dysarthria. EEG confirmed frequent brachiofacial myoclonic jerks were EPC with occasional generalization. There was no epileptiform activity or abnormal activity from his left hemisphere. Follow-up

brain MRI scans at 6 (Figure 1D) and 22 (Figure 1E) months revealed increase in frontal right T2/FLAIR hyperintensity in addition to post-surgical inflammatory changes and a mild symmetric bilateral hemispheric atrophy. No progressive hemiatrophy was observed. Spectroscopy revealed an increase in choline peak and reduction in aspartate, suggestive of an inflammatory lesion. Ketogenic diet was started, alongside felbamate 1800mg bid, eslicarbazepine 1600mg/day, phenobarbital 100mg bid and clonazepam 0.25mg bid. Plasmapheresis was also attempted with no improvement in clinical status. Ultimately, vertical right perisylvian hemispherotomy was performed and seizure freedom achieved. As expected, he developed left hemiparesis and is currently undergoing neurorehabilitation. Neuropathology of the resected hemisphere again showed neuronal loss, reactive gliosis and astrocytosis, as well perivascular mononuclear inflammatory infiltrate and features of neuronophagia similar to the earlier resection.

Discussion

Anti-Hu typically presents in adults with small-cell lung cancer, although cases of anti-Hu limbic encephalitis associated with nonseminomatous mediastinal germinoma have been reported up to 9 years before tumor detection(8). Anti-Hu antibodies in children are rare(1-7)(Table). Additionally, only a limited number of cases described in the literature report an association between anti-Hu encephalitis and an identified tumour, with the majority being neuroblastoma in children under the age of 3(1,2,7).

While it was unclear in our patient if the mediastinal mass was related to the clinical picture, the fact that anti-Hu antibodies are directed at intranuclear antigens and pathogenically related to the presence of Hu-specific T cells, plus the initial response to immunotherapy and lesion resection, strongly advocate in favour of a paraneoplastic anti-Hu encephalitis related with the seminoma. Interestingly, Rasmussen Encephalitis (RE) is also a T cell-mediated disease suggesting a shared pathophysiologic mechanism. Moreover, the neuropathological findings in anti-Hu encephalitis are identical to those found in RE, which is a diagnosis of exclusion (9). However, the mild and non-progressive cortical deficits before hemispherotomy, plus the absence of progressive unilateral cortical hemispheric atrophy, strongly disfavour RE in this case(9). Notwithstanding, unilateral signal abnormalities in the affected hemisphere have been described in a third of EPC patients diagnosed with RE(10).

To date, two cases of antibody-mediated inflammatory diseases mimicking RE have been described: one with anti-NMDA(11) and one with anti-Hu antibodies(5) although neither of them with associated malignancy as in our case. Other differential diagnoses for inflammatory lesions presenting with EPC include mitochondrial disorders, although in these EPC tends to present earlier, with distinguishing clinical features and bilateral EEG and imaging changes(10). Likewise, in children with anti-NMDA encephalitis, EPC presents with severe encephalopathy and complex movement disorders, and therefore is unlikely to account for isolated EPC(10). Moreover, to our knowledge only a few descriptions of the association between the anti-Hu paraneoplastic syndrome and EPC are described, mainly in adults, and without hemispheric atrophy or other RE resembling features(4, 12-14).

Currently, little is known regarding the best therapeutic strategy for these challenging cases. While the goal is to achieve optimal seizure control, prevent further brain atrophy, and preserve intellectual and motor performance, this must be balanced with iatrogenic immunotherapy risks, a particularly sensitive question when dealing with children. In the advent of immunotherapy failure, surgery indication is considered. As this is the first description of hemispherotomy in anti-Hu associated encephalitis, long term outcomes are unknown. Although, this procedure alone may not be sufficient to achieve seizure freedom

due to continuous antibody cytotoxicity(5), a probability higher than 70% of long-term seizure-free has been described for RE(15).

This case broadens the spectrum of anti-Hu-associated neurologic disorder in children. We highlight the importance of considering antineuronal antibody testing in children presenting with EPC, focal cerebral atrophy or hypersignal suggestive of RE, as well the need for an ongoing surveillance for malignancy in the presence of anti-Hu antibodies. Although prior reported cases may have involved undiscovered occult malignancies, to our knowledge, this is the first description of a pathology proven paraneoplastic autoimmune encephalitis associated with anti-Hu antibodies and EPC.

Author contributions

VC and DF wrote the manuscript. All authors planned this work and agreed with the final version. All authors were involved in the direct medical care for this patient.

Research ethics and patient consent

The study is exempt from ethics board review board approval. Written informed consent-to-disclose was obtained from the patient and his parents.

Data availability

The authors have full access and the right to publish all data contained in this manuscript, separate and apart from the guidance of any sponsor.

ACCEPTED

WNL-2023-000467_etab --- <http://links.lww.com/WNL/D19>

References

1. Sabanathan S, Abdel-Mannan O, Mankad K, Siddiqui A, Das K, Carr L, et al. Clinical features, investigations, and outcomes of pediatric limbic encephalitis: A multicenter study. *Annals of clinical and translational neurology*. 2022;9(1):67-78.
2. Honnorat J, Didelot A, Karantoni E, Ville D, Ducray F, Lambert L, et al. Autoimmune limbic encephalopathy and anti-Hu antibodies in children without cancer. *Neurology*. 2013;80(24):2226-32.
3. Capobianco M SF, Malentacchi M, Valentino P, Sala A, Gned D, De Pascale A, Bertolotto A. Anti-HU Antibodies Associated Focal Epileptogenic Encephalitis Successfully Treated with Rituximab: A New Limited form of Chronic Focal Encephalitis of the Rasmussen's Type? *Austin J Clin Neurol*. 2015;2(5): 1043.
4. Sweeney M, Sweney M, Soldán MM, Clardy SL. Antineuronal Nuclear Autoantibody Type 1/Anti-Hu-Associated Opsoclonus Myoclonus and Epilepsia Partialis Continua: Case Report and Literature Review. *Pediatric neurology*. 2016;65:86-9.
5. Aravamuthan BR, Sánchez Fernández I, Zurawski J, Olson H, Gorman M, Takeoka M. Pediatric anti-Hu-associated encephalitis with clinical features of Rasmussen encephalitis. *Neurology(R) neuroimmunology & neuroinflammation*. 2015;2(5):e150.
6. Langer JE, Lopes MB, Fountain NB, Pranzatelli MR, Thiele EA, Rust RS, et al. An unusual presentation of anti-Hu-associated paraneoplastic limbic encephalitis. *Developmental medicine and child neurology*. 2012;54(9):863-6.
7. Pranzatelli MR, McGee NR. Neuroimmunology of OMS and ANNA-1/anti-Hu paraneoplastic syndromes in a child with neuroblastoma. *Neurology(R) neuroimmunology & neuroinflammation*. 2018;5(2):e433.
8. Silsby M, Clarke CJ, Lee K, Sharpe D. Anti-Hu limbic encephalitis preceding the appearance of mediastinal germinoma by 9 years. *Neurology(R) neuroimmunology & neuroinflammation*. 2020;7(3).
9. Varadkar S, Bien CG, Kruse CA, Jensen FE, Bauer J, Pardo CA, et al. Rasmussen's encephalitis: clinical features, pathobiology, and treatment advances. *The Lancet Neurology*. 2014;13(2):195-205.
10. Sabanathan S, Abdel-Mannan O, Mankad K, Siddiqui A, Das K, Carr L, et al. Clinical features, investigations, and outcomes of pediatric limbic encephalitis: A multicenter study. *Ann. Clin. Transl. Neurol*. 2022;9: 67-78.
11. Greiner H, Leach JL, Lee KH, Krueger DA. Anti-NMDA receptor encephalitis presenting with imaging findings and clinical features mimicking Rasmussen syndrome. *Seizure*. 2011;20(3):266-70.
12. Shavit YB, Graus F, Probst A, Rene R, Steck AJ. Epilepsia partialis continua: a new manifestation of anti-Hu-associated paraneoplastic encephalomyelitis. *Annals of neurology*. 1999;45(2):255-8.
13. Jacobs DA, Fung KM, Cook NM, Schalepfer WW, Goldberg HI, Stecker MM. Complex partial status epilepticus associated with anti-Hu paraneoplastic syndrome. *Journal of the neurological sciences*. 2003;213(1-2):77-82.
14. Mut M, Schiff D, Dalmau J. Paraneoplastic recurrent multifocal encephalitis presenting with epilepsia partialis continua. *Journal of neuro-oncology*. 2005;72(1):63-6.
15. Lagarde S, Boucraut J, Bartolomei F. Medical treatment of Rasmussen's Encephalitis: A systematic review. *Rev Neurol (Paris)*. 2022;178(7):675-691.

Table. Review of the literature. Cases of anti-Hu antibody disease in pediatric populations.

Study	Gender, age	Presentation	Diagnostic work-up	Tumour	Treatment	Outcome and follow-up
Langer JE, et al; 2012	5-year-old, male	Episodic ataxia, behavioural changes, later temporal seizures	- MRI: temporal T2 hypersignal, no atrophy - CSF: no relevant changes - EEG: bilateral temporal seizures - Anti-Hu antibodies (+, serum)	No tumor identified at 2 years of follow-up	Six different ASD and immunotherapy: steroids, low-dose prednisone, rituximab, IVIg, dexamethasone	Normalization of serum anti-Hu titres 1 year after treatment. Oral steroids discontinued. Improvement of seizures and behaviour two years later.
Honnorat J, et al; 2013	Case series	Eight children with limbic encephalitis	- MRI abnormal in 4/6, with temporal T2/FLAIR hyperintensities - CSF: unpaired positive oligoclonal bands in 4 patients - Anti-Hu antibodies (+, serum)	Neuroblastoma in 2; 6 did not have tumor at 50 months	All 6 patients received ASD and immunotherapy	Epilepsy resistant to therapy in all of them; five developed cognitive impairment.
Aravamudan BR et al; 2015	5-year-old, female	Focal seizures of right face and arm; Right lower facial weakness, dysarthria, and cognitive decline	- EEG: left hemispheric slowing and frontotemporal seizures - MRI: left-greater-than-right hemispheric atrophy and T2 caudate hyperintensity - Anti-Hu antibody (+, serum and CSF)	No tumor identified.	- ASD: Levetiracetam and lacosamide - Immunotherapy: pulses of methylprednisolone, cyclophosphamide and mycophenolate mofetil.	Improvement of seizure frequency, facial weakness, and cognitive skills.
Capobianco M et al; 2015	5-year-old, female	Non-convulsive status epilepticus; left haemiparesis, choreoathetosis, dystonia and cognitive decline	- MRI: T2-hyperintensity in left frontal lobe - CSF oligoclonal bands - Elevated serum ANA (>1/640) - Anti-Hu antibodies (+, serum)	No tumor identified.	Immunotherapy: prednisone and rituximab	- No recurrence of status epilepticus; sporadic focal motor seizures - Slight improvement of paresis and choreoathetotic movements - Stabilisation of cognitive function
Sweeney M, et al; 2016	11-year-old, female	Opsoclonus-myoclonus syndrome, ataxia, and focal jerks of the left face and arm	- MRI: mesial temporal lobe and subsular hyperintensities in T2 FLAIR - EEG: epilepsy partialis continua - CSF pleocytosis - Anti-Hu antibodies (+, serum and CSF) - MRI: normal	Paraspinal ganglioneuroblastoma	- ASD: oxcarbazepine, levetiracetam, phenytoin, clobazam - Immunotherapy: oral prednisone, monthly IVIg, rituximab	After 1 year, she continued with ongoing subtle opsoclonus, mild ataxia, dysarthric speech and frequent focal seizures of the left face and hand.
Pranzatelli M, et al; 2017	16-month-old female	Limbic encephalitis and left focal seizures with impairment of awareness	- EEG: left temporal epileptic focus - Anti-Hu antibodies (+, serum and CSF) - Pathology: focal neuronal loss and gliosis, focal perivascular chronic inflammation and gliosis, and cortical temporal dysplasia	Neuroblastoma	- Multiple ASD - Immunotherapy: IVIg, prednisone, high-dose corticotropin, cyclophosphamide, rituximab - Surgery: left anterior temporal lobectomy	Serum antibodies remained high for 10 months before declining but persisted for years. Clinical improvement after rituximab, without seizures off antiseizure drugs and immunotherapy, and returned to school.
Frazzini V et al; 2019	15-year-old female	Focal left motor seizures progressing to bilateral seizures; myoclonic jerks (EPC)	- MRI: bilateral FLAIR hyperintense signals on the precentral gyri - Anti-Hu antibodies (+, serum and CSF) - EEG: interictal bilateral spike and waves, on the right frontal areas	No tumor identified.	- Several ASDs - Immunotherapy: steroids, IVIg, cyclophosphamide, rituximab, mycophenolate	After 10 years of follow-up, she presented moderate reduction of myoclonus
Sabanathan S et al; 2022	Case series of pediatric autoimmune limbic encephalitis	Two children with limbic encephalitis; one had a peripheral axonal neuropathy since infancy	- Anti-Hu antibodies (+, serum)	Neuroblastoma in one; in the second patient underlying malignancies were not identified	(no data provided)	The patient with neuroblastoma died.

ASD: antiseizure drugs; CSF: cerebrospinal fluid; MRI: magnetic resonance imaging.

Figure 1. MRI and CT imaging

Axial brain MRI T2-fluid attenuation inversion recovery (FLAIR) showing a right middle frontal gyrus infiltrative lesion (A), with corresponding T1 hypointensity, no enhancement after gadolinium (B) and no increase in relative cerebral blood volume (rCBV) on perfusion-weighted imaging (PWI) (C) (pre-surgery). Follow-up axial brain MRI T2-FLAIR at 6 (D) and 22 (E) months post-surgery revealing increased frontal right hyperintensity and a mild symmetric bilateral hemispheric atrophy.

Chest (F), abdomen (G) and pelvis (H) CT scan showing a large anterior mediastinal mass.

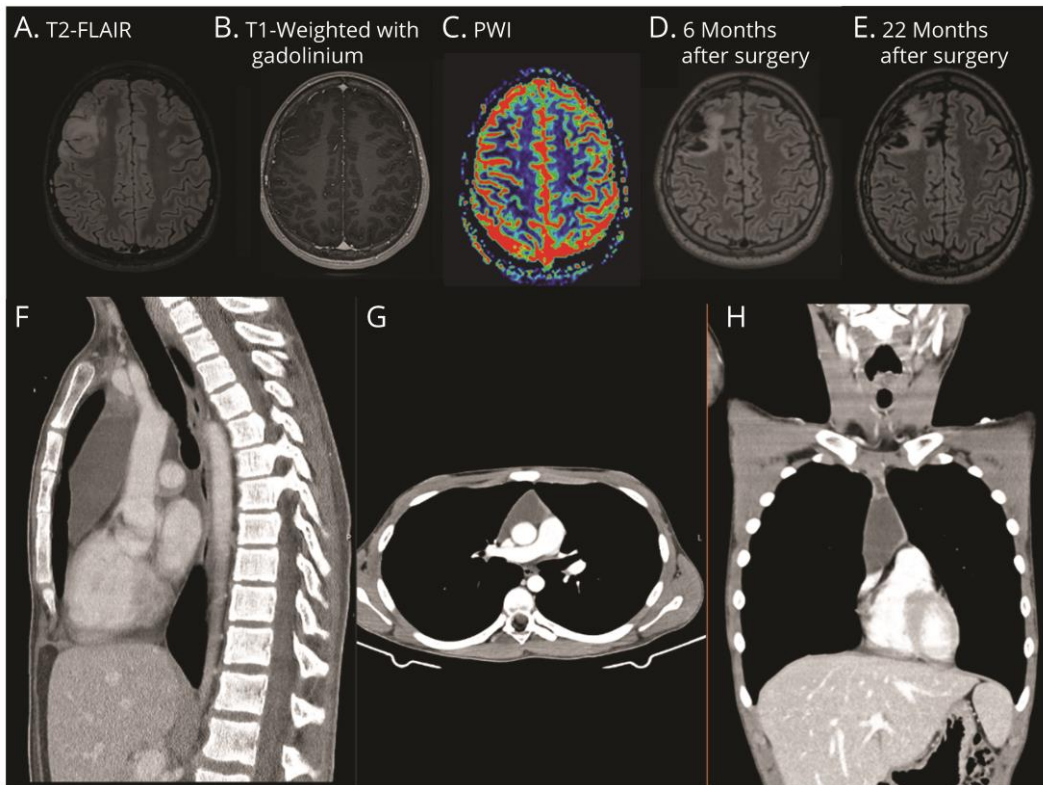
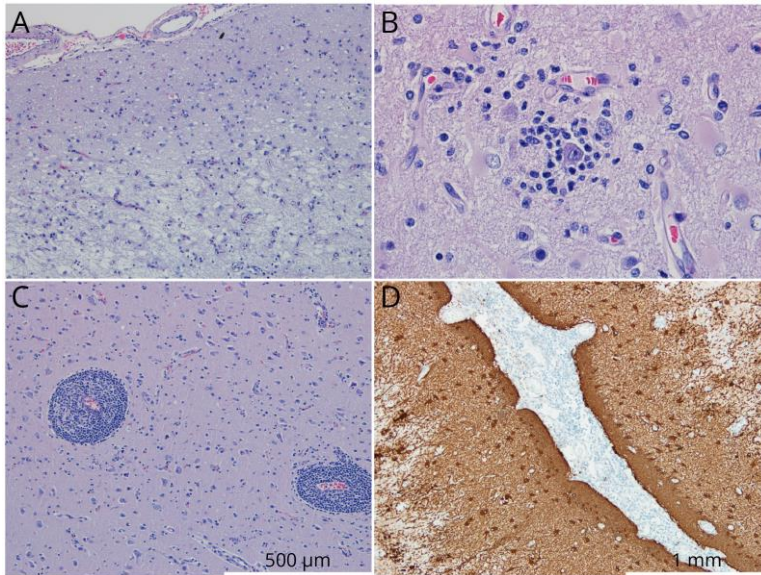


Figure 2. Neuropathology

Pathology analysis discloses increased cellularity and exuberant vascular network (HE-100X)(A), neuronophagia (HE-400x)(B), perivascular mononucleated inflammatory infiltrate (HE-200X)(C) and gliosis with reactive astrocytosis (GFAP - 400X)(D).



ACCEPTED

Neurology[®]

Child Neurology: Anti-Hu Encephalitis in an Adolescent With a Mediastinal Seminoma

Veronica Cabreira, Daniel Ferreira, Cláudia Melo, et al.

Neurology published online August 1, 2023

DOI 10.1212/WNL.0000000000207673

This information is current as of August 1, 2023

Updated Information & Services	including high resolution figures, can be found at: http://n.neurology.org/content/early/2023/08/01/WNL.0000000000207673.full
Subspecialty Collections	This article, along with others on similar topics, appears in the following collection(s): All Epilepsy/Seizures http://n.neurology.org/cgi/collection/all_epilepsy_seizures All Immunology http://n.neurology.org/cgi/collection/all_immunology All Pediatric http://n.neurology.org/cgi/collection/all_pediatric Antiepileptic drugs http://n.neurology.org/cgi/collection/antiepileptic_drugs Paraneoplastic syndrome http://n.neurology.org/cgi/collection/paraneoplastic_syndrome
Permissions & Licensing	Information about reproducing this article in parts (figures, tables) or in its entirety can be found online at: http://www.neurology.org/about/about_the_journal#permissions
Reprints	Information about ordering reprints can be found online: http://n.neurology.org/subscribers/advertise

Neurology® is the official journal of the American Academy of Neurology. Published continuously since 1951, it is now a weekly with 48 issues per year. Copyright © 2023 American Academy of Neurology. All rights reserved. Print ISSN: 0028-3878. Online ISSN: 1526-632X.

