

---

## Neurology Publish Ahead of Print

DOI: 10.1212/WNL.0000000000207647

### Child Neurology: Mucopolysaccharidosis IIID: Evidence From Ultrastructural and Genomic Study

#### Author(s):

Rashmi Santhoshkumar, PhD<sup>1</sup>; Rohan R Mahale, DM<sup>2</sup>; Pakina Krishna Kishore, MD<sup>2</sup>; Yasha T Chickabasaviah, MD<sup>1</sup>

#### Corresponding Author:

Yasha T Chickabasaviah, yasha\_muthane@yahoo.co.in

**Affiliation Information for All Authors:** 1. Dept. of Neuropathology, National Institute of Mental Health and Neurosciences, Bengaluru – 560 029, Karnataka, India; 2. Department of Neurology, National Institute of Mental Health and Neurosciences, Bengaluru – 560 029, Karnataka, India

#### Equal Author Contribution:

#### Contributions:

Rashmi Santhoshkumar: Drafting/revision of the manuscript for content, including medical writing for content; Major role in the acquisition of data; Study concept or design; Analysis or interpretation of data

Rohan R Mahale: Drafting/revision of the manuscript for content, including medical writing for content; Major role in the acquisition of data; Analysis or interpretation of data

Pakina Krishna Kishore: Major role in the acquisition of data

Yasha T Chickabasaviah: Drafting/revision of the manuscript for content, including medical writing for content; Major role in the acquisition of data; Study concept or design; Analysis or interpretation of data

**Figure Count:**

1

**Table Count:**

1

**Search Terms:**

[ 153 ] Metabolic disease (inherited), [ 191 ] Retina, [ 185 ] Muscle disease, Electron microscopy, Mucopolysaccharidosis IIID

**Acknowledgment:**

We thank the patient and family members for taking part in this study. We also thank Indian Council of Medical Research (ICMR), Govt. of India for funding the project- Human Skeletal Muscle Disease Biobank at our institution from where the tissue was archived for this study.

**Study Funding:**

The authors report no targeted funding.

**Disclosure:**

The authors report no relevant disclosures.

**Preprint DOI:****Received Date:**

2022-10-19

**Accepted Date:**

2023-05-31

**Handling Editor Statement:**

Submitted and externally peer reviewed. The handling editor was Resident and Fellow Deputy Editor Ariel Lyons-Warren, MD, PhD.

## **Abstract**

Mucopolysaccharidosis IIID (MPS IIID/ Sanfilippo syndrome D, OMIM # 252940), is an autosomal recessive lysosomal storage disorder (LSD) and the rarest form of the mucopolysaccharidosis (MPS) III subtypes. It is caused by mutations in the gene encoding lysosomal enzyme N-acetyl glucosamine-6-sulphatase (GNS). Deficiency of GNS impairs catabolism of glycosaminoglycans causing accumulation of heparan sulphate within lysosomes of various tissues which is visualized as membranous cytoplasmic bodies (MCBs) on electron microscopy. The recognition of this ultrastructural feature in a muscle biopsy instigated genetic evaluation for LSD in our case resulting in the detection of a novel pathogenic GNS gene mutation. The patient also exhibited intellectual disability since childhood, reduced vision due to pigmentary retinopathy, and behavioural abnormalities without other systemic features of MPS. Here, we report a patient of Indian origin with MPS IIID based on a novel pathogenic variant c.1078 G>T (p.G360C) in the GNS gene and the presence of MCBs in muscle biopsy, characterized by several novel findings including the occurrence of pigmentary retinopathy which extends the clinical spectrum of MPS IIID.

## **Clinical case**

A 23-year-old woman presented with insidious onset painless bilateral progressive visual impairment from 12 years of age. She was born to healthy consanguineous parents (second-degree) with no family history of reduced vision or neurological symptoms. She struggled academically due to intellectual disability, exhibited behavioural abnormalities including irritability with anger outbursts and preferred limited social interaction but ultimately achieved independence in self-care and was able to do domestic work. Her birth and developmental milestones were otherwise normal. Systemic examination was normal including no neurocutaneous markers. Initially, she had difficulty with night vision, followed by daylight vision. At age 23, bilateral visual acuity was 6/60. Fundus examination showed retinitis pigmentosa (RP). The rest of the neurological examination was unremarkable. Specifically, there was no weakness in the muscles of head/neck, trunk and limbs.

Visual evoked potential showed right poor waveform, prolonged P100 (167.7ms, N<108msec) and absent left P100 potential. Brainstem auditory and somatosensory evoked potentials were normal. Magnetic resonance imaging (MRI) showed mild cortical and cerebellar atrophy (Figure 1A). A mitochondrial disease was considered and therefore

quadriceps muscle was biopsied. Biopsied tissue was archived in Human skeletal muscle disease Biobank at our institution with prior consent and the same was retrieved for the study.

Hematoxylin and eosin (H&E) stained cryosections of the muscle biopsy showed a rare myofiber with cytoplasmic small irregular eosinophilic deposits, and clear vacuoles in the periphery (eFigure 1A). Oxidative enzymes stains for succinate dehydrogenase (SDH) and nicotinamide adenine dinucleotide-tetrazolium reductase (NADH-Tr) showed a mild increase in activity in the peripheral regions of a few fibers. 1% toluidine blue stained resin sections highlighted a couple of fibers with vacuoles and lipid droplets in the perinuclear and peripheral regions (Figure 1B; eFigure 1B). The corresponding areas on electron microscopy (EM) revealed several membrane-bound multi-layered concentric lamellar structures with granular core called membranous cytoplasmic bodies (MCBs) (Figure 1C; eFigure 1C), characteristic of certain forms of lysosomal storage disorders (LSD) particularly Mucopolysaccharidosis (MPS) and gangliosidosis. These have been described in other tissues including brain, liver, kidney and skin.<sup>1, 2</sup> To the best of our knowledge MCBs in skeletal muscle has not been reported. The possibility of MPS/GM1 gangliosidosis was considered based on the ultrastructural observations which instigated a genetic evaluation for LSD.

Clinical exome sequencing (MedGenome labs, Bangalore) showed a novel homozygous missense c.1078 G>T, p.G360C variation in N-acetyl glucosamine-6-sulphatase (*GNS*) (transcript ENST00000543646.5) in the proband (Figure 1D), further validated by Sanger sequencing (eFigure 1D). Both parents and her brother were heterozygous carriers (eFigure 1D). The brothers' heterozygous status provides evidence for the variant's pathogenicity since it segregates within the family according to mendelian expectations. This variation is conserved across species and predicted to be disease-causing by *in silico* analysis using Mutation taster and Rare Exome Variant Ensemble list (REVEL, score 0.972) and deleterious with Combined Annotation Dependent Depletion (CADD, score 31). This variant was not found in 1000 Genomes Project, Exome Aggregation Consortium (ExAC), Genome Aggregation Database (gnomAD) and Indian database, Indigenomes, and hence it is a novel variant. No variants were identified in Mitochondrial genome sequencing.

Biochemical investigations like serum/plasma lactate, plasma ammonia, mitochondrial respiratory enzyme assays and  $\beta$ -galactosidase enzyme level were normal. The leukocyte *GNS* enzyme activity was significantly low [0.1 nmol/24hr/mg; (reference range: mean $\pm$ SD – 4-16 (13 $\pm$ 1.4)]. Based on these features a diagnosis of MPS IIID was made.

## Discussion

Mucopolysaccharidoses are devastating autosomal recessive disorders caused by accumulation of glycosaminoglycans (GAG). The deficiency of the lysosomal enzyme that breaks down heparan sulphate (HS) results in MPS III disorders, with various subtypes including MPS IIIA (heparan N-sulfatase, SGSH), MPS IIIB (alpha-N-acetylglucosaminidase, NAGLU), MPS IIIC (heparan-alpha-glucosaminide N-acetyltransferase, HGSNAT) and MPS IIID (N-acetyl glucosamine-6-sulphatase, GNS).<sup>3</sup> Amongst the subtypes, MPS I is the most common overall<sup>4</sup>, while MPS IIIC and IIID (1 in 1,000,000 live births) are the rarest forms according to the National MPS Society.<sup>5</sup> However, region and ethnic background may affect the phenotype of MPS.<sup>7</sup> For example, of patients in Asia, mainly from China, Japan and South Korea, the majority reported were subtype MPS II. But in Europe, the incidence of MPS II was lower than that of MPS I and MPS III. In Germany, Netherlands and Estonia specifically, MPS III was the most common MPS subtype.<sup>6</sup> Here, we report an adult patient from India with intellectual disability since childhood, vision loss, RP, and MCBs on muscle biopsy. She was diagnosed with MPS IIID based on genetic analysis and low GNS enzyme activity. Notably, there are no prior reports of genetically confirmed MPS IIID from the Indian subcontinent, though Kresse et al. reported MPS IIID based on skin fibroblasts from a European patient of east Indian origin.<sup>7</sup>

Mucopolysaccharidoses is characterized by neurological symptoms, facial dysmorphism, cardiac diseases, skeletal abnormality, respiratory and ocular disorders (**Table 1**). The clinical manifestations overlap substantially across subtypes. Patients typically exhibit normal development for the first few years of life. Neurological symptoms, including developmental (primarily speech) delay, intellectual impairment, behavioural changes in the form of agitation, aggression and hyperactivity, sleep disturbances and seizures, generally start between 2-6 years. Disease progression is characterized by development of spasticity, recurrent falls leading to loss of independent ambulation, feeding difficulties ultimately requiring enteral feeding, speech loss, recurrent respiratory infections, and mortality in adolescence. Systemic manifestations include pigmentary retinopathy, optic atrophy, sensorineural hearing loss, coarse facial features (broad nose with flared nostrils, flat nasal bridge, prominent supraorbital ridges, large rounded cheeks, synophrys, hirsutism, thick lips, macroglossia, frontal bossing), abdominal and inguinal hernia, femoral head osteonecrosis, osteopenia and hepatosplenomegaly.<sup>8,9</sup> MPS IIIC and IIID have a slightly milder course with a longer survival compared to MPS IIIA/IIIB.<sup>8</sup> The clinical course in our patient was marked

by normal development through her first decade. However, she exhibited poor scholastics leading to a diagnosis of intellectual disability, and preferred limited social interaction. Starting at age 12 she developed significant ocular manifestations including vision loss and RP. Pigmentary retinopathy as seen in our patient is a novel clinical feature in MPS IIID. While pigmentary retinopathy was reported in patients with MPS IIIA and MPS IIIC, it was not seen in a cohort of 15 patients with MPS IIID by Valstar et al<sup>10</sup> or other published cases of MPS IIID.<sup>11</sup> The differential diagnoses for pigmentary retinopathy include other MPS, Niemann-pick disease, Gaucher's disease, multiple sulfatase deficiency, fucosidosis, mannosidosis and mitochondrial disorders.

The first screening test for MPS is a quantitative assay for urinary GAG. If elevated, individual GAG species can be identified by mass or electrophoretic spectroscopy. In MPS III, HS is elevated. To identify the subtypes, leucocyte or fibroblast enzyme activity assay is desirable. Molecular genetic analysis will identify the underlying gene defect.<sup>8</sup> In our patient, blood leukocyte GNS enzyme activity was done after genetic testing and was low.

HS is the most variable GAG and its functional role depends on its structural variability allowing it to form conjugates with various protein moieties including heparan sulphate proteoglycans (HSPGs). HSPGs are widely expressed on the basal lamina and surface of skeletal muscle cells. Inappropriate catabolism of HS destroys muscle development and physiological function causing weakness.<sup>12</sup> Improper HS breakdown leads to accrual within cell lysosomes which form the characteristic MCBs detected on EM. MCBs are a characteristic feature of MPS and GM1/GM2 gangliosidosis. The biopsied muscle from our patient highlighted MCBs which gave the preliminary clue to diagnosis of MPS although MCBs have not been previously reported in skeletal muscle fibers of MPS IIID patients. This case highlights the role of ultrastructural morpho-diagnosis in peripheral tissue biopsy.

Brain and spine imaging in MPS can show enlarged Virchow Robin spaces, focal or confluent T2/FLAIR white matter hyperintensities, communicating hydrocephalous, brain atrophy, cervical spinal canal stenosis with or without cord compression, and abnormalities of skull and vertebrae. Brain atrophy is most common in MPS II and III.<sup>13</sup> Likewise, mild cortical and cerebellar atrophy was noted in our patient with MPS IIID phenotype. Spine MRI was not done.

MPS IIID is caused by homozygous mutation in the GNS gene, located on chromosome 12 first described in 2002 by Mok et al.<sup>11</sup> Subsequent cases reported by various groups have

identified 23 different mutations overall including point mutations, deletions and large rearrangements with similar clinical presentation and age at onset in the first decade of life.<sup>10,</sup>

<sup>14</sup> Here, we describe a novel homozygous missense c.1078 G>T (p.G360C) variation in exon 9 of *GNS*. Sanger sequencing confirmed homozygosity in patient, while parents and younger brother were heterozygous carriers (Figure 1D). The biallelic loss-of-function was supported by almost complete loss of GNS enzyme activity.

Treatment for MPS III includes enzyme replacement therapy, substrate reduction therapy, gene therapy, hematopoietic stem cell therapy and enzyme enhancement therapy. In 2017, promising data from a mouse model for MPS IIID treated with adeno-associated virus 9 mediated gene therapy suggests gene therapy may be a future treatment option.<sup>15</sup> Identification of novel variants, functional validation and further studies on pathophysiology are required to pave the way for developing additional treatment strategies.

The novel findings of the present report are the occurrence of retinitis pigmentosa, lack of systemic features of MPS, presence of MCBs in muscle biopsy, and a novel *GNS* pathogenic mutation in a patient of MPS IIID. A high index of suspicion is desirable in patients with intellectual disability, behavioural changes, hyperactivity, retinitis pigmentosa even without coarse facial features, skeletal abnormalities or organomegaly. Awareness of pathological findings in peripheral tissue biopsies can guide targeted gene testing and diagnosis.

**Table 1:** Clinical features of Mucopolysaccharidosis (MPS) subtypes

MPS subtypes	Neurological features	Systemic features*
MPS I	Intellectual impairment, behavioural changes, cervical myelopathy	Skeletal deformations, coarse facial features, hepatosplenomegaly, cardiac diseases, respiratory diseases, ocular disorders
MPS II	Intellectual impairment, behavioural changes, seizures, cervical myelopathy	Skeletal deformations, coarse facial features, hepatosplenomegaly, cardiac diseases, respiratory diseases, ocular disorders- corneal clouding and retinopathy is rare
MPS III	Intellectual impairment, behavioural changes, seizures, sleep disturbance, cervical myelopathy	Hernia, sensorineural hearing loss, retinopathy and, dental caries. Corneal clouding is rare
MPS IV	Learning disability	Skeletal deformations, valvular heart diseases, dental caries, restrictive respiratory disease, corneal clouding
MPS VI and VII	Learning disability	Skeletal deformations, coarse facial features, corneal clouding, optic atrophy, short stature, cardiomyopathy, hernias

\* Skeletal deformation include dysostosis multiplex, thoracolumbar gibbus, odontoid hypoplasia, and spondylolisthesis

Cardiac diseases include cardiomyopathy, valvular heart disease, and ischemic heart disease

Ocular disorders include corneal clouding, open- and closed-angle glaucoma, optic atrophy, refractive errors, hypertelorism, and exophthalmos



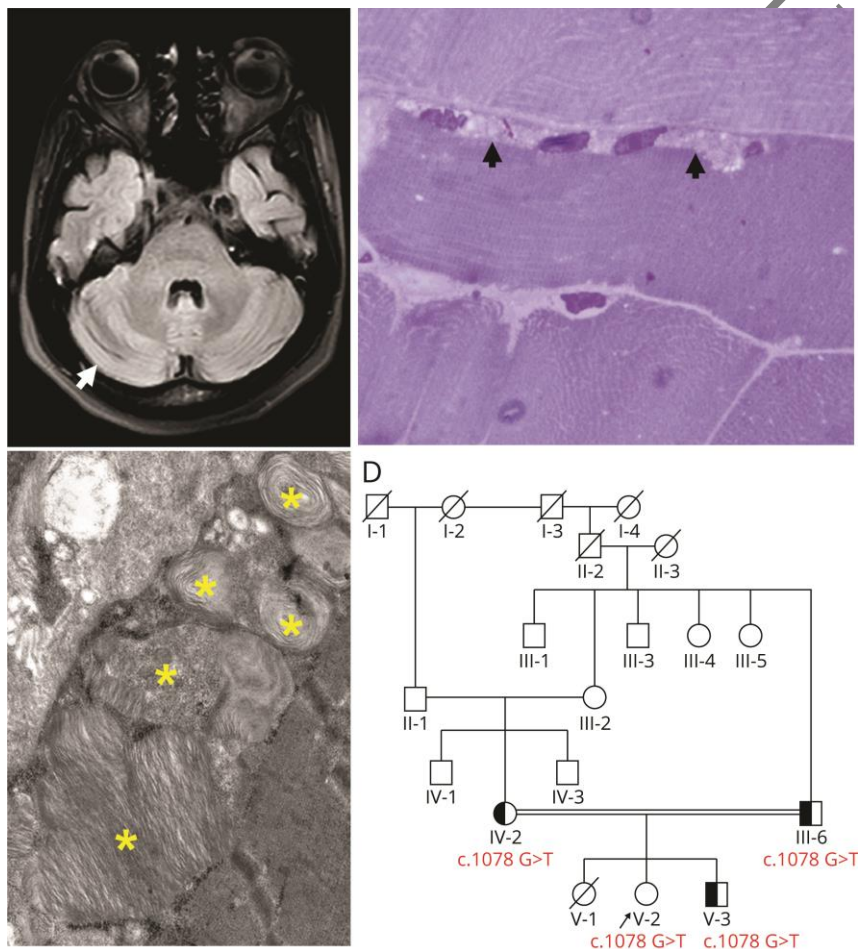
## References

1. Hadfield MG, Ghatak NR, Nakoneczna I, et al. Pathologic Findings in Mucopolysaccharidosis Type IIIB (Sanfilippo's Syndrome B). *Archives of Neurology* 1980;37:645-650.
2. Bioulac P, Mercier M, Beylot C, Fontan D. The diagnosis of mucopolysaccharidoses by electron microscopy of skin biopsies. *J Cutan Pathol* 1975;2:179-190.
3. Tomatsu S, Pitz S, Hampel U. Ophthalmological Findings in Mucopolysaccharidoses. *Journal of clinical medicine* 2019;8.
4. Sheth J, Mistri M, Sheth F, et al. Burden of lysosomal storage disorders in India: experience of 387 affected children from a single diagnostic facility. *JIMD Rep* 2014;12:51-63.
5. National MPS Society, [online]. Accessed September 4, 2022.
6. Zhou J, Lin J, Leung WT, Wang L. A basic understanding of mucopolysaccharidosis: Incidence, clinical features, diagnosis, and management. *Intractable & rare diseases research* 2020;9:1-9.
7. Kresse H, Paschke E, von Figura K, Gilberg W, Fuchs W. Sanfilippo disease type D: deficiency of N-acetylglucosamine-6-sulfate sulfatase required for heparan sulfate degradation. *Proc Natl Acad Sci U S A* 1980;77:6822-6826.
8. Seker Yilmaz B, Davison J, Jones SA, Baruteau J. Novel therapies for mucopolysaccharidosis type III. *Journal of inherited metabolic disease* 2021;44:129-147.
9. Galimberti C, Madeo A, Di Rocco M, Fiumara A. Mucopolysaccharidoses: early diagnostic signs in infants and children. *Italian journal of pediatrics* 2018;44:133.
10. Valstar MJ, Bertoli-Avella AM, Wessels MW, et al. Mucopolysaccharidosis type IIID: 12 new patients and 15 novel mutations. *Human Mutation* 2010;31:E1348-E1360.
11. Mok A, Cao H, Hegele R. Genomic basis of mucopolysaccharidosis type IIID (MIM 252940) revealed by sequencing of GNS encoding N-acetylglucosamine-6-sulfatase. *Genomics* 2003;81:1-5.
12. Jenniskens GJ, Veerkamp JH, van Kuppevelt TH. Heparan sulfates in skeletal muscle development and physiology. *Journal of cellular physiology* 2006;206:283-294.
13. Reichert R, Campos LG, Vairo F, et al. Neuroimaging Findings in Patients with Mucopolysaccharidosis: What You Really Need to Know. *RadioGraphics* 2016;36:1448-1462.
14. Celik B, Tomatsu SC, Tomatsu S, Khan SA. Epidemiology of Mucopolysaccharidoses Update. *Diagnostics* 2021;11:273.
15. Roca C, Motas S, Marcó S, et al. Disease correction by AAV-mediated gene therapy in a new mouse model of mucopolysaccharidosis type IIID. *Human Molecular Genetics* 2017;26:1535-1551.

**Legend:**

**Figure 1:** MRI, pathological findings and inheritance pattern in a patient with MPS IIID

(A) Axial FLAIR MRI brain image showing mild cerebellar atrophy (arrow). (B) Resin section from skeletal muscle stained with 1% toluidine blue showing lightly stained areas in the periphery of myofiber with numerous clear vacuoles [(arrow), Magnification = 100x; Scale bar = 10  $\mu$ m]. (C) Electron micrograph showing portion of myofiber with several single membrane-bound membranous cytoplasmic bodies (MCBs) with multi-layered concentric lamellae with granular core (asterisks) in the subsarcolemmal region of the myofibers (x5000), (D) Pedigree.



# Neurology<sup>®</sup>

## Child Neurology: Mucopolysaccharidosis IIID: Evidence From Ultrastructural and Genomic Study

Rashmi Santhoshkumar, Rohan R Mahale, Pakina Krishna Kishore, et al.

*Neurology* published online July 24, 2023

DOI 10.1212/WNL.0000000000207647

**This information is current as of July 24, 2023**

<b>Updated Information &amp; Services</b>	including high resolution figures, can be found at: <a href="http://n.neurology.org/content/early/2023/07/24/WNL.0000000000207647.full">http://n.neurology.org/content/early/2023/07/24/WNL.0000000000207647.full</a>
<b>Subspecialty Collections</b>	This article, along with others on similar topics, appears in the following collection(s): <b>Metabolic disease (inherited)</b> <a href="http://n.neurology.org/cgi/collection/metabolic_disease_inherited">http://n.neurology.org/cgi/collection/metabolic_disease_inherited</a> <b>Muscle disease</b> <a href="http://n.neurology.org/cgi/collection/muscle_disease">http://n.neurology.org/cgi/collection/muscle_disease</a> <b>Retina</b> <a href="http://n.neurology.org/cgi/collection/retina">http://n.neurology.org/cgi/collection/retina</a>
<b>Permissions &amp; Licensing</b>	Information about reproducing this article in parts (figures, tables) or in its entirety can be found online at: <a href="http://www.neurology.org/about/about_the_journal#permissions">http://www.neurology.org/about/about_the_journal#permissions</a>
<b>Reprints</b>	Information about ordering reprints can be found online: <a href="http://n.neurology.org/subscribers/advertise">http://n.neurology.org/subscribers/advertise</a>

*Neurology*® is the official journal of the American Academy of Neurology. Published continuously since 1951, it is now a weekly with 48 issues per year. Copyright © 2023 American Academy of Neurology. All rights reserved. Print ISSN: 0028-3878. Online ISSN: 1526-632X.

