

---

**Neurology Publish Ahead of Print**  
**DOI:10.1212/WNL.000000000207477**

Teaching Video NeuroImage: Pendular Vertical Oscillations in a Young Adult With a Pontine Hemorrhage

**Author(s):**

Jacky Ganguly, MD, DM, PDF<sup>1</sup>; Soumava Mukherjee, MD, DM<sup>1</sup>; Nilam Singh, MD, DM<sup>1</sup>; Hrishikesh Kumar, MD, DM, PDF<sup>1</sup>

**Corresponding Author:**

Hrishikesh Kumar, rishi\_medicine@yahoo.com

**Affiliation Information for All Authors:** 1. Institute of Neurosciences Kolkata. 185, Acharya Jagadish Chandra Bose Rd, Elgin, Kolkata, West Bengal, India 700017.

**Equal Author Contribution:**

**Contributions:**

Jacky Ganguly: Drafting/revision of the manuscript for content, including medical writing for content; Major role in the acquisition of data; Analysis or interpretation of data

Soumava Mukherjee: Major role in the acquisition of data

Nilam Singh: Major role in the acquisition of data

Hrishikesh Kumar: Study concept or design

**Figure Count:**

1

**Table Count:**

0

**Search Terms:**

[ 186 ] All Neuro-ophthalmology, Pendular vertical oscillations

**Acknowledgment:**

We acknowledge Dr. Mona Tiwari (Department of Radiology, I-NK, Kolkata) for providing MRI images and Dr. Divyani Garg (Department of Neurology, AIIMS, New Delhi) for the discussion.

**Study Funding:**

The authors report no targeted funding.

**Disclosure:**

The authors report no relevant disclosures.

**Preprint DOI:****Received Date:**

2023-01-22

**Accepted Date:**

2023-04-17

**Handling Editor Statement:**

Submitted and externally peer reviewed. The handling editor was Resident and Fellow Deputy Editor Ariel Lyons-Warren, MD, PhD.

A 23-year-old woman presented with constant pendular vertical oscillations in primary gaze along with bilateral horizontal gaze palsy [Video 1] within 3 days of acute pontine haemorrhage [Figure]. There was no palatal tremor. Gaze palsy was likely due to involvement of the paramedian pontine reticular formation. Pendular vertical oscillations (PVOs) after pontine stroke are a unique clinical finding initially described as ‘ocular myoclonus’. Pathophysiology of PVOs include: (1) synchronized neural oscillations from the inferior olive following disruption of the central tegmental tract, (2) unstable integration of vertical gaze in the interstitial nucleus of Cajal from damage to the pontine paramedian tract or (3) injury to omnipause neurons.<sup>1</sup> Differential diagnosis includes ocular bobbing and oculopalatal tremor, both more common after brainstem stroke. However, ocular bobbing consists of intermittent fast downward movement with slow return to midline. Oculopalatal tremor is a delayed manifestation of injury to the dentato-rubro-olivary pathway manifesting as pendular nystagmus with vertical and/or torsional component synchronous with palatal tremor.<sup>2</sup>

WNL-2023-000307\_slides --- <http://links.lww.com/WNL/C923>

WNL-2023-000307\_vid1 --- <http://links.lww.com/WNL/C924>

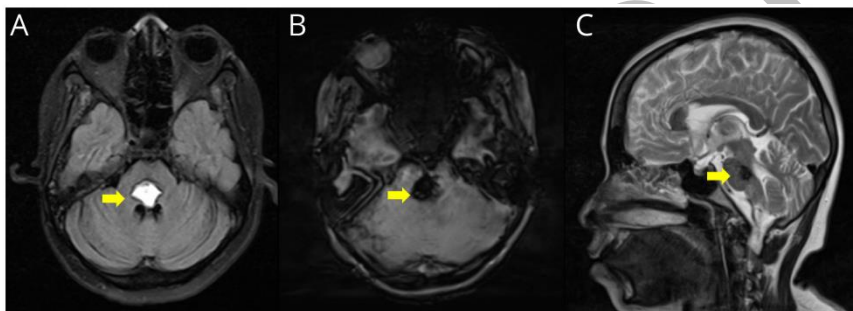
## References

1. Chang TP, Gold DR, Otero-Millan J, Huang BR, Zee DS. Pendular Oscillation and Ocular Bobbing After Pontine Hemorrhage. *The Cerebellum*. 2021;20(5):734-743. doi:10.1007/s12311-019-01086-6
2. Borruat FX. Oculopalatal tremor. *Curr Opin Neurol*. 2013;26(1):67-73. doi:10.1097/WCO.0b013e32835c60e6

## Legends:

**Video 1. Continuous pendular vertical oscillations in primary gaze along with bilateral horizontal gaze palsy**

**Figure. Axial T2FLAIR MRI (A) showing acute haemorrhage at dorsal pons with blooming in SWI (B) and follow-up sagittal T2 MRI (C) image showing haemorrhagic residue. Arrows indicate the site of haemorrhage.**



# Neurology<sup>®</sup>

## Teaching Video NeuroImage: Pendular Vertical Oscillations in a Young Adult With a Pontine Hemorrhage

Jacky Ganguly, Soumava Mukherjee, Nilam Singh, et al.  
*Neurology* published online June 23, 2023  
DOI 10.1212/WNL.0000000000207477

**This information is current as of June 23, 2023**

<b>Updated Information &amp; Services</b>	including high resolution figures, can be found at: <a href="http://n.neurology.org/content/early/2023/06/23/WNL.0000000000207477.citation.full">http://n.neurology.org/content/early/2023/06/23/WNL.0000000000207477.citation.full</a>
<b>Subspecialty Collections</b>	This article, along with others on similar topics, appears in the following collection(s): <b>All Neuro-ophthalmology</b> <a href="http://n.neurology.org/cgi/collection/all_neuroophthalmology">http://n.neurology.org/cgi/collection/all_neuroophthalmology</a>
<b>Permissions &amp; Licensing</b>	Information about reproducing this article in parts (figures, tables) or in its entirety can be found online at: <a href="http://www.neurology.org/about/about_the_journal#permissions">http://www.neurology.org/about/about_the_journal#permissions</a>
<b>Reprints</b>	Information about ordering reprints can be found online: <a href="http://n.neurology.org/subscribers/advertise">http://n.neurology.org/subscribers/advertise</a>

*Neurology*® is the official journal of the American Academy of Neurology. Published continuously since 1951, it is now a weekly with 48 issues per year. Copyright © 2023 American Academy of Neurology. All rights reserved. Print ISSN: 0028-3878. Online ISSN: 1526-632X.

