
Neurology Publish Ahead of Print
DOI: 10.1212/WNL.0000000000207394

Teaching NeuroImage: Radial Compression Neuropathy Secondary to Accessory Belly of the Triceps Muscle

Author(s):

Pablo Bastias, MD, Neurologist, Fellow Research^{1,2}; Romulo Melo, MD, Neurosurgeon^{3,4}; Jose Manuel Matamala, MD, PhD, Neurologist^{1,4,5,6}; Nicholas Earle, MD, Neurologist⁷; Ignacio Acosta, MD, Neurologist^{1,4,6,8}

Corresponding Author:

Ignacio Acosta, ignacioacosta@uchile.cl

Affiliation Information for All Authors: 1. Neurology and translational neurophysiology laboratory (NODO lab), University of Chile, Medicine Faculty. Santiago, Chile. 2. Hospital Clinico de la Fuerza Aerea de Chile (FACH), General Dr. Raúl Yazigi J., Santiago, Chile 3. Clinica Alemana de Santiago, Neurology and Psychiatry Department, Santiago, Chile. 4. Departamento de Ciencias Neurologicas Oriente, University of Chile, Medicine Faculty. Santiago, Chile. 5. Instituto Milenio de Neurociencia Biomedica (BNI), University of Chile, Medicine Faculty. Santiago, Chile. 6. Neurology and Psychiatry Department. University of Chile, Medicine Faculty. Santiago, Chile. 7. Clinica Davila, Neurology and Neurosurgery department, Santiago, Chile. 8. Hospital del Salvador, Neurology department, Santiago, Chile.

Equal Author Contribution:

Pablo Bastias and Ignacio Acosta contributed equally to this work.

Contributions:

Pablo Bastias: Drafting/revision of the manuscript for content, including medical writing for content; Major role in the acquisition of data; Study concept or design; Analysis or interpretation of data
Romulo Melo: Drafting/revision of the manuscript for content, including medical writing for content; Analysis or interpretation of data

Jose Manuel Matamala: Drafting/revision of the manuscript for content, including medical writing for content; Analysis or interpretation of data

Nicholas Earle: Drafting/revision of the manuscript for content, including medical writing for content;

Analysis or interpretation of data

Ignacio Acosta: Drafting/revision of the manuscript for content, including medical writing for content; Major role in the acquisition of data; Study concept or design; Analysis or interpretation of data

Figure Count:2

Table Count:0

Search Terms:

[285] EMG, [124] Ultrasound, [181] Peripheral neuropathy, Neuromuscular ultrasound, Radial neuropathy

Acknowledgment:

Study Funding:

The authors report no targeted funding

Disclosures:

The authors report no relevant disclosures.

Preprint DOI:

Received Date:

2022-10-04

Accepted Date:

2023-03-23

Handling Editor Statement:

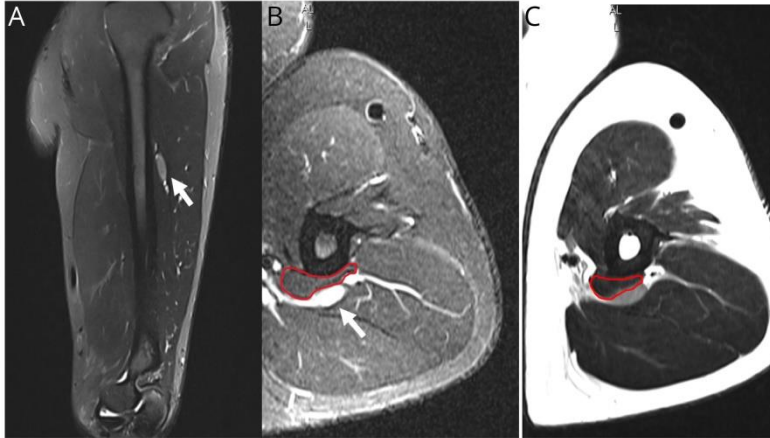
Submitted and externally peer reviewed. The handling editor was Resident and Fellow Section Editor Whitley Aamodt, MD, MPH.

A 43-year-old male presented with five months of left-hand pain, extensor weakness, and dorsal sensory loss. There was no history of trauma, infection, or exercise-related symptoms. Neurological examination showed atrophy and weakness (4/5 on the MCR scale) of the left brachioradialis, wrist, and finger extensor muscles. Sensation to pinprick and touch were reduced over the dorsum of the left hand. NCV showed a reduction in CMAP (1.0mV) and SNAP (14uV) amplitudes in the left radial nerve. No conduction blocks or focal slowing were recorded. EMG also showed active denervation of the brachioradialis and forearm extensor muscles, sparing the triceps. An axonal radial sensorimotor neuropathy proximal to the brachioradialis muscle was diagnosed. Left arm MRI, ultrasound, and surgical exploration showed an entrapment of the radial nerve in the upper arm due to a triceps accessory muscle belly (Figures 1 and 2). Muscle anatomical variants are an infrequent cause of radial nerve entrapment, and images are crucial to identify this etiology^{1,2}

Figure legends

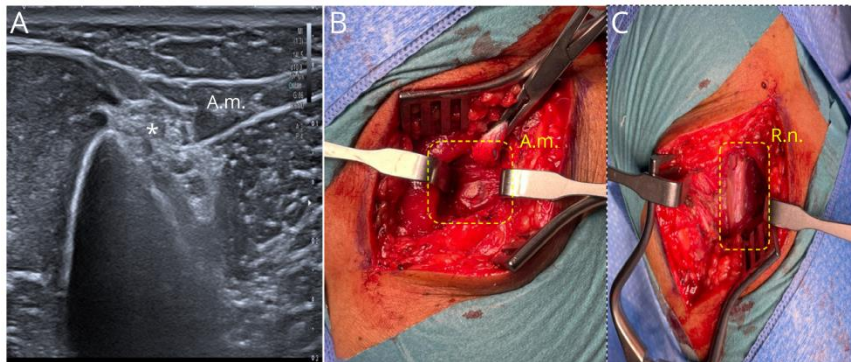
- **Figure 1:**

Left arm MRI without contrast: sagittal STIR (**a**), axial STIR (**b**), and axial T2 (**c**) images. The radial nerve (white arrows) has focal thickening and increased signal at the level of the middle third of the humerus. An accessory muscle belly of the triceps (red lines; **b,c**) is visualized compressing the radial nerve.



- **Figure 2:**

Left radial nerve ultrasound (**a**). The radial nerve (asterisk) has increased echogenicity and cross-sectional area (CSA) at the middle third of the humerus; the accessory belly of the triceps muscle (A.m.) is shown. Surgical decompression pre-radial nerve release (**b**) and post-radial nerve release (**c**) confirmed this entrapment etiology. R.n: Radial nerve.



<http://links.lww.com/WNL/C800>

References

1.- Agarwal A, Chandra A, Jaipal U, Saini N. A panorama of radial nerve pathologies- an imaging diagnosis: a step ahead. *Insights into Imaging*, 2018;9:1021–1034.

<https://doi.org/10.1007/s13244-018-0662-x>

2.- Shane Tubbs R, George Salter E, Jerry Oakes W. Triceps brachii muscle demonstrating of fourth head. *Clinical Anatomy*: 2006; 19: 657 – 666. <https://doi.org/10.1002/ca.20326>.

ACCEPTED

Neurology®

Teaching NeuroImage: Radial Compression Neuropathy Secondary to Accessory Belly of the Triceps Muscle

Pablo Bastias, Romulo Melo, Jose Manuel Matamala, et al.

Neurology published online May 8, 2023

DOI 10.1212/WNL.0000000000207394

This information is current as of May 8, 2023

| | |
|---|--|
| Updated Information & Services | including high resolution figures, can be found at: http://n.neurology.org/content/early/2023/05/08/WNL.0000000000207394.citation.full |
| Subspecialty Collections | This article, along with others on similar topics, appears in the following collection(s): EMG http://n.neurology.org/cgi/collection/emg Peripheral neuropathy http://n.neurology.org/cgi/collection/peripheral_neuropathy Ultrasound http://n.neurology.org/cgi/collection/ultrasound |
| Permissions & Licensing | Information about reproducing this article in parts (figures, tables) or in its entirety can be found online at: http://www.neurology.org/about/about_the_journal#permissions |
| Reprints | Information about ordering reprints can be found online: http://n.neurology.org/subscribers/advertise |

Neurology® is the official journal of the American Academy of Neurology. Published continuously since 1951, it is now a weekly with 48 issues per year. Copyright © 2023 American Academy of Neurology. All rights reserved. Print ISSN: 0028-3878. Online ISSN: 1526-632X.

