

# Teaching Video NeuroImage: Facial-Faucial-Finger Myoclonus in Kufor-Rakeb Syndrome

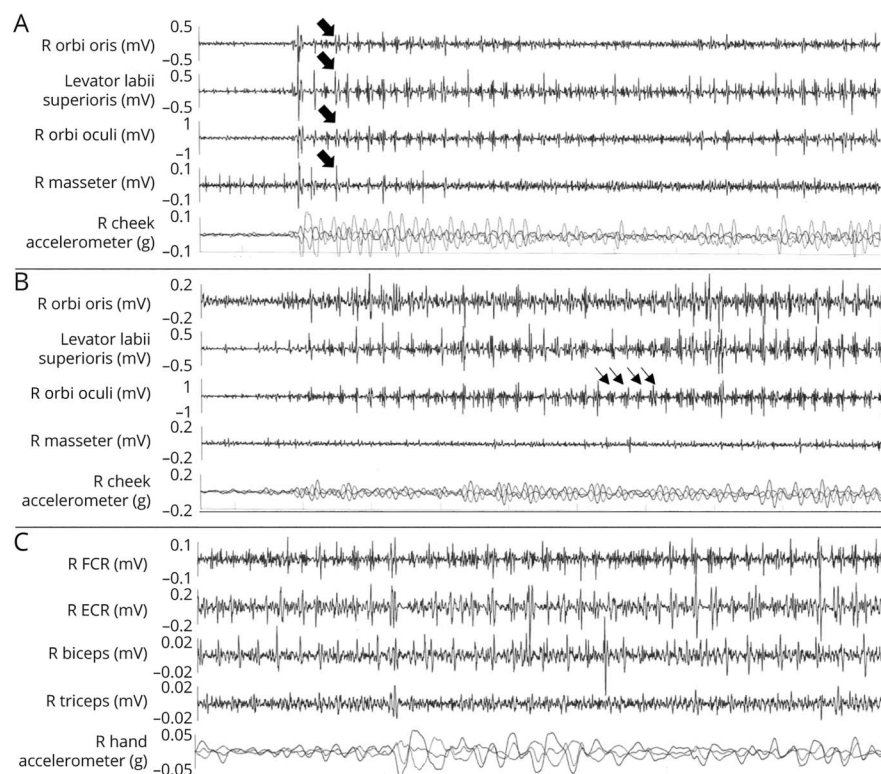
Sophie E. Waller, BMed(Hons), Laura Williams, MB BCh BAO, MD, Hugo Morales-Briceño, MD, and Victor S.C. Fung, PhD

*Neurology*® 2022;99:172-173. doi:10.1212/WNL.0000000000200751

## Correspondence

Dr. Waller  
sophie.waller@  
health.nsw.gov.au

**Figure 1** Surface EMG



Surface EMG showed both brief, synchronous <50 ms EMG bursting across facial muscles consistent with myoclonus (Panel A, wide arrows) and more sustained bursting typical of tremulous activity (Panel B, thin arrows). Upper limb surface EMG showed findings more consistent with a dystonic tremor, with continuous muscle activity present between discrete, tremulous EMG bursting (Panel C, arms extended). These neurophysiologic characteristics, to our knowledge not previously reported, demonstrate that what has been described phenomenologically as facial-faucial-finger myoclonus may have both myoclonic and tremulous features. ECR = extensor carpi radialis; FCR = flexor carpi radialis; orbi = orbicularis; R = right.

Two Chinese Australian siblings from nonconsanguineous parents presented with adolescent-onset dystonia-parkinsonism with prominent anxiety. Examination revealed eyelid, lower facial, and distal upper extremity myoclonus (Video 1), which was recorded using surface EMG (Figure 1). Compound heterozygous pathogenic variants in *ATP13A2* were identified, c.3176T>G (p.L1059R) and c.3253delC (p.L1088WfsX4), confirming the diagnosis of Kufor-Rakeb syndrome (KRS).<sup>1</sup> KRS classically presents as juvenile-onset, levodopa-responsive parkinsonism combined with pyramidal signs, upgaze palsy, cognitive decline, and, uniquely, facial-faucial-finger minimyoclonus.<sup>2</sup> This distinctive pattern of myoclonus is a useful clue to the diagnosis in affected individuals and distinguishes it from other forms of juvenile-onset parkinsonism.

## MORE ONLINE

▶ Video

## Teaching slides

[links.lww.com/WNL/C59](https://links.lww.com/WNL/C59)

From the Movement Disorders Unit, Neurology Department, Westmead Hospital, Westmead, Australia.

Go to [Neurology.org/N](https://Neurology.org/N) for full disclosures. Funding information and disclosures deemed relevant by the authors, if any, are provided at the end of the article.

## Acknowledgment

The authors thank Professor John Morris for his assistance in videotaping.

## Study Funding

The authors report no targeted funding.

## Disclosure

The authors report no disclosures relevant to the manuscript. Go to [Neurology.org/N](http://Neurology.org/N) for full disclosures.

## Publication History

Received by *Neurology* October 24, 2021. Accepted in final form April 4, 2022. Submitted and externally peer reviewed. The handling editor was Whitley Aamodt, MD, MPH.

## Appendix Authors

Name	Location	Contribution
<b>Sophie E. Waller, BMed(Hons)</b>	Movement Disorders Unit, Neurology Department, Westmead Hospital, Westmead, Australia	Drafting/revision of the manuscript for content, including medical writing for content, and study concept or design

## Appendix (continued)

Name	Location	Contribution
<b>Laura Williams, MB BCh BAO, MD</b>	Movement Disorders Unit, Neurology Department, Westmead Hospital, Westmead, Australia	Drafting/revision of the manuscript for content, including medical writing for content, and study concept or design
<b>Hugo Morales-Briceño, MD</b>	Movement Disorders Unit, Neurology Department, Westmead Hospital, Westmead, Australia	Drafting/revision of the manuscript for content, including medical writing for content, and study concept or design
<b>Victor S.C. Fung, PhD</b>	Movement Disorders Unit, Neurology Department, Westmead Hospital, Westmead, Australia	Drafting/revision of the manuscript for content, including medical writing for content; major role in the acquisition of data; and study concept or design

## References

1. Park JS, Mehta P, Cooper AA, et al. Pathogenic effects of novel mutations in the P-type ATPase ATP13A2 (PARK9) causing Kufor-Rakeb syndrome, a form of early-onset parkinsonism. *Hum Mutat.* 2011;32(8):956-964.
2. Behrens MI, Brüggemann N, Chana P, et al. Clinical spectrum of Kufor-Rakeb Syndrome in the Chilean kindred with ATP13A2 mutations. *Mov Disord.* 2010; 25(12):1929-1937.

## Neurology Question of the Day App

Challenge yourself to answer a neurology question each day. Staying up to date and earning CME has never been easier. This app serves up one new multiple-choice question each day on various topics in neurology and provides suggested resources for further study.

Get started today at [AAN.com/QODapp](http://AAN.com/QODapp).

## Announcing...

### Child Neurology: A Case-Based Approach Cases From the Neurology® Resident & Fellow Section

This collaboration between the American Academy of Neurology (AAN) and the Child Neurology Society (CNS) represents a collection of reprinted cases from the past 15 years from the Neurology Resident & Fellow Section.

An invaluable resource for both adult and pediatric neurologists and trainees! FREE download: [Npub.org/cnbook](http://Npub.org/cnbook)

# Neurology®

## Teaching Video NeuroImage: Facial-Facial-Finger Myoclonus in Kufor-Rakeb Syndrome

Sophie E. Waller, Laura Williams, Hugo Morales-Briceño, et al.  
*Neurology* 2022;99;172-173 Published Online before print May 24, 2022  
DOI 10.1212/WNL.0000000000200751

**This information is current as of May 24, 2022**

<b>Updated Information &amp; Services</b>	including high resolution figures, can be found at: <a href="http://n.neurology.org/content/99/4/172.full">http://n.neurology.org/content/99/4/172.full</a>
<b>References</b>	This article cites 2 articles, 0 of which you can access for free at: <a href="http://n.neurology.org/content/99/4/172.full#ref-list-1">http://n.neurology.org/content/99/4/172.full#ref-list-1</a>
<b>Subspecialty Collections</b>	This article, along with others on similar topics, appears in the following collection(s): <b>All Genetics</b> <a href="http://n.neurology.org/cgi/collection/all_genetics">http://n.neurology.org/cgi/collection/all_genetics</a> <b>Clinical neurology examination</b> <a href="http://n.neurology.org/cgi/collection/clinical_neurology_examination">http://n.neurology.org/cgi/collection/clinical_neurology_examination</a> <b>Myoclonus</b> <a href="http://n.neurology.org/cgi/collection/myoclonus">http://n.neurology.org/cgi/collection/myoclonus</a>
<b>Permissions &amp; Licensing</b>	Information about reproducing this article in parts (figures, tables) or in its entirety can be found online at: <a href="http://www.neurology.org/about/about_the_journal#permissions">http://www.neurology.org/about/about_the_journal#permissions</a>
<b>Reprints</b>	Information about ordering reprints can be found online: <a href="http://n.neurology.org/subscribers/advertise">http://n.neurology.org/subscribers/advertise</a>

*Neurology*® is the official journal of the American Academy of Neurology. Published continuously since 1951, it is now a weekly with 48 issues per year. Copyright © 2022 American Academy of Neurology. All rights reserved. Print ISSN: 0028-3878. Online ISSN: 1526-632X.

