

Clinical Reasoning: An 80-Year-Old Woman With a Homonymous Hemianopsia

Deena Tajfirouz, MD, John J. Chen, MD, PhD, and M. Tariq Bhatti, MD

Neurology® 2022;99:713-717. doi:10.1212/WNL.0000000000201175

Correspondence

Dr. Bhatti
muhammad.t.bhatti@kp.org

Abstract

An 80-year-old woman who was experiencing visual symptoms for 2 years was found to have a left homonymous hemianopsia (HH). On further evaluation the following month, she was noted to have simultanagnosia and alexia. MRI of the brain did not reveal a structural etiology for the symptoms. [¹⁸F]-fluorodeoxyglucose (FDG) PET-CT was performed to aid in the diagnostic investigation. This case of posterior cortical atrophy highlights the differential diagnosis of a HH in the absence of a structural lesion on MRI and the role of FDG PET-CT imaging in such patients.

Section 1

An 80-year-old woman with hypertension, hyperlipidemia, and type 2 diabetes mellitus reported 2 years of progressive difficulty reading and loss of depth perception. More recently, she stopped driving and was running into objects while walking. Initial evaluation by a local ophthalmologist identified bilateral cataracts resulting in surgical extraction, which did not improve the visual symptoms. Automated visual field (AVF) testing demonstrated a left homonymous hemianopsia (HH). Routine laboratory evaluation showed normal blood counts and chemistries. The patient was referred to a neurologist, and a normal neurologic examination was noted. A brain MRI with contrast showed normal age-related changes, but specifically, there was no evidence of a prior stroke, restricted diffusion on the diffusion-weighted images, tumor, abnormal posterior cortical asymmetry, or enhancement. The patient was referred to neuro-ophthalmology for further evaluation.

On our evaluation, visual acuity was 20/30 in each eye. She identified only 1 of 13 plates in each eye from the Ishihara pseudochromatic book. Confrontation testing was inconsistent to finger counting, but there was a nasal defect in the right eye and a temporal defect in the left eye. Pupils were equal with normal light reflexes and no relative afferent pupillary defect. Slitlamp examination showed centered posterior chamber intraocular lenses with normal intraocular pressure. The optic disc, macula, and retina appeared normal in each eye. Repeat AVF testing confirmed the left HH (Figure 1A).

Questions for Consideration:

1. Where is the lesion responsible for the visual field defect?
2. What is the cause of the decreased color vision?
3. What is the differential diagnosis for a HH with a negative MRI?

GO TO SECTION 2

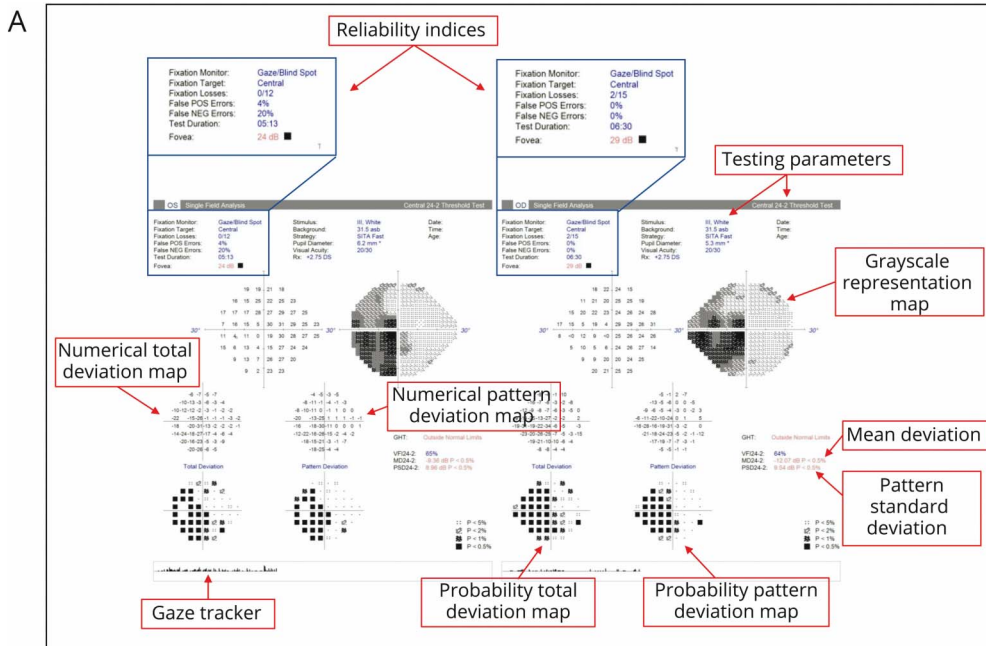
From the Department of Ophthalmology (D.T., J.J.C., M.T.B.), Mayo Clinic College of Medicine; and Department of Neurology (J.J.C., M.T.B.), Mayo Clinic College of Medicine. Dr. Bhatti is currently affiliated with The Permanente Medical Group, Northern California.

Go to [Neurology.org/N](https://www.neurology.org/N) for full disclosures. Funding information and disclosures deemed relevant by the authors, if any, are provided at the end of the article.

Glossary

AVF = Automated visual field; CJD = Creutzfeldt-Jacob disease; FDG = fluorodeoxyglucose; HH = homonymous hemianopsia; PCA = posterior cortical atrophy.

Figure 1 Interpretation of Humphrey Visual Field Test Printout



B Identify patient

- Patient name
- Birthdate (incorrect entry results in comparison with the wrong age group)
- Visual acuity
- Pupil size (pupil smaller than 2 mm or larger than 6 mm may affect results)

Identify testing parameters

- Stimulus size (size III stimulus [4 mm²] used in patients with visual acuity of 20/200 or better)
- Testing algorithm (10-2, 24-2, etc.) (i.e., central 24-2 indicates the central 24 degrees of visual field were tested and "2" indicates that the recorded values straddle the vertical and horizontal meridians)

Assess reliability indices

- Fixation losses: Patient reports seeing a stimulus in the expected central fixation zone (>20% could result in unreliable test)
- False positive errors: Patient presses button when no stimulus was present "trigger happy" (>20-30% could result in unreliable test)
- False negative errors: Patient fails to see a brighter stimulus at a previously seen location (>20-30% could result in unreliable test)

Interpret results

- Numerical total deviation map compares patient's visual sensitivity to age-matched controls (positive values represent increased sensitivity than normal, and negative values represent decreased sensitivity than normal)
- Numerical pattern deviation map extrapolates localized areas of sensitivity loss from a field that is diffusely depressed (i.e., depicts focal field depression in a patient with decreased threshold across the entire field due to factors such as dense cataracts)
- Grayscale probability plots of total deviation and pattern deviation maps are useful visual representation of the statistical significance of field defects (should be interpreted in conjunction with the numerical maps)
- Mean deviation (MD) represents the average difference from the expected age-matched normative database
- Pattern standard deviation (PSD) provides information about focal defects (higher values represent more focal losses, and lower values represent either no loss or diffuse loss)
- Gaze tracker monitors patient's eye movements during testing: upward bar indicates fixation disparity, and downward bar represents tracking failure. The length of the upward bar indicates the magnitude of the disparity, while a long downward bar represent eyelid closure.

(A) 24-2 Humphrey analyzer (Carl Zeiss Meditec AG, Dublin, CA). There is a left homonymous hemianopsia. Annotations highlight the various metrics needed to interpret the results. (B) Approach to automated perimetry interpretation.

Section 2

The pattern of a visual field defect can often determine the anatomic location of the lesion (Figure 2). In general, the following characteristics of a visual field defect should be noted: monocular or binocular, homonymous or heteronymous, complete or incomplete, and incongruous or congruous. Historically, a congruent HH was considered to originate from a lesion involving the occipital lobe, but this paradigm has been shown not to be a reliable localizing sign.¹ Therefore, in our patient, the presence of a left HH localizes the site of the lesion to anywhere along the right retrochiasmal visual pathway (i.e., right optic tract, optic radiations, or occipital lobe).

AVF is designed to detect visual field defects by projecting lights of different brightness, size, and location while the patient fixates at the center of a hemispherical bowl. Typically, the central 24–30° of vision is tested with a target size of III (4 mm²) stimulus. These stimuli are algorithmically planned to decrease patient anticipation and increase reliability. For the test to be valid, the patient must be able to reliably participate and complete the test. Patient factors such as familiarity with the test (i.e., learning curve), age, cognition, and physical abilities affect reliability.^{2,3} Fixation losses, false-positive responses (a positive response but there is no target displayed), and false-negative responses (failure to signal at a target that was previously seen in the same location) are metrics measured and displayed on the printout that determine the reliability of the test. Fixation losses should be less than 20% and false-negative errors and false-positive errors less than 20%–30% for the test to be reliable (Figure 1B).

Any visual field defect should be interpreted within the context of other clinical signs and symptoms. The Ishihara

pseudochromatic color plates are often used clinically to screen for dyschromatopsia by displaying a symbol (number or geometric figure) composed of colored dots against a background of differently colored dots; however, they can also be used as a screening tool for simultanagnosia. Patients with simultanagnosia are unable to perceive more than a single image at a time and often have trouble depicting the numbers from the background without actual impairment in color vision because of the inherent nature of the test.⁴ Further testing was notable for alexia and inability to name single objects in overlapping figures. Our patient's difficulty with the Ishihara color plates was likely because of simultanagnosia because she did not have a history of congenital color blindness and there was no evidence of optic neuropathy or retinopathy on examination. She scored 27 of 38 on the Kokmen Short Test of Mental Status, by obtaining 8 of 8 points in Orientation, 6 of 7 in Attention, 4 of 4 in Registration, 0 of 4 in Calculation, 2 of 3 in Similarities, 1 of 4 in Construction, 4 of 4 in Knowledge, and 2 of 4 in Recall.

An HH without a structural lesion on brain MRI has a short but important differential diagnosis that includes the Heidenhain variant of Creutzfeldt-Jacob disease (CJD), posterior cortical atrophy (PCA) syndrome, nonketotic hyperglycemia, seizures, subtle occipital ischemia, or a functional visual disorder.^{5,6} In our patient, the duration of symptoms and lack of diffusion restriction on the brain MRI made CJD unlikely. Normal laboratory evaluation and the progressive nature of the symptoms made hyperglycemia or a vascular etiology unlikely. The history and examination findings were not consistent with seizures or a functional visual disorder.

Question for Consideration:

1. What further testing would you perform?

GO TO SECTION 3

Figure 2 Visual Pathway Anatomy With Localization of Visual Field Defects

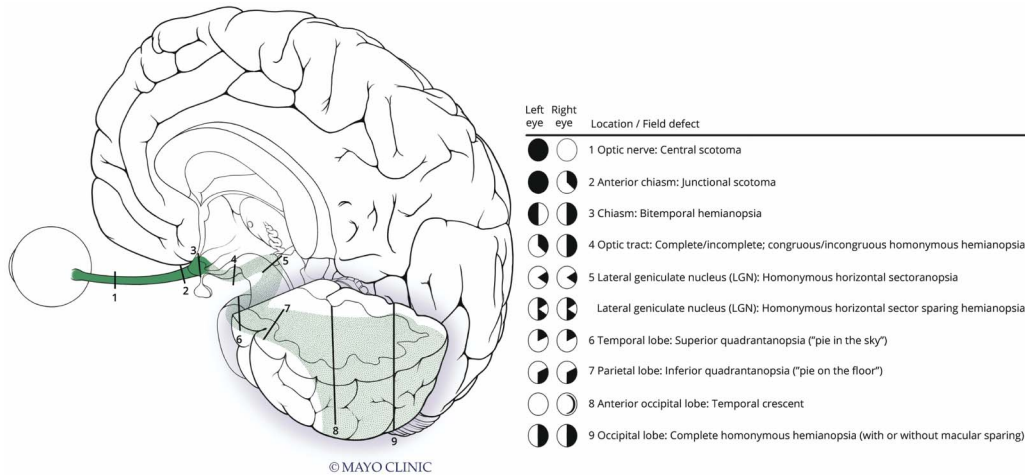


Illustration of the anterior and posterior visual pathway with various locations of a left-sided lesion resulting in corresponding visual field defects. With permission from the Mayo Foundation for Medical Education and Research.

Section 3

[¹⁸F]-fluorodeoxyglucose (FDG) PET-CT showed asymmetric moderate hypometabolism involving the right posterior cerebral hemisphere in a pattern consistent with PCA (eFigure 1, links.lww.com/WNL/C290). Studies have shown that FDG PET-CT, which measures functionality, is more sensitive and specific when evaluating patients with mild cognitive impairment compared with MRI, which is a structural measurement.^{7,8} She was referred to neurology for management but declined further neuropsychiatric testing or initiation of treatment.

Discussion

PCA is a rare, progressive, neurodegenerative syndrome that affects the posterior cortices resulting in visual dysfunction early in the disease.⁹ The disease process may initially affect parietal, occipital, or occipitotemporal regions; therefore, patients can present with a wide range of visual symptoms affecting higher order visual function while sparing anterograde memory, language, executive functions, and personality.^{10,11} PCA typically presents in the fifth and sixth decades of life, and as the disease progresses, patients develop dysfunction of other cognitive domains. The most common etiology of PCA syndrome is Alzheimer disease pathology; however, it can also be seen with other underlying pathologies such as dementia with Lewy body, corticobasal degeneration, prion disease, and subcortical gliosis.^{9,12-14}

The initial symptoms of PCA can be visuospatial-visuoperceptual impairments such as alexia, homonymous visual field deficits, features of Balint syndrome (simultanagnosia, oculomotor apraxia, optic ataxia, environmental agnosia) or Gerstmann

syndrome (acalculia, agraphia, finger agnosia, left/right disorientation).¹⁵ Patients with PCA syndrome commonly present with reading difficulties while simultanagnosia and homonymous visual field defects are also common findings in the initial evaluation. Homonymous visual field defects have been reported to be present in up to 60% of patients, highlighting the importance of AVF testing and cognitive assessment in suspected cases.¹³

Our patient with HH, alexia, and simultanagnosia met diagnostic criteria for PCA syndrome.¹² This case highlights the importance of considering neurodegenerative disease when a patient older than 45 years presents with a reproducible HH and negative findings on MRI.

Study Funding

No targeted funding reported.

Disclosure

The authors reported no relevant disclosures. Go to Neurology.org/N for full disclosures.

Publication History

Received by *Neurology* March 15, 2022. Accepted in final form July 14, 2022. Submitted and externally peer-reviewed. The handling editor was Roy Strowd III, MD, Med, MS.

Appendix Authors

Name	Location	Contribution
Deena Tajfirouza, MD	Department of Ophthalmology, Mayo Clinic College of Medicine	Drafting/revision of the manuscript for content, including medical writing for content; major role in the acquisition of data; analysis or interpretation of data

Appendix (continued)

Name	Location	Contribution
John J. Chen, MD, PhD	Department of Ophthalmology, Mayo Clinic College of Medicine; Department of Neurology, Mayo Clinic College of Medicine	Drafting/revision of the manuscript for content, including medical writing for content
M. Tariq Bhatti, MD	Department of Ophthalmology, Mayo Clinic College of Medicine; Department of Neurology, Mayo Clinic College of Medicine	Drafting/revision of the manuscript for content, including medical writing for content; major role in the acquisition of data; study concept or design; analysis or interpretation of data

References

1. Kedar S, Zhang X, Lynn MJ, Newman NJ, Biousse V. Congruency in homonymous hemianopia. *Am J Ophthalmol.* 2007;143(5):772-780.
2. Nazia Farah SDM. Influence of age on the visual fields of normal subjects: a clinical Study. *Int J Scientific Study.* 2015;2(10):41-46.
3. Sherafat H, Spry PGD, Waldock A, Sparrow JM, Diamond JP. Effect of a patient training video on visual field test reliability. *Br J Ophthalmol.* 2003;87(2):153-156.
4. Brazis PW, Graff-Radford NR, Newman NJ, Lee AG. Ishihara color plates as a test for simultanagnosia. *Am J Ophthalmol.* 1998;126(6):850-851.
5. Ma J, Micieli A, Micieli JA. Homonymous hemianopia with normal neuroimaging. *JAMA Ophthalmol.* 2022;140(1):92-93.
6. Brazis PW, Lee AG, Graff-Radford N, Desai NP, Eggenberger ER. Homonymous visual field defects in patients without corresponding structural lesions on neuroimaging. *J Neuroophthalmol.* 2000;20(2):92-96.
7. Chen JJ, Flanagan EP, Jitrapaikulsan J, et al. Myelin oligodendrocyte glycoprotein antibody-positive optic neuritis: clinical characteristics, radiologic clues, and outcome. *Am J Ophthalmol.* 2018;195:8-15.
8. Rice L, Bisdas S. The diagnostic value of FDG and amyloid PET in Alzheimer's disease—a systematic review. *Eur J Radiol.* 2017;94:16-24.
9. Crutch SJ, Lehmann M, Schott JM, Rabinovici GD, Rossor MN, Fox NC. Posterior cortical atrophy. *Lancet Neurol.* 2012;11(2):170-178.
10. Holden SK, Bettcher BM, Pelak VS. Update on posterior cortical atrophy. *Curr Opin Neurol.* 2020;33(1):68-73.
11. Pelak VS. The clinical approach to the identification of higher-order visual dysfunction in neurodegenerative disease. *Curr Neurol Neurosci Rep.* 2022;22(4):229-242.
12. Crutch SJ, Schott JM, Rabinovici GD, et al. Consensus classification of posterior cortical atrophy. *Alzheimers Dement.* 2017;13(8):870-884.
13. Olds JJ, Hills WL, Warner J, et al. Posterior cortical atrophy: characteristics from a clinical data registry. *Front Neurol.* 2020;11:358.
14. Renner JA, Burns JM, Hou CE, McKeel DW Jr, Storandt M, Morris JC. Progressive posterior cortical dysfunction: a clinicopathologic series. *Neurology.* 2004;63(7):1175-1180.
15. Kaeser PF, Ghika J, Borruat FX. Visual signs and symptoms in patients with the visual variant of Alzheimer disease. *BMC Ophthalmol.* 2015;15:65.

Neurology® Genetics

Neurology® Genetics is an online-only, open-access journal publishing peer-reviewed reports in the area of neurogenetics that elucidate the role of genetic and epigenetic variations in diseases and biological traits of the central and peripheral nervous systems. The journal's Impact Factor is 3.485. Access *Neurology: Genetics* at NG.Neurology.org.

Neurology® Neuroimmunology & Neuroinflammation

Neurology® Neuroimmunology & Neuroinflammation is an online-only, open-access journal with rigorously peer-reviewed reports of research in this area affecting the full range of neurologic diseases. Articles, editorials, and reviews aim to facilitate basic and translational research, along with enhancing patient care. The journal's Impact Factor is 8.485. Access *Neurology: Neuroimmunology & Neuroinflammation* at NN.Neurology.org.

Subspecialty Alerts by E-mail!

Customize your online journal experience by signing up for e-mail alerts related to your subspecialty or area of interest. Access this free service by clicking on the “My Alerts” link on the home page. An extensive list of subspecialties, methods, and study design choices will be available for you to choose from—allowing you priority alerts to cutting-edge research in your field!

Neurology[®]

Clinical Reasoning: An 80-Year-Old Woman With a Homonymous Hemianopsia

Deena Tajfirouz, John J. Chen and M. Tariq Bhatti

Neurology 2022;99;713-717 Published Online before print August 29, 2022

DOI 10.1212/WNL.0000000000201175

This information is current as of August 29, 2022

Neurology® is the official journal of the American Academy of Neurology. Published continuously since 1951, it is now a weekly with 48 issues per year. Copyright © 2022 American Academy of Neurology. All rights reserved. Print ISSN: 0028-3878. Online ISSN: 1526-632X.



Updated Information & Services	including high resolution figures, can be found at: http://n.neurology.org/content/99/16/713.full
References	This article cites 15 articles, 2 of which you can access for free at: http://n.neurology.org/content/99/16/713.full#ref-list-1
Subspecialty Collections	This article, along with others on similar topics, appears in the following collection(s): All Cognitive Disorders/Dementia http://n.neurology.org/cgi/collection/all_cognitive_disorders_dementia All Neuro-ophthalmology http://n.neurology.org/cgi/collection/all_neuroophthalmology Alzheimer's disease http://n.neurology.org/cgi/collection/alzheimers_disease Assessment of cognitive disorders/dementia http://n.neurology.org/cgi/collection/assessment_of_cognitive_disorders_dementia Cognitive neuropsychology in dementia http://n.neurology.org/cgi/collection/cognitive_neuropsychology_in_dementia Dementia with Lewy bodies http://n.neurology.org/cgi/collection/dementia_with_lewy_bodies Neuropsychological assessment http://n.neurology.org/cgi/collection/neuropsychological_assessment Visual fields http://n.neurology.org/cgi/collection/visual_fields Visual processing http://n.neurology.org/cgi/collection/visual_processing
Permissions & Licensing	Information about reproducing this article in parts (figures, tables) or in its entirety can be found online at: http://www.neurology.org/about/about_the_journal#permissions
Reprints	Information about ordering reprints can be found online: http://n.neurology.org/subscribers/advertise

Neurology® is the official journal of the American Academy of Neurology. Published continuously since 1951, it is now a weekly with 48 issues per year. Copyright © 2022 American Academy of Neurology. All rights reserved. Print ISSN: 0028-3878. Online ISSN: 1526-632X.

