

Teaching Video NeuroImage: Subacute Hemichorea Secondary to Disseminated *Cryptococcus* Infection in an Immunocompetent Host

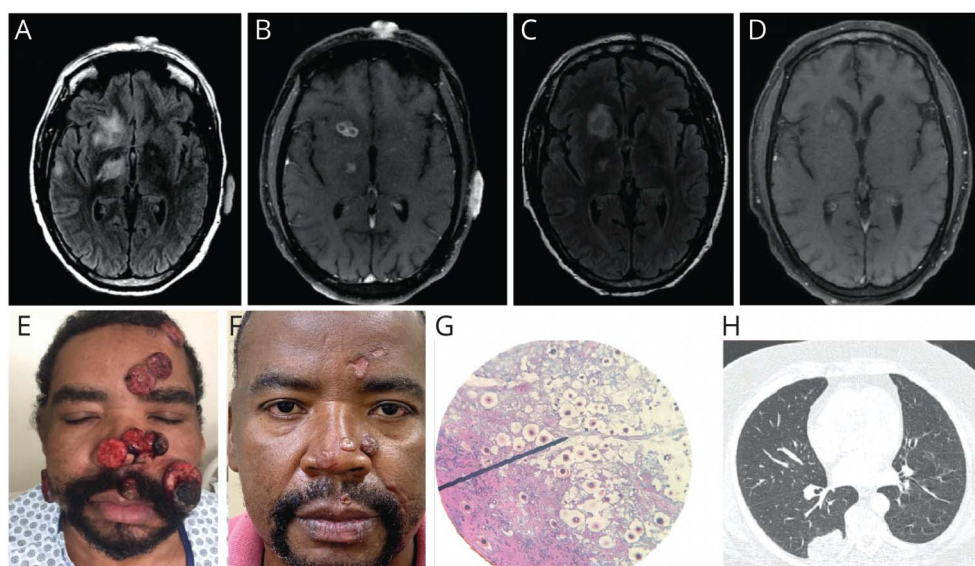
Mariana Hiromi Manoel Oku, MD, Carlos André Oshiro, MD, Cesar Castello Branco Lopes, MD, Michelle Abdo Paiva, MD, Bruno Guedes, MD, Marcia Rubia Rodrigues Gonçalves, MD, and Jacy Bezerra Parmera, MD, PhD

Correspondence

Mariana Hiromi Manoel Oku
mariana.hiromi@fm.usp.br

Neurology® 2022;99:36-37. doi:10.1212/WNL.0000000000200710

Figure Disseminated *Cryptococcosis* With Dermatologic, Pulmonary, and Neurologic Involvement



Brain MRI showing hyperintense T2/FLAIR right nucleocapsular lesions (A and C) with peripheral nodular enhancement in T1-weighted postcontrast sequences (B and D), at admission (A and B) and after 4-month therapy (C and D). Patient photographs show cutaneous lesions before (E) and after (F) treatment. Skin biopsy stained with Grocott's silver stain (G) identified oval yeasts compatible with cryptococcal infection. A chest CT scan (H) revealed a homogeneous subpleural pulmonary mass in the right lower lobe, compatible with cryptococcal infection and confirmed by a pulmonary biopsy.

A 52-year-old immunocompetent man presented with a 2-month history of weight loss, fever, and headache associated with cutaneous lesions in his face and upper limbs. A month later, he developed left-sided hemichorea (Video 1). Laboratory investigation revealed a positive serum cryptococcal antigen hemagglutination test. Skin and lung biopsies identified *Cryptococcus gattii*. Brain MRI showed right caudate and internal capsule T2/FLAIR hyperintense lesions compatible with cryptococcomas (Figure). Cryptococcal infections occasionally present as neurocryptococcosis but rarely as hemichorea, especially in immunocompetent hosts.^{1,2} After induction therapy with IV amphotericin B plus flucytosine followed by voriconazole, hemichorea (Video 1) and neuroimaging (Figure) improved significantly.

MORE ONLINE

▶ Video

Teaching Slides

links.lww.com/WNL/C20

Study Funding

No targeted funding reported.

From the Department of Neurology, Hospital das Clínicas, Faculdade de Medicina da Universidade de São Paulo (HC-FMUSP), São Paulo, SP, Brazil.

Go to Neurology.org/N for full disclosures. Funding information and disclosures deemed relevant by the authors, if any, are provided at the end of the article.

Disclosure

The authors report no disclosures relevant to the manuscript. Go to [Neurology.org/N](https://www.neurology.org/N) for full disclosures.

Publication History

Received by *Neurology* December 23, 2021. Accepted in final form March 24, 2022. Submitted and externally peer reviewed. The handling editor was Whitley Aamodt, MD, MPH.

Appendix Authors

Name	Location	Contribution
Mariana Hiromi Manoel Oku, MD	Universidade de São Paulo, São Paulo, SP, BR	Conception and design; acquisition, analysis, and interpretation of data; literature review; drafting of the manuscript and critical revision; supervision; and final approval
Carlos Andre Oshiro, MD	Universidade de São Paulo, São Paulo, SP, BR	Conception and design; acquisition, analysis, and interpretation of data; literature review; drafting of the manuscript and critical revision; supervision; and final approval
Bruno Fukelmann Guedes, MD	Universidade de São Paulo, São Paulo, SP, BR	Conception and design; acquisition, analysis, and interpretation of data; literature review; drafting of the manuscript and critical revision; supervision; and final approval

Appendix (continued)

Name	Location	Contribution
Michelle Abdo Paiva, MD	Universidade de São Paulo, São Paulo, SP, BR	Acquisition, analysis, and interpretation of data; critical revision; supervision; and final approval
Cesar Castello Branco Lopes, MD	Universidade de São Paulo, São Paulo, SP, BR	Acquisition, analysis, and interpretation of data; critical revision; supervision; and final approval
Marcia Rubia Rodrigues Gonçalves, MD	Universidade de São Paulo, São Paulo, SP, BR	Critical revision; supervision; and final approval
Jacy Bezerra Parmera, MD, PhD	Universidade de São Paulo, São Paulo, SP, BR	Conception and design; acquisition, analysis, and interpretation of data; literature review; drafting of the manuscript and critical revision; supervision; and final approval

References

1. Teive HA, Troiano AR, Cabral NL, Becker NI, Werneck LC. Hemichorea-hemiballism associated to cryptococcal granuloma in a patient with AIDS: case report. *Arq Neuropsiquiatr*. 2000;58(3B):965-968.
2. Weeks RA, Clough CG. Hemichorea due to cryptococcal meningitis. *Mov Disord*. 1995;10(4):522-.

Cultivating Leaders. Building Neurology's Future.

AAN Leadership Development Programs incorporate training, personalized coaching, and mentoring, that inspires and transforms neurologists into the change leaders of tomorrow. Explore the many AAN leadership programs at [AAN.com/Lead](https://www.aan.com/Lead).

The AAN Has Your Back!

Every day, the AAN is fighting for you. From actively lobbying members of Congress for common sense legislation, to meeting with regulators to demonstrate the value of neurology and reduce regulatory hassles, the Academy is forcefully countering any threats to your profession and patient access to care. Learn more at [AAN.com/policy-and-guidelines](https://www.aan.com/policy-and-guidelines), read the bimonthly Capitol Hill Report and monthly *AANnews*® member magazine, and respond to Advocacy Action Alert emails when we invite you to share your voice with Congress.

Get into the conversation at [#AANAdvocacy](https://twitter.com/AANAdvocacy).

Neurology®

Teaching Video NeuroImage: Subacute Hemichorea Secondary to Disseminated *Cryptococcus* Infection in an Immunocompetent Host
Mariana Hiromi Manoel Oku, Carlos André Oshiro, Cesar Castello Branco Lopes, et al.
Neurology 2022;99;36-37 Published Online before print May 6, 2022
DOI 10.1212/WNL.0000000000200710

This information is current as of May 6, 2022

Updated Information & Services	including high resolution figures, can be found at: http://n.neurology.org/content/99/1/36.full
References	This article cites 2 articles, 0 of which you can access for free at: http://n.neurology.org/content/99/1/36.full#ref-list-1
Subspecialty Collections	This article, along with others on similar topics, appears in the following collection(s): All Infections http://n.neurology.org/cgi/collection/all_infections All Movement Disorders http://n.neurology.org/cgi/collection/all_movement_disorders Chorea http://n.neurology.org/cgi/collection/chorea Clinical neurology examination http://n.neurology.org/cgi/collection/clinical_neurology_examination Fungal infections http://n.neurology.org/cgi/collection/fungal_infections
Permissions & Licensing	Information about reproducing this article in parts (figures, tables) or in its entirety can be found online at: http://www.neurology.org/about/about_the_journal#permissions
Reprints	Information about ordering reprints can be found online: http://n.neurology.org/subscribers/advertise

Neurology® is the official journal of the American Academy of Neurology. Published continuously since 1951, it is now a weekly with 48 issues per year. Copyright © 2022 American Academy of Neurology. All rights reserved. Print ISSN: 0028-3878. Online ISSN: 1526-632X.

