

Teaching NeuroImage: Atypical Anterior Cerebral Artery Syndrome From Pericallosal Artery Infarct

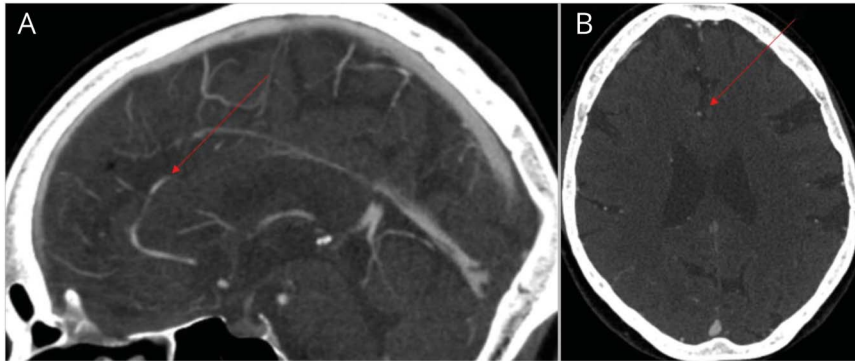
Diana J. Kim, MD,* Sina Marzoughi, MD,* and Thalia S. Field, MD, MHSc, FRCPC

Neurology® 2022;98:e209-e210. doi:10.1212/WNL.0000000000013002

Correspondence

Dr. Kim
dianajkim@alumni.ubc.ca

Figure 1 CT Angiogram Demonstrates Acute Occlusion (Red Arrow) of A3 Segment of Left ACA Artery in the Pericallosal Branch



A 76-year-old right-handed woman presented with sudden right-sided weakness and mutism. Examination revealed transcortical motor aphasia, right arm apraxia and spasticity, and right leg hemiplegia. She demonstrated abulia, anosognosia, and emotional lability. CT angiogram demonstrated a left pericallosal artery occlusion (Figure 1). The patient received tPA. MRI demonstrated an infarct spanning the left supplementary motor area (SMA) and anterior cingulate cortex (Figure 2).¹

Acute onset of aphasia, contralateral dyspraxia, and motor hemineglect should raise suspicion for SMA territory infarct while anterior cingulate involvement may result in acute spasticity and neuropsychiatric symptoms; these are rarely reported simultaneously in ACA infarcts.¹ Atypical ACA stroke syndromes are rare; clinical recognition avoids misdiagnosis.^{1,2}

Study Funding

The authors report no targeted funding.

Disclosure

The authors report no disclosures relevant to the manuscript. Go to [Neurology.org/N](https://www.neurology.org/N) for full disclosures.

MORE ONLINE

Teaching slides

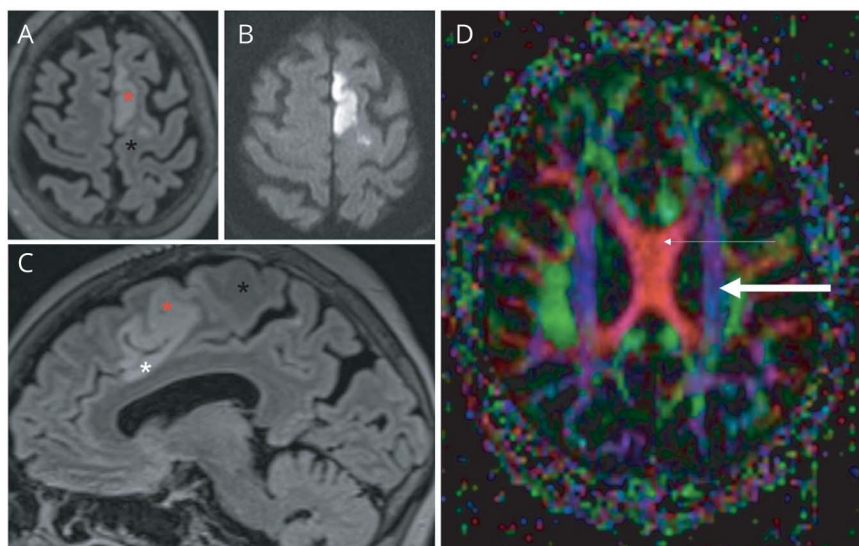
links.lww.com/WNL/B632

*These authors contributed equally to this work as first authors.

From the Department of Neurology, University of British Columbia, Vancouver, BC, Canada.

Go to [Neurology.org/N](https://www.neurology.org/N) for full disclosures.

Figure 2 Follow-up MRI Showing Axial FLAIR (A), DWI (B), Sagittal FLAIR (C), and Axial DTI (D) Sequences



MRI confirms the area of infarct involving the supplementary motor area (red asterisk), cingulate cortex (white asterisk), and sparing of the primary motor cortex (black asterisk), with corresponding DWI restriction. Axial DTI sequences confirm the sparing of corticospinal tracts (thick arrow) and commissural fibres (thin arrow).

Appendix Authors

Name	Location	Contribution
Diana J. Kim, MD	University of British Columbia, Vancouver, Canada	Drafted and revised the manuscript and prepared figures
Sina Marzoughi, MD	University of British Columbia, Vancouver, Canada	Drafted and revised the manuscript and prepared figures
Thalia S. Field, MD, MHSc, FRCPC	University of British Columbia, Vancouver, Canada	Revised manuscript for intellectual content

References

1. Kang SY, Kim JS. Anterior cerebral artery infarction: stroke mechanism and clinical-imaging study in 100 patients. *Neurology*. 2008;70(24 pt 2):2386-2393.
2. Mathew P, Batchala PP, Muttikkal T. Supplementary motor area stroke mimicking functional disorder. *Stroke*. 2018;49(10):e28-30.

Neurology®

Teaching NeuroImage: Atypical Anterior Cerebral Artery Syndrome From Pericallosal Artery Infarct

Diana J. Kim, Sina Marzoughi and Thalia S. Field

Neurology 2022;98:e209-e210 Published Online before print October 21, 2021

DOI 10.1212/WNL.0000000000013002

This information is current as of October 21, 2021

Updated Information & Services	including high resolution figures, can be found at: http://n.neurology.org/content/98/2/e209.full
References	This article cites 2 articles, 2 of which you can access for free at: http://n.neurology.org/content/98/2/e209.full#ref-list-1
Subspecialty Collections	This article, along with others on similar topics, appears in the following collection(s): Agnosia http://n.neurology.org/cgi/collection/agnosia All Cerebrovascular disease/Stroke http://n.neurology.org/cgi/collection/all_cerebrovascular_disease_stroke Aphasia http://n.neurology.org/cgi/collection/aphasia Apraxia http://n.neurology.org/cgi/collection/apraxia Neglect http://n.neurology.org/cgi/collection/neglect
Permissions & Licensing	Information about reproducing this article in parts (figures, tables) or in its entirety can be found online at: http://www.neurology.org/about/about_the_journal#permissions
Reprints	Information about ordering reprints can be found online: http://n.neurology.org/subscribers/advertise

Neurology® is the official journal of the American Academy of Neurology. Published continuously since 1951, it is now a weekly with 48 issues per year. Copyright © 2021 American Academy of Neurology. All rights reserved. Print ISSN: 0028-3878. Online ISSN: 1526-632X.

