

Clinical Reasoning: A 45-Year-Old Man With Vertical Diplopia

Neel Fotedar, MD, Junling Dong, DO, Alexander Lewis, DO, Michael Devereaux, MD, and Alessandro Serra, MD, PhD

Neurology® 2022;98:82-87. doi:10.1212/WNL.0000000000012999

Correspondence

Dr. Fotedar
neel.fotedar@
uhhospitals.org

Section 1

A 45-year-old man with known hypertension presented with double vision ongoing for several weeks. He described seeing objects as if they were stacked on top of each other. This double vision disappeared when he closed either eye. He denied any diurnal variation of his symptoms and any associated limb weakness. He denied any history of dysphagia and dysarthria. He denied any history of thyroid disease. He did report intermittent numbness on the left side of his tongue.

Examination revealed left eye adduction paresis with dissociated nystagmus of the abducting right eye with attempted rightward gaze. In primary gaze, the left eye was elevated compared with the right eye. When looking toward the left, the vertical misalignment was less pronounced, whereas assessment in right gaze was not possible because of the left eye adduction deficit. The left eye hypertropia was worse with a leftward head tilt and improved with a rightward head tilt. There was no significant change in vertical misalignment when supine vs when upright. Convergence was intact. Lid retraction, ptosis, proptosis, and periorbital swelling were absent. There were no other significant findings on neurologic examination.

Questions for Consideration:

1. What is the differential diagnosis of vertical diplopia?
2. Where does left eye adduction paresis on conjugate rightward gaze localize?
3. What is the Parks-Bielschowsky test?

GO TO SECTION 2

From the Department of Neurology (N.F., A.L., M.D., A.S.), University Hospitals Cleveland Medical Center; Case Western Reserve University (N.F., A.L., M.D., A.S.), OH; Department of Neurology (J.D.), Washington University, St. Louis, MO; and Louis Stokes Cleveland VA Medical Center (A.L., A.S.), OH.

Go to [Neurology.org/N](https://www.neurology.org/N) for full disclosures. Funding information and disclosures deemed relevant by the authors, if any, are provided at the end of the article.

Section 2

The patient in this vignette presented with acute onset of vertical binocular diplopia. Binocular diplopia is a result of misalignment of visual axes and is typically due to an extraocular motility defect, which can be a result of various pathologies affecting the extraocular muscles, the neuromuscular junction (NMJ), or the cranial nerves anywhere along their course. In addition, a lesion in the brainstem causing a skew deviation can also lead to vertical binocular diplopia. Monocular diplopia is usually caused by ophthalmic pathology such as refractive error, astigmatism, and corneal disease. It can also be caused by retinal pathology.

With rightward gaze, the left eye adduction was incomplete and the abducting right eye showed dissociated nystagmus. This finding is consistent with left internuclear ophthalmoplegia (INO), which localizes to the left medial longitudinal fasciculus (MLF). Convergence remains intact with MLF lesion unless the lesion involves the convergence pathways in the midbrain.⁶

For vertical diplopia, the possible affected muscles include either the superior rectus (SR) or inferior oblique (IO) of the hypotropic eye vs the inferior rectus (IR) or superior oblique (SO) of the hypertropic eye. The Parks-Bielschowsky three-step test helps localize the affected muscles (Figures 1A–C).¹

Step 1: Which eye is hypertropic in the primary position? In this case, it was the left eye.

Step 2: Is the misalignment worse in 1 particular horizontal gaze direction? In our patient, the left eye hypertropia was less pronounced with leftward gaze, which suggests that the left IR was normal. Therefore, the dysfunction could have been with the left SO or right SR. It was impossible to assess the degree of left eye hypertropia in rightward gaze because of left INO.

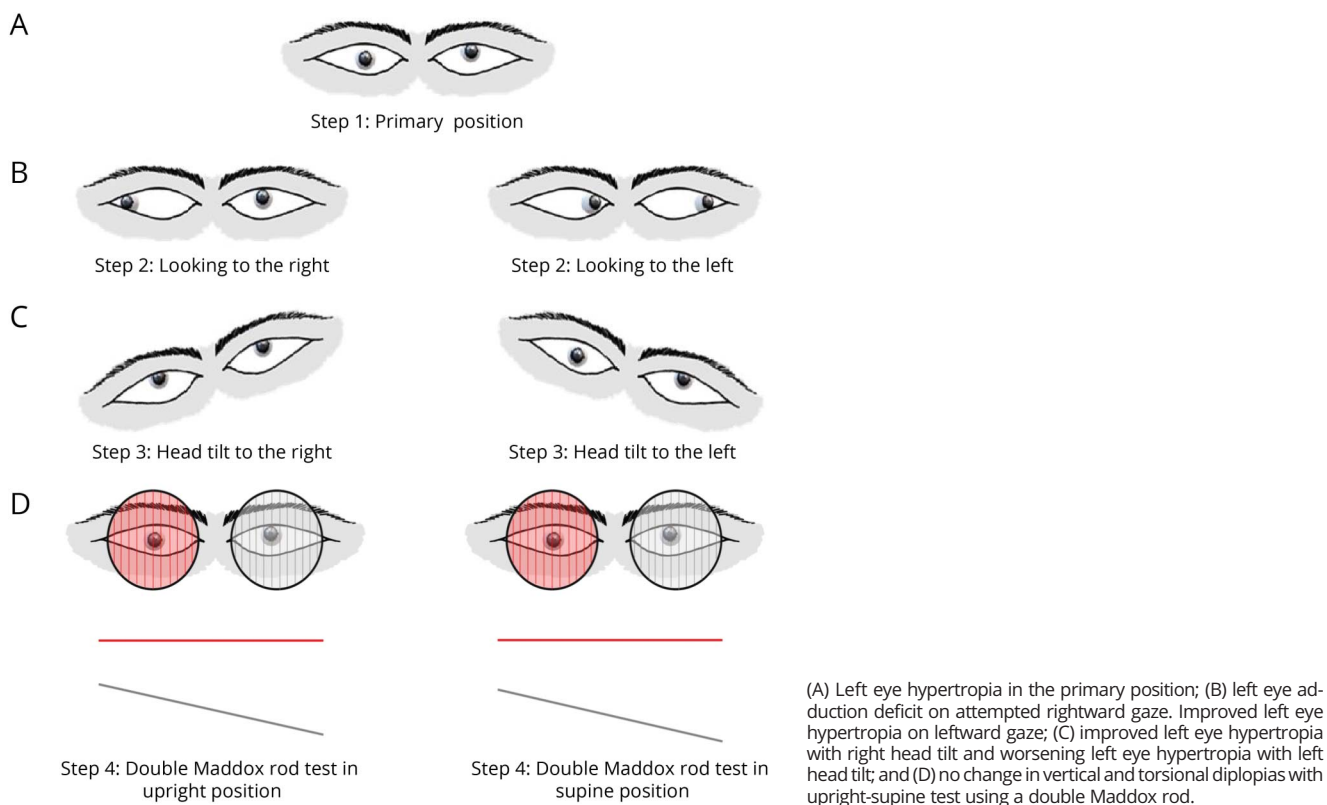
The principle underlying this maneuver is that in every cardinal position of gaze, there is an extraocular muscle, which is a prime mover. The goal is to isolate that muscle based on the maximum separation of images (worsening diplopia) in the direction of the affected muscle being tested.⁶

Step 3: Is the misalignment worse with leftward head tilt or rightward head tilt? In our patient, it was worse with leftward head tilt, which localizes the deficit to left SO.

In leftward head tilt, the left eye intorts through the left SO (intorsion with depression) and left SR (intorsion with elevation). With a weak SO, the SR is left unopposed and causes an elevation of the left eye, thus worsening the hypertropia, as was seen in our patient. Thus, the most likely explanation of this patient's vertical diplopia is a left SO palsy.

An alternative cause of ocular vertical misalignment is skew deviation. Normally, the findings in the Parks-Bielschowsky

Figure 1 Parks-Bielschowsky Test and Upright-Supine Test



test can differentiate skew deviation from trochlear nerve palsy.⁶ However, in our case; the test was partly limited because of the left INO.

Question for Consideration:

1. How can trochlear nerve palsy be distinguished from skew deviation?

GO TO SECTION 3

Section 3

The upright-supine test is a reliable test to distinguish skew deviation from trochlear nerve palsy.²

With skew deviation, a positive upright-supine test shows a 50% or greater reduction in the vertical and the torsional deviation measured from the upright to the supine position.² The torsional deviation can be quantified using a double Maddox rod test, and the vertical deviation can be quantified by an alternate cover test and prisms. The change in position from upright to supine causes a change in the orientation of the utricle regarding gravity. This causes an overall reduction

in the activity of bilateral utricular projections, thus diminishing the asymmetry as well.²

In this case, there was no significant difference in the degree of vertical misalignment between upright and supine positions (Figure 1D). The patient was reliably able to describe his subjective degree of diplopia in both positions. One limitation of our study is that we did not quantify the deviations using prisms.

Questions for Consideration:

1. Where do these examination findings localize?
2. What are the differential diagnoses for such a presentation?

GO TO SECTION 4

Section 4

A single lesion affecting the MLF and trochlear nerve nucleus or fibers before decussation would present with INO and a contralateral SO palsy.^{3,4} But in this case, there were likely 2 lesions, one involving the left MLF resulting in a left INO and the other lesion involving the postdecussation left trochlear nerve fibers in the left dorsal midbrain, originating from the right trochlear nucleus, resulting in a left SO palsy (Figure 2A).

Differential Diagnoses

Multiple lesions affecting the MLF and the trochlear nerve fibers are indicative of multifocal CNS pathology such as multiple sclerosis or multiple infarcts in the brainstem. Diseases affecting NMJ such as myasthenia gravis and those affecting extraocular muscles such as thyroid eye disease are great mimickers and should always be on the differential for such cases with multifocal localization.

Final Diagnosis

The patient's brain MRI examination showed a lesion in the left dorsal midbrain and multiple other lesions in the supra and infratentorial white matter (Figure 2B). The left dorsal midbrain lesion had evidence of postcontrast enhancement as well, thus confirming a new diagnosis of multiple sclerosis. The patient's symptoms improved with corticosteroids. He was eventually transitioned to ocrelizumab and remained relapse-free.

Discussion

In patients with INO, the more common cause of a vertical misalignment is a skew deviation, which is caused by interruption of the central otolithic pathways.⁶ The vestibular

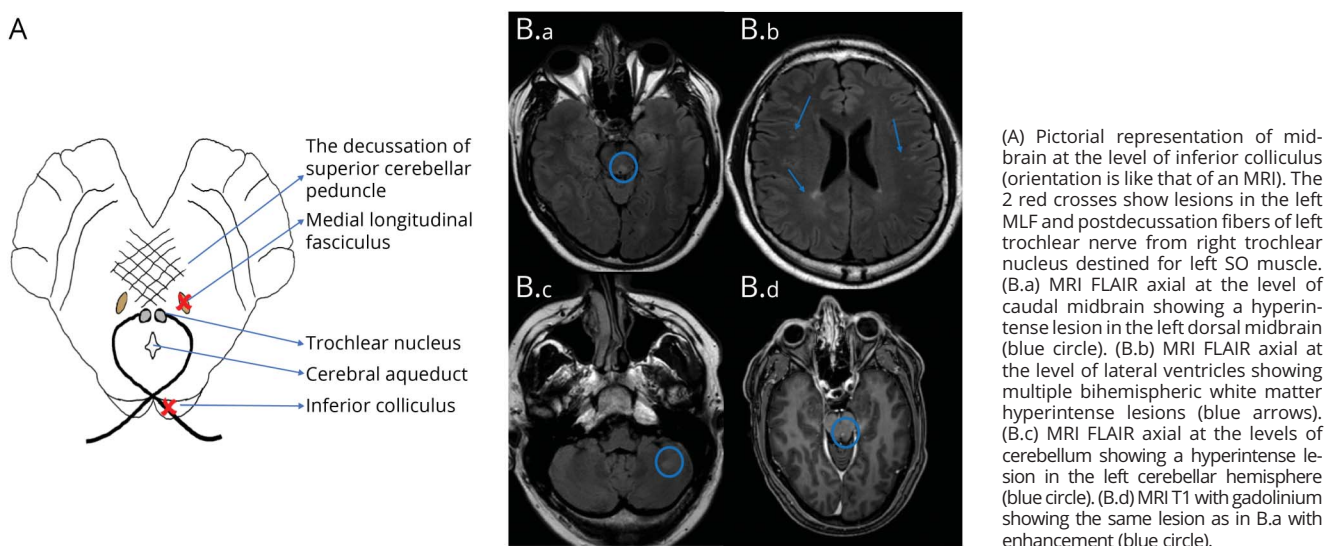
signals from the utricle (e.g., during head tilt) project primarily to laterodorsal medial vestibular nucleus and ventrolateral superior vestibular nucleus. These nuclei, in turn, project to the ocular motorneurons controlling vertical and torsional eye movements. This projection is crossed and ascends in the brainstem through the MLF.⁶ This is the pathway for the vestibulo-ocular reflex in the roll plane. A part of this projection also reaches the interstitial nucleus of Cajal, which plays an important role in coordinating eye and head movements in the roll plane.⁶ A lesion affecting these pathways inferior to the pontomesencephalic junction causes the ipsilateral eye to be hypotropic, and a lesion superior to the pontomesencephalic junction causes the ipsilateral eye to be hypertropic.⁷

Because the MLF is a common substrate shared by the horizontal conjugate gaze and the central otolithic pathways, it is typical to see a skew deviation with an INO in the setting of lesions affecting the MLF.

The misalignment in skew deviation is typically comitant (i.e., unchanged in all directions of gaze) unlike incomitant strabismus (i.e., different degree of misalignment in different gaze directions) observed with SO palsy while performing the Parks-Bielschowsky test.⁶ Our examination, as noted earlier, was not consistent with a skew deviation. In addition, the upright-supine test did not favor a skew deviation either.

A combination of INO and trochlear nerve palsy has been rarely reported in the literature.^{3,4} The typical presentation is that of INO with a contralateral superior oblique palsy as explained by a single lesion affecting the MLF and trochlear nucleus or the intraparenchymal fibers of trochlear nerve before decussation in the dorsal midbrain.³⁻⁵

Figure 2 Neuroanatomic Localization and Brain MRI



What is unusual in our case is the co-occurrence of INO with ipsilateral SO palsy. This combination can only be explained by 2 separate lesions: one affecting the MLF and the other affecting the postdecussation trochlear nerve fibers, originating from the contralateral trochlear nucleus, in the ipsilateral dorsal midbrain (Figure 2A). Such a presentation is more likely to be caused by multifocal pathology such as multiple sclerosis or posterior circulation infarcts affecting different parts of the brainstem. In this case, the diagnosis was multiple sclerosis.

In clinical neurology, we often seek to explain all the findings by a single lesion, which is usually the simplest and the more elegant explanation (Occam's razor). However, as Hickam's dictum states, "patients can have as many diseases (or lesions) as they please."

Study Funding

The authors report no targeted funding.

Disclosure

N. Fotedar, J. Dong, A. Lewis, and M. Devereaux report no disclosures relevant to the manuscript; A. Serra receives consultant/speaker fees from Biogen Idec. Go to Neurology.org/N for full disclosures.

Appendix Authors

| Name | Location | Contribution |
|-------------------------|---|---|
| Neel Fotedar, MD | Department of Neurology, University Hospitals Cleveland Medical Center; Case Western Reserve University, OH | Drafting/revision of the article for content, including medical writing for content; major role in the acquisition of data; study concept or design; and analysis or interpretation of data |

Appendix (continued)

| Name | Location | Contribution |
|----------------------------------|---|---|
| Junling Dong, DO | Department of Neurology, Washington University, St. Louis, MO | Drafting/revision of the article for content, including medical writing for content; major role in the acquisition of data; and study concept or design |
| Alexander Lewis, DO | Department of Neurology, University Hospitals Cleveland Medical Center; Case Western Reserve University, OH; Louis Stokes Cleveland VA Medical Center, OH | Major role in the acquisition of data and study concept or design |
| Michael Devereaux, MD | Department of Neurology, University Hospitals Cleveland Medical Center; Case Western Reserve University, OH | Drafting/revision of the article for content, including medical writing for content, and analysis or interpretation of data |
| Alessandro Serra, MD, PhD | Department of Neurology, University Hospitals Cleveland Medical Center; Case Western Reserve University, OH; Louis Stokes Cleveland VA Medical Center, OH | Drafting/revision of the article for content, including medical writing for content; study concept or design; and analysis or interpretation of data |

References

1. Bielschowsky A: Lecture on motor anomalies of the eyes: II. Paralysis of individual eye muscles. *Arch Ophthalmol (Chicago)*. 1935;13:33-59.
2. Wong AM. Understanding skew deviation and a new clinical test to differentiate it from trochlear nerve palsy. *J AAPOS*. 2010;14(1):61-67.
3. Vanooteghem P, Dehaene I, Van Zandycke M, Casselman J. Combined trochlear nerve palsy and internuclear ophthalmoplegia. *Arch Neurol*. 1992;49(1):108-109.
4. Borgman CJ. Trochlear nerve palsy and contralateral internuclear ophthalmoplegia: an unusual crossed syndrome. *Clin Exp Optom*. 2020;103(5):715-716.
5. Miller NR. Pearls and oysters: central fourth nerve palsies. *Neurology*. 2013;81(6):603.
6. Zee DS, John Leigh R. *The Neurology of Eye Movements*, 5th ed. Oxford University Press; 2015.
7. Brandt T, Dieterich M. Skew deviation with ocular torsion: a vestibular brainstem sign of topographic diagnostic value. *Ann Neurol*. 1993;33(5):528-534.

Call for Voices: Lived Experiences

The Editors of the *Neurology* specialty section Inclusion, Diversity, Equity, Anti-racism, & Social Justice (IDEAS) encourage you to submit short first-person accounts (1,000 words or less) of experiences lived within the realm of IDEAS with the goal of informing and enlightening our community on these critical issues. Some topics to consider include, but are not limited to:

- Descriptions of personal experiences that shaped your views of IDEAS.
- Reflections on the intersection between personal identity and career.
- Discussions at the intersection of IDEAS and neurology patient care, research, education, advocacy, or policy.

Submit your contributions to journal@neurology.org and include "Voices Submission" in the subject line.

Neurology®

Clinical Reasoning: A 45-Year-Old Man With Vertical Diplopia

Neel Fotedar, Junling Dong, Alexander Lewis, et al.

Neurology 2022;98:82-87 Published Online before print October 21, 2021

DOI 10.1212/WNL.0000000000012999

This information is current as of October 21, 2021

| | |
|---|--|
| Updated Information & Services | including high resolution figures, can be found at: http://n.neurology.org/content/98/2/82.full |
| References | This article cites 6 articles, 1 of which you can access for free at: http://n.neurology.org/content/98/2/82.full#ref-list-1 |
| Citations | This article has been cited by 1 HighWire-hosted articles: http://n.neurology.org/content/98/2/82.full##otherarticles |
| Subspecialty Collections | This article, along with others on similar topics, appears in the following collection(s): Diplopia (double vision) http://n.neurology.org/cgi/collection/diplopia_double_vision Multiple sclerosis http://n.neurology.org/cgi/collection/multiple_sclerosis |
| Permissions & Licensing | Information about reproducing this article in parts (figures, tables) or in its entirety can be found online at: http://www.neurology.org/about/about_the_journal#permissions |
| Reprints | Information about ordering reprints can be found online: http://n.neurology.org/subscribers/advertise |

Neurology® is the official journal of the American Academy of Neurology. Published continuously since 1951, it is now a weekly with 48 issues per year. Copyright © 2021 American Academy of Neurology. All rights reserved. Print ISSN: 0028-3878. Online ISSN: 1526-632X.

