

# Teaching NeuroImages: Stroke With Nondecussating Corticospinal Tracts Causing Ipsilateral Weakness

## Straight Forward

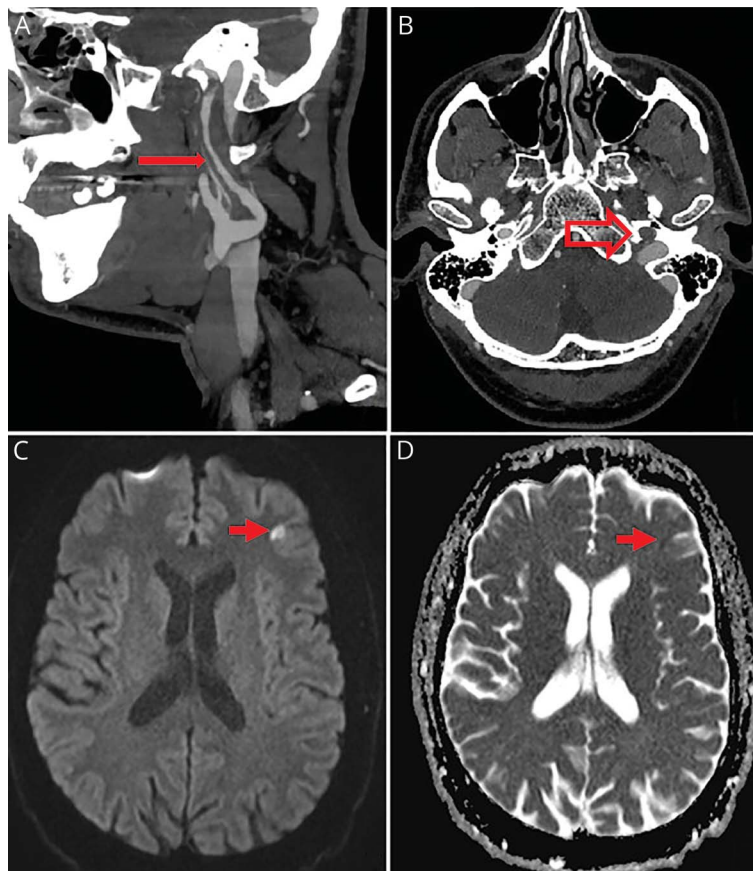
Lily W. Zhou, MD, Jason Chew, MBChB, FRCPC, and Thalia S. Field, MHSc, MD, FRCP

*Neurology*® 2021;96:e480-e481. doi:10.1212/WNL.0000000000010804

### Correspondence

Dr. Field  
thalia.field@ubc.ca

**Figure 1** CT Angiogram and Diffusion Weighted MRI



CT angiogram showing left carotid dissection with luminal irregularity and mural thickening of the left carotid from C2 up to the carotid canal on sagittal image (panel A, long solid arrow) and reduced opacification at the carotid canal on axial image (panel B, large hollow arrow). Axial MRI head showing restricted diffusion on B1000 diffusion weighted imaging (panel C, short solid arrow) and apparent diffusion coefficient (panel D, short solid arrow) demonstrating left-sided subacute frontal stroke.

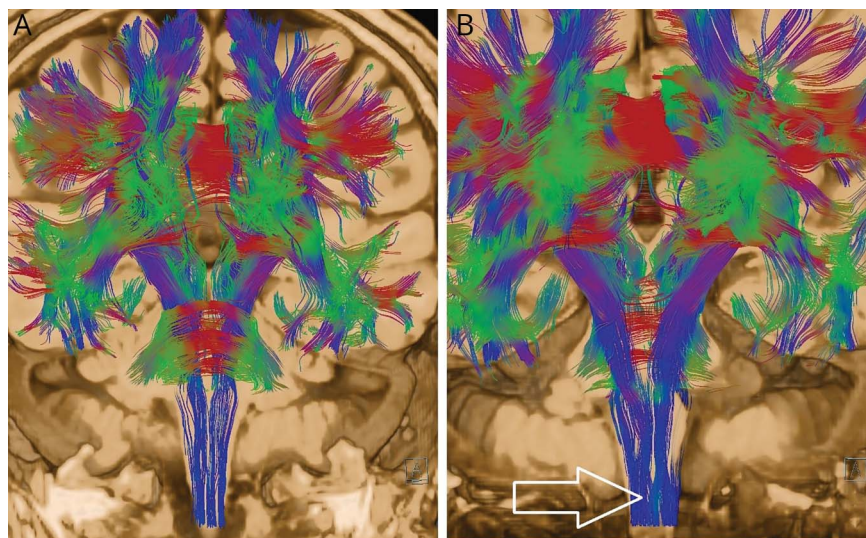
A 43-year-old man presented with left carotid dissection. Examination showed left-sided Horner, left facial weakness, and left pronator drift. MRI brain showed a small left frontal infarct (figure 1), with no other areas of infarction and nondecussating corticospinal tracts on diffusion tensor imaging (figure 2).

### MORE ONLINE

→ **Teaching slides**  
[links.lww.com/WNL/B212](https://links.lww.com/WNL/B212)

From the Department of Neurology (L.W.Z., T.S.F.), University of British Columbia; and Department of Radiology (J.C.), University of British Columbia, Vancouver, Canada. Go to [Neurology.org/N](https://Neurology.org/N) for full disclosures. Funding information and disclosures deemed relevant by the authors, if any, are provided at the end of the article.

**Figure 2** Diffusion Tensor Imaging



Coronal reformatted diffusion tensor imaging showing nondecussation of white matter tracts in the caudal medulla (panel A) compared with normal control (panel B, arrow showing decussation).

Several congenital syndromes are associated with non-decussating tracts and mirror movements.<sup>1</sup> The prevalence of nondecussating corticospinal tracts in the general population is unknown. Ipsilateral hemiparesis is also reported with previous contralateral infarcts possibly from the disruption of compensating normal uncrossed corticospinal fibres.<sup>2</sup> This patient has no baseline impairment and demonstrates non-decussating tracts as an anatomical variant.

### Study Funding

No targeted funding reported.

### Disclosure

The authors report no disclosures relevant to the manuscript. Go to [Neurology.org/N](http://Neurology.org/N) for full disclosures.

### Appendix Authors

Author	Location	Contribution
Lily W. Zhou, MD	University of British Columbia, Vancouver, Canada	Drafted the manuscript for intellectual content and prepared the figures for publications
Jason Chew, MBChB, FRCPC	University of British Columbia, Vancouver, Canada	Revised the manuscript for intellectual content and prepared the figures for publications
Thalia S. Field, MSc, MD, FRCPC	University of British Columbia, Vancouver, Canada	Drafted the manuscript for intellectual content and communicated with the patient for informed consent

### References

1. Sag E, Gocmen R, Yildiz FG, et al. Congenital mirror movements in Gorlin syndrome: a case report with DTI and functional MRI features. *Pediatrics* 2016;137:e20151771.
2. Inatomi Y, Nakajima M, Yonehara T, Ando Y. Ipsilateral hemiparesis in ischemic stroke patients. *Acta Neurol Scand* 2017;136:31–40.

# Neurology<sup>®</sup>

## Teaching NeuroImages: Stroke With Nondecussating Corticospinal Tracts Causing Ipsilateral Weakness: Straight Forward

Lily W. Zhou, Jason Chew and Thalia S. Field

*Neurology* 2021;96:e480-e481 Published Online before print September 9, 2020

DOI 10.1212/WNL.0000000000010804

**This information is current as of September 9, 2020**

<b>Updated Information &amp; Services</b>	including high resolution figures, can be found at: <a href="http://n.neurology.org/content/96/3/e480.full">http://n.neurology.org/content/96/3/e480.full</a>
<b>References</b>	This article cites 2 articles, 0 of which you can access for free at: <a href="http://n.neurology.org/content/96/3/e480.full#ref-list-1">http://n.neurology.org/content/96/3/e480.full#ref-list-1</a>
<b>Subspecialty Collections</b>	This article, along with others on similar topics, appears in the following collection(s): <b>All Cerebrovascular disease/Stroke</b> <a href="http://n.neurology.org/cgi/collection/all_cerebrovascular_disease_stroke">http://n.neurology.org/cgi/collection/all_cerebrovascular_disease_stroke</a> <b>All Education</b> <a href="http://n.neurology.org/cgi/collection/all_education">http://n.neurology.org/cgi/collection/all_education</a> <b>Cortical localization</b> <a href="http://n.neurology.org/cgi/collection/cortical_localization">http://n.neurology.org/cgi/collection/cortical_localization</a> <b>MRI</b> <a href="http://n.neurology.org/cgi/collection/mri">http://n.neurology.org/cgi/collection/mri</a>
<b>Permissions &amp; Licensing</b>	Information about reproducing this article in parts (figures, tables) or in its entirety can be found online at: <a href="http://www.neurology.org/about/about_the_journal#permissions">http://www.neurology.org/about/about_the_journal#permissions</a>
<b>Reprints</b>	Information about ordering reprints can be found online: <a href="http://n.neurology.org/subscribers/advertise">http://n.neurology.org/subscribers/advertise</a>

*Neurology*® is the official journal of the American Academy of Neurology. Published continuously since 1951, it is now a weekly with 48 issues per year. Copyright © 2020 American Academy of Neurology. All rights reserved. Print ISSN: 0028-3878. Online ISSN: 1526-632X.

