

Teaching NeuroImages: All Hemiparesis Are Not Contralateral

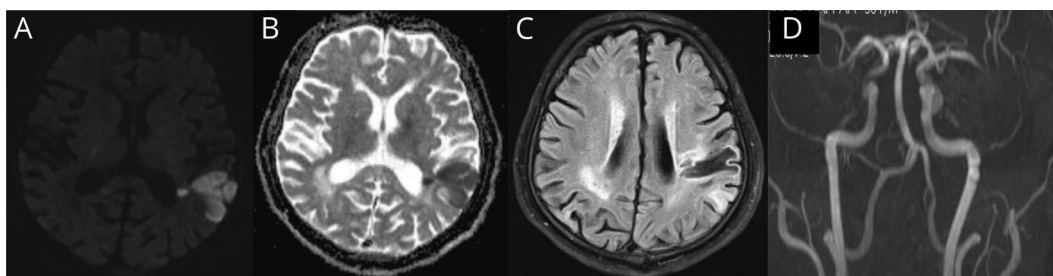
Y. Muralidhar Reddy, DM (Neurology), ASN (Certification), Subhendu Parida, DM (Neuroradiology), and Jagarlapudi M.K. Murthy, DM (Neurology), FAAN

Correspondence

Y. Muralidhar Reddy
muralidharnims@gmail.com

Neurology® 2021;96:e478-e479. doi:10.1212/WNL.0000000000010755

Figure 1 MRI Axial Images Showing Diffusion Restriction and Corresponding ADC Reversal Suggestive of Acute Infarct in Left Inferior Parietal Lobe (A–B); FLAIR Showing Gliotic Scar in Left Parietal Lobe (C); Angiogram Showing Left M2 Stenosis (D)



A 56-year-old hypertensive man presented with left-sided weakness of 2-hour duration. He made complete recovery from right hemiparesis because of left parietal infarct. Examination showed dysarthria and left hemiparesis (NIHSS 8/42). MRI brain showed both left parietal acute infarct and gliosis from old infarct (Figure 1). He was successfully thrombolysed with intravenous alteplase. Present stroke was diagnosed as ipsilateral hemiparesis, confirmed by diffusion tensor imaging (Figure 2). Ipsilateral hemiparesis, mostly seen with posterior fossa malformations and remote infarctions,¹ results from injury to uncrossed corticospinal tract (CST) in patients of remote brain injury or with no decussation of CST or injury to ipsilateral extrapyramidal motor pathway.²

MORE ONLINE

→ **Teaching slides**
links.lww.com/WNL/B204

Acknowledgment

The authors thank Dr. Suresh, MD, and Dr. Mahmood, MD, for assistance in compiling the pictures.

Study Funding

No targeted funding reported.

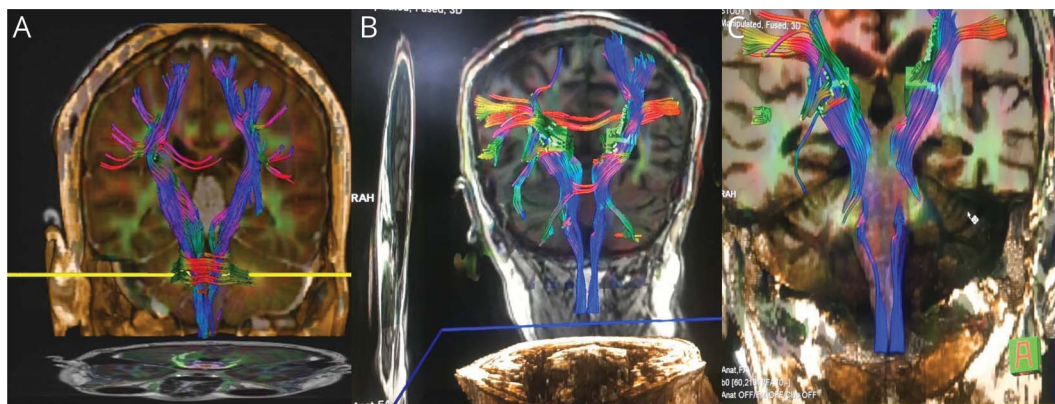
Disclosure

The authors report no disclosures relevant to the manuscript. Go to Neurology.org/N for full disclosures.

From the Department of Neurology, Care Hospital, Hyderabad, Telangana, India.

Go to Neurology.org/N for full disclosures. Funding information and disclosures deemed relevant by the authors, if any, are provided at the end of the article.

Figure 2 Diffusion Tensor Imaging Showing Normal Decussation of Pyramidal Tracts in Caudal Medulla in Normal Subjects (A); No Decussation in the Given Case (B-C)



Appendix Authors

Name	Location	Contribution
Y. Muralidhar Reddy, DM	Care Hospital, Hyderabad, India	Conceptualized and drafted the manuscript
Subhendu Parida, DM	Care Hospital, Hyderabad, India	Drafted the figures
Jagarlapudi M.K. Murthy, DM, FAAN	Care Hospital, Hyderabad, India	Revision of the manuscript

References

1. Saada F, Antonios N. Existence of ipsilateral hemiparesis in ischemic and hemorrhagic stroke: two case reports and review of the literature. *Eur Neurol* 2014;71:25–31.
2. Inatomi Y, Nakajima M, Yonehara T, Ando Y. Ipsilateral hemiparesis in ischemic stroke patients. *Acta Neurol Scand* 2017;136:31–40.

Neurology®

Teaching NeuroImages: All Hemiparesis Are Not Contralateral
Y. Muralidhar Reddy, Subhendu Parida and Jagarlapudi M.K. Murthy
Neurology 2021;96:e478-e479 Published Online before print September 4, 2020
DOI 10.1212/WNL.0000000000010755

This information is current as of September 4, 2020

Updated Information & Services	including high resolution figures, can be found at: http://n.neurology.org/content/96/3/e478.full
References	This article cites 2 articles, 0 of which you can access for free at: http://n.neurology.org/content/96/3/e478.full#ref-list-1
Subspecialty Collections	This article, along with others on similar topics, appears in the following collection(s): All Cerebrovascular disease/Stroke http://n.neurology.org/cgi/collection/all_cerebrovascular_disease_stroke All Clinical Neurology http://n.neurology.org/cgi/collection/all_clinical_neurology DWI http://n.neurology.org/cgi/collection/dwi Infarction http://n.neurology.org/cgi/collection/infarction MRI http://n.neurology.org/cgi/collection/mri
Permissions & Licensing	Information about reproducing this article in parts (figures, tables) or in its entirety can be found online at: http://www.neurology.org/about/about_the_journal#permissions
Reprints	Information about ordering reprints can be found online: http://n.neurology.org/subscribers/advertise

Neurology® is the official journal of the American Academy of Neurology. Published continuously since 1951, it is now a weekly with 48 issues per year. Copyright © 2020 American Academy of Neurology. All rights reserved. Print ISSN: 0028-3878. Online ISSN: 1526-632X.

