

# Teaching NeuroImages: Spinal cord herniation after cervical corpectomy

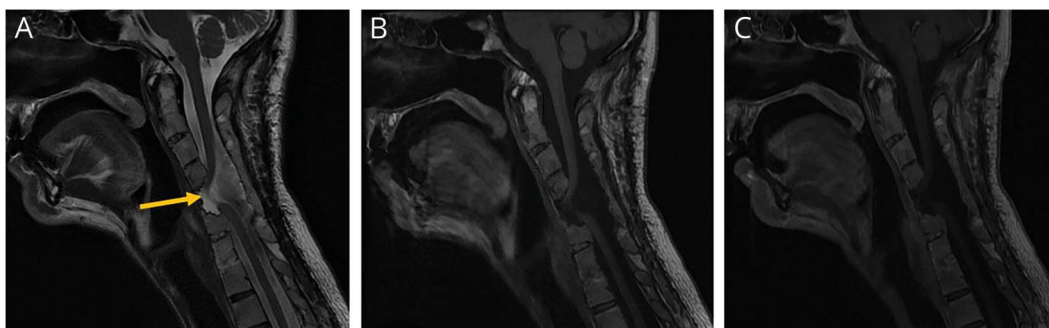
Melike Guryildirim, MD, Mehmet Kocak, MD, and Sumeet G. Dua, MD

*Neurology*® 2019;93:e1744. doi:10.1212/WNL.0000000000008401

**Correspondence**

Dr. Guryildirim  
mguryil1@jhmi.edu

## Figure Imaging



MRI shows spinal cord herniation into the C5 corpectomy defect ([A] sagittal T2-weighted image, [B] sagittal T1-weighted image without contrast, [C] sagittal T1-weighted image with contrast). Sagittal T2-weighted MRI shows herniation of the spinal cord anteriorly into the C5 corpectomy defect. There is marked thinning of the cervical cord at this level with abnormal T2 hyperintensity, compatible with myelomalacia (arrow in A). Precontrast and postcontrast T1-weighted images do not demonstrate any abnormal enhancement.

A 48-year-old man presented with worsening generalized pain. He had a history of complex cervical deformity and C2-T4 anterior and posterior instrumented fusions. On neurologic examination, cranial nerves, sensation, and strength were intact. Imaging demonstrated herniation of the spinal cord into the corpectomy defect and myelomalacia of the herniated cord (figure). Components of the patient's pain were attributed to myelomalacia. Spinal cord herniation (SCH), when iatrogenic, mostly occurs in the setting of posterior instrumentation and associated pseudomeningocele formation. SCH may also develop as a complication of anterior cervical decompression and underlying dural defect is the most likely mechanism.<sup>1,2</sup>

## MORE ONLINE

### →Teaching slides

[links.lww.com/WNL/A986](https://links.lww.com/WNL/A986)

## Author contributions

M. Guryildirim: drafting/revising the manuscript, data acquisition, study concept or design, analysis or interpretation of data, accepts responsibility for conduct of research and final approval, study supervision. M. Kocak: drafting/revising the manuscript, analysis or interpretation of data, accepts responsibility for conduct of research and final approval, study supervision. S.G. Dua: drafting/revising the manuscript, accepts responsibility for conduct of research and final approval, intellectual input.

## Study funding

No targeted funding reported.

## Disclosure

The authors report no disclosures relevant to the manuscript. Go to [Neurology.org/N](https://Neurology.org/N) for full disclosures.

## References

- Guppy KH, Silverthorn JW. Spinal cord herniation after cervical corpectomy with cerebrospinal fluid leak: case report and review of the literature. *World Neurosurg* 2017;100:711.e7–711.e12.
- Min JH, Jung BJ, Jang JS, Kim SK, Jung DJ, Lee SH. Spinal cord herniation after multilevel anterior cervical corpectomy and fusion for ossification of the posterior longitudinal ligament of the cervical spine. *J Neurosurg Spine* 2009;10:240–243.

From the Department of Diagnostic Radiology and Nuclear Medicine, Rush University Medical Center, Chicago, IL.

Go to [Neurology.org/N](https://Neurology.org/N) for full disclosures.

# Neurology®

## Teaching NeuroImages: Spinal cord herniation after cervical corpectomy

Melike Guryildirim, Mehmet Kocak and Sumeet G. Dua

*Neurology* 2019;93:e1744

DOI 10.1212/WNL.00000000000008401

**This information is current as of October 28, 2019**

<b>Updated Information &amp; Services</b>	including high resolution figures, can be found at: <a href="http://n.neurology.org/content/93/18/e1744.full">http://n.neurology.org/content/93/18/e1744.full</a>
<b>References</b>	This article cites 2 articles, 0 of which you can access for free at: <a href="http://n.neurology.org/content/93/18/e1744.full#ref-list-1">http://n.neurology.org/content/93/18/e1744.full#ref-list-1</a>
<b>Subspecialty Collections</b>	This article, along with others on similar topics, appears in the following collection(s): <b>All Pain</b> <a href="http://n.neurology.org/cgi/collection/all_pain">http://n.neurology.org/cgi/collection/all_pain</a> <b>All Spinal Cord</b> <a href="http://n.neurology.org/cgi/collection/all_spinal_cord">http://n.neurology.org/cgi/collection/all_spinal_cord</a>
<b>Permissions &amp; Licensing</b>	Information about reproducing this article in parts (figures, tables) or in its entirety can be found online at: <a href="http://www.neurology.org/about/about_the_journal#permissions">http://www.neurology.org/about/about_the_journal#permissions</a>
<b>Reprints</b>	Information about ordering reprints can be found online: <a href="http://n.neurology.org/subscribers/advertise">http://n.neurology.org/subscribers/advertise</a>

*Neurology*® is the official journal of the American Academy of Neurology. Published continuously since 1951, it is now a weekly with 48 issues per year. Copyright © 2019 American Academy of Neurology. All rights reserved. Print ISSN: 0028-3878. Online ISSN: 1526-632X.

