

Teaching NeuroImages: Imaging in metabolic leukoencephalopathy, L-2-hydroxyglutaric aciduria

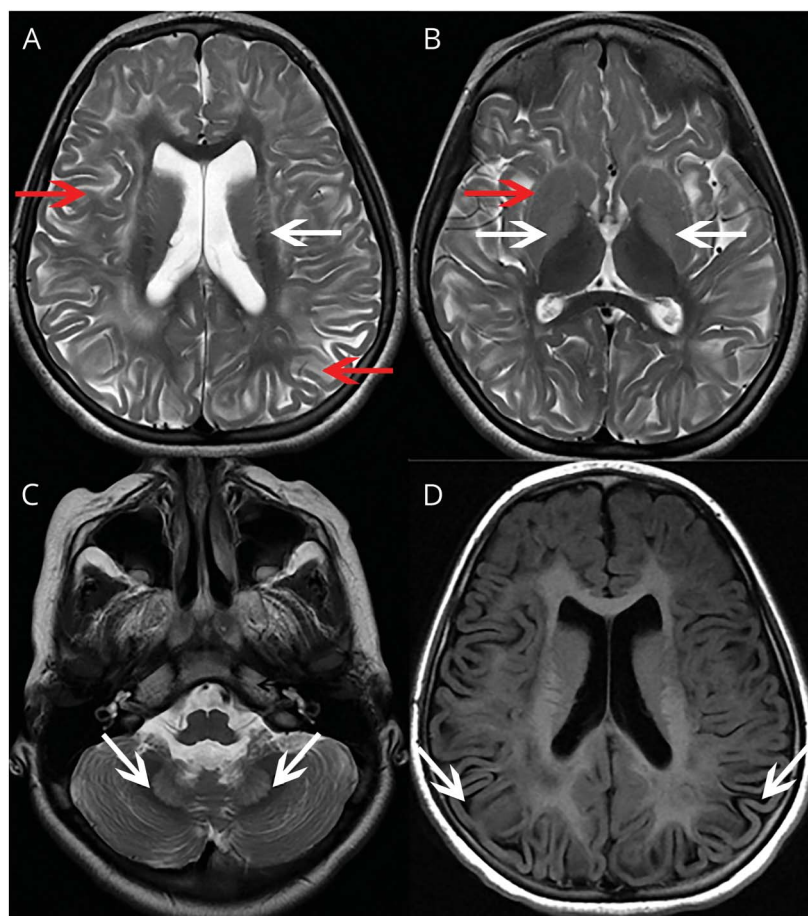
Sesh Sivadasan, MD, Vinayagamani S, MD, and Soumya Sundaram, MD, DM

Neurology® 2018;91:e1549-e1550. doi:10.1212/WNL.0000000000006362

Correspondence

Dr. Sivadasan
seshs2010@gmail.com

Figure Leukoencephalopathy with basal ganglia hyperintensity and outer rim sign of the putamen



Axial T2-weighted MRIs show (A) bilateral symmetrical white matter (WM) hyperintensity (red arrows) in the centripetal pattern involving subcortical and deep WM, with sparing of periventricular WM (white arrows). (B) Hyperintense basal ganglia (white arrows) with more hyperintensity along the outer rim of the putamen (outer rim sign, red arrow). (C) Hyperintense dentate nucleus (white arrows). (D) The fluid-attenuated inversion recovery image shows rarefaction (white arrows).

A 9-year-old girl presented to us with insidious onset difficulty in walking, recurrent falls, anxiety, and poor scholastic performance from age 5 years. Her MRI findings (figure) were classic of L-2-hydroxyglutaric aciduria (L2-HGA). However, similar findings are also seen in Leigh syndrome, 3-hydroxy-3-methylglutaric aciduria, and succinic semialdehyde dehydrogenase deficiency. Urine analysis showed elevated levels of L-2-hydroxyglutaric acid, which confirmed the diagnosis. L2-HGA is a rare autosomal recessive metabolic disorder due to deficiency of L-2-hydroxyglutarate dehydrogenase.¹ The characteristic MRI findings in this condition are

MORE ONLINE

→ Teaching slides

links.lww.com/WNL/A703

From the Department of Neurology (S. Sivadasan, S. Sundaram), and Department of Neuroimaging and Interventional Radiology (V.S.), Sree Chitra Institute of Medical Sciences and Technology, Thiruvananthapuram, India.

Go to Neurology.org/N for full disclosures. Funding information and disclosures deemed relevant by the authors, if any, are provided at the end of the article.

bilateral symmetrical basal ganglia and dentate nuclei involvement along with subcortical white matter abnormality.²

Author contributions

S. Sundaram: biochemical and clinical workup of the patient. V. S: reporting of MRI and differential diagnosis. S. Sivadasan: manuscript preparation and critical revision of the manuscript.

Acknowledgment

The authors thank Sajith R, Technical Assistant (Imaging Sciences and Intervention Radiology), who helped in obtaining high-quality MRIs.

Study funding

No targeted funding reported.

Disclosure

The authors report no disclosures relevant to the manuscript. Go to Neurology.org/N for full disclosures.

References

1. Kranendijk M, Struys EA, Salomons GS, Van der Knaap MS, Jakobs C. Progress in understanding 2-hydroxyglutaric acidurias. *J Inherit Metab Dis* 2012;35:571–587.
2. Steenweg ME, Salomons GS, Yapici Z, et al. L-2-hydroxyglutaric aciduria: pattern of MR imaging abnormalities in 56 patients. *Radiology* 2009;251:856–865.

Neurology®

Teaching NeuroImages: Imaging in metabolic leukoencephalopathy, L-2-hydroxyglutaric aciduria

Sesh Sivadasan, Vinayagamani S and Soumya Sundaram

Neurology 2018;91:e1549-e1550

DOI 10.1212/WNL.0000000000006362

This information is current as of October 15, 2018

Updated Information & Services	including high resolution figures, can be found at: http://n.neurology.org/content/91/16/e1549.full
References	This article cites 2 articles, 0 of which you can access for free at: http://n.neurology.org/content/91/16/e1549.full#ref-list-1
Subspecialty Collections	This article, along with others on similar topics, appears in the following collection(s): Basal ganglia http://n.neurology.org/cgi/collection/basal_ganglia Gait disorders/ataxia http://n.neurology.org/cgi/collection/gait_disorders_ataxia Leukodystrophies http://n.neurology.org/cgi/collection/leukodystrophies Organic acid http://n.neurology.org/cgi/collection/organic_acid
Permissions & Licensing	Information about reproducing this article in parts (figures, tables) or in its entirety can be found online at: http://www.neurology.org/about/about_the_journal#permissions
Reprints	Information about ordering reprints can be found online: http://n.neurology.org/subscribers/advertise

Neurology® is the official journal of the American Academy of Neurology. Published continuously since 1951, it is now a weekly with 48 issues per year. Copyright © 2018 American Academy of Neurology. All rights reserved. Print ISSN: 0028-3878. Online ISSN: 1526-632X.

