

# Teaching NeuroImages: Distinct brain microhemorrhage pattern in critical illness associated with respiratory failure

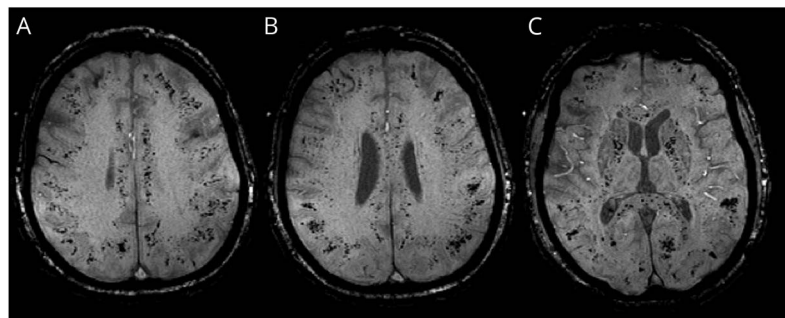
Julianne P. Hall, BA, Priyanka Minhas, MD, Marinos Kontzialis, MD, and Miral D. Jhaveri, MD

*Neurology*® 2018;90:e2011. doi:10.1212/WNL.0000000000005609

## Correspondence

Julianne P. Hall  
julianne\_p\_hall@rush.edu

**Figure** MRI of the brain shows distinct microhemorrhage pattern in critical illness associated with respiratory failure



(A–C) Axial susceptibility-weighted imaging MRI shows extensive punctate microhemorrhages involving the subcortical white matter, corpus callosum, and internal capsules.

A 51-year-old man with dementia presented with altered mental status and unremarkable initial brain CT and MRI. Hospitalization was complicated by aspiration pneumonia, hypoxia, and acute respiratory distress syndrome requiring intubation. He improved with antibiotics, but 1 week later developed seizures. MRI revealed new multiple microhemorrhages involving the subcortical white matter, internal capsules, and corpus callosum, sparing the deep white matter and deep gray nuclei (figure). This distinctive pattern is seen in critically ill patients with respiratory failure<sup>1</sup> and resembles high altitude exposure.<sup>2</sup> It is important to distinguish this from other causes of microhemorrhages including hypertension, diffuse axonal injury, and amyloid angiopathy.

## MORE ONLINE

→ **Teaching slides**  
[links.lww.com/WNL/A485](https://links.lww.com/WNL/A485)

## Author contributions

J.P. Hall: acquisition and interpretation of data, crafting of manuscript. Dr. Minhas: study concept and design, acquisition of data, critical revision of manuscript for intellectual content. Dr. Kontzialis: study concept and design, critical revision of manuscript for intellectual content. Dr. Jhaveri: study concept and design, acquisition and interpretation of data, critical revision of manuscript for intellectual content, study supervision.

## Study funding

No targeted funding reported.

## Disclosure

The authors report no disclosures relevant to the manuscript. Go to [Neurology.org/N](https://Neurology.org/N) for full disclosures.

## References

1. Fanou EM, Coutinho JM, Shannon P, et al. Critical illness-associated cerebral microbleeds. *Stroke* 2017;48:1085–1087.
2. Riech S, Kallenberg K, Moerer O, et al. The pattern of brain microhemorrhages after severe lung failure resembles the one seen in high-altitude cerebral edema. *Crit Care Med* 2015;43:e386–e389.

From Rush Medical College (J.P.H.), Rush University; and Department of Radiology (P.M., M.K., M.D.J.), Rush University Medical Center, Chicago, IL.

# Neurology®

## Teaching NeuroImages: Distinct brain microhemorrhage pattern in critical illness associated with respiratory failure

Julianne P. Hall, Priyanka Minhas, Marinos Kontzialis, et al.

*Neurology* 2018;90:e2011

DOI 10.1212/WNL.0000000000005609

**This information is current as of May 28, 2018**

<b>Updated Information &amp; Services</b>	including high resolution figures, can be found at: <a href="http://n.neurology.org/content/90/22/e2011.full">http://n.neurology.org/content/90/22/e2011.full</a>
<b>References</b>	This article cites 2 articles, 1 of which you can access for free at: <a href="http://n.neurology.org/content/90/22/e2011.full#ref-list-1">http://n.neurology.org/content/90/22/e2011.full#ref-list-1</a>
<b>Subspecialty Collections</b>	This article, along with others on similar topics, appears in the following collection(s): <b>All Education</b> <a href="http://n.neurology.org/cgi/collection/all_education">http://n.neurology.org/cgi/collection/all_education</a> <b>Critical care</b> <a href="http://n.neurology.org/cgi/collection/critical_care">http://n.neurology.org/cgi/collection/critical_care</a> <b>Intracerebral hemorrhage</b> <a href="http://n.neurology.org/cgi/collection/intracerebral_hemorrhage">http://n.neurology.org/cgi/collection/intracerebral_hemorrhage</a> <b>MRI</b> <a href="http://n.neurology.org/cgi/collection/mri">http://n.neurology.org/cgi/collection/mri</a>
<b>Permissions &amp; Licensing</b>	Information about reproducing this article in parts (figures, tables) or in its entirety can be found online at: <a href="http://www.neurology.org/about/about_the_journal#permissions">http://www.neurology.org/about/about_the_journal#permissions</a>
<b>Reprints</b>	Information about ordering reprints can be found online: <a href="http://n.neurology.org/subscribers/advertise">http://n.neurology.org/subscribers/advertise</a>

*Neurology*® is the official journal of the American Academy of Neurology. Published continuously since 1951, it is now a weekly with 48 issues per year. Copyright © 2018 American Academy of Neurology. All rights reserved. Print ISSN: 0028-3878. Online ISSN: 1526-632X.

