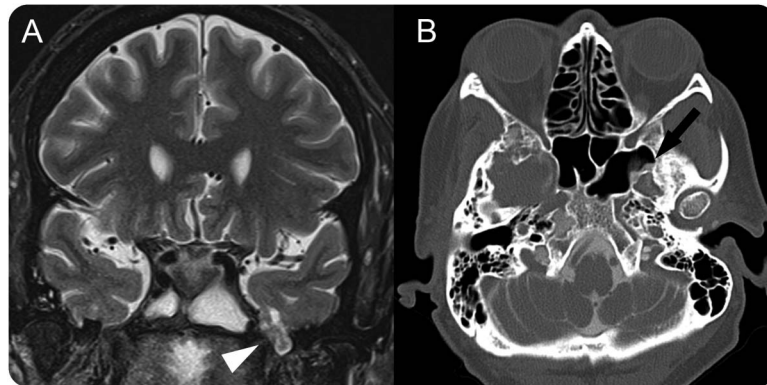


Teaching NeuroImages: Meningoencephalocele and CSF leak in chronic idiopathic intracranial hypertension

Donald McCorquodale,
MD, PhD
Tina M. Burton, MD
Blair Winegar, MD
Stefan M. Pulst, MD,
DrMed

Correspondence to
Dr. McCorquodale:
donald.mccorquodale@hsc.utah.
edu

Figure MRI and CT cisternogram



(A) Coronal T2 MRI shows bilateral meningoencephaloceles with herniating of temporal lobe and surrounding CSF on the left (arrowhead). (B) CT cisternogram shows intrathecal contrast extending through a punctate osseous defect in the lateral aspect of the left sphenoid sinus consistent with site of CSF leak (arrow).

A 63-year-old woman with epilepsy and chronic headaches was admitted for status epilepticus. A lumbar puncture revealed increased opening pressure of 320 mm H₂O and bacterial meningitis. MRI brain demonstrated a partial empty sella, tortuous optic nerve sheaths, flattening of the optic papillae, and numerous prominent arachnoid granulations, consistent with chronic idiopathic intracranial hypertension (IIH), as well as bright CSF signal and brain parenchyma within a left meningoencephalocele (figure, A). A CT cisternogram confirmed communication of the subarachnoid space of the meningoencephalocele with the left sphenoid sinus through a small osseous defect (figure, B). While most CSF leaks are related to trauma, IIH is increasingly recognized as a cause of spontaneous leaks.^{1,2} While the increased opening pressure may have been due to her acute meningitis, her headache symptoms and MRI findings are suggestive of longstanding intracranial hypertension. Monitoring and medical treatment of

IIH must accompany surgical repair to avoid recurrence.²

AUTHOR CONTRIBUTIONS

Donald McCorquodale: clinical evaluation, image review and formatting. Tina M. Burton: clinical evaluation, chart review, image review and formatting. Blair Winegar: diagnostic imaging, imaging interpretation, critical revision of manuscript. Stefan Pulst: clinical evaluation and critical revision of manuscript.

STUDY FUNDING

No targeted funding reported.

DISCLOSURE

The authors report no disclosures relevant to the manuscript. Go to Neurology.org for full disclosures.

REFERENCES

1. Lloyd KM, DelGaudio JM, Hudgins PA. Imaging of skull base cerebrospinal fluid leaks in adults. *Radiology* 2008; 248:725–736.
2. Pérez MA, Bialer OY, Bruce BB, Newman NJ, Biousse V. Primary spontaneous cerebrospinal fluid leaks and idiopathic intracranial hypertension. *J Neuroophthalmol* 2013;33:330–337.

Neurology®

Teaching *NeuroImages*: Meningoencephalocele and CSF leak in chronic idiopathic intracranial hypertension

Donald McCorquodale, Tina M. Burton, Blair Winegar, et al.

Neurology 2016;87:e244

DOI 10.1212/WNL.0000000000003330

This information is current as of November 14, 2016

Updated Information & Services	including high resolution figures, can be found at: http://n.neurology.org/content/87/20/e244.full
Supplementary Material	Supplementary material can be found at: http://n.neurology.org/content/suppl/2016/11/14/WNL.0000000000003330.DC1
References	This article cites 2 articles, 0 of which you can access for free at: http://n.neurology.org/content/87/20/e244.full#ref-list-1
Subspecialty Collections	This article, along with others on similar topics, appears in the following collection(s): CT http://n.neurology.org/cgi/collection/ct Idiopathic intracranial hypertension http://n.neurology.org/cgi/collection/idiopathic_intracranial_hypertension MRI http://n.neurology.org/cgi/collection/mri
Permissions & Licensing	Information about reproducing this article in parts (figures, tables) or in its entirety can be found online at: http://www.neurology.org/about/about_the_journal#permissions
Reprints	Information about ordering reprints can be found online: http://n.neurology.org/subscribers/advertise

Neurology® is the official journal of the American Academy of Neurology. Published continuously since 1951, it is now a weekly with 48 issues per year. Copyright © 2016 American Academy of Neurology. All rights reserved. Print ISSN: 0028-3878. Online ISSN: 1526-632X.

