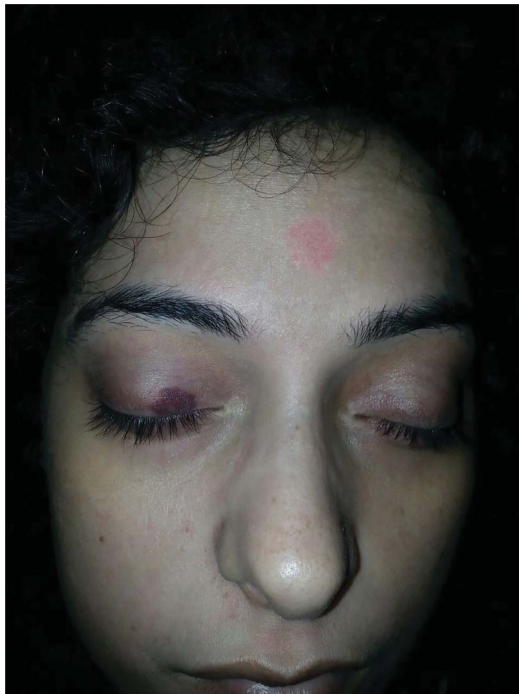

# Teaching NeuroImages: Red forehead dot syndrome and migraine revisited

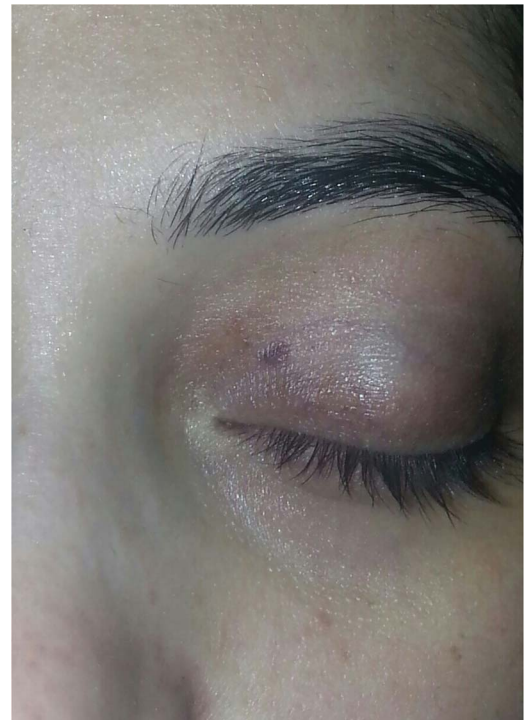
Prahlad K. Sethi, MD,  
MBBS  
Nitin K. Sethi, MD,  
MBBS  
Josh Torgovnick, MD

Correspondence to  
Dr. Nitin Sethi:  
sethinitinmd@hotmail.com

**Figure 1** Photograph of the patient shows red forehead dot sign



**Figure 2** Photograph of the patient shows eye lid ecchymosis and redness of skin in the V1 distribution of the trigeminal nerve



A 32-year-old woman with episodic headaches presented with 1.5 months of continuous left frontotemporal headache, pain, and dragging sensation in the left eye. Red forehead dot was noted along with eyelid ecchymosis (figures 1 and 2). Family history of migraine was reported in the patient's father and grandmother. Neurologic examination and brain MRI, magnetic resonance angiography, and magnetic resonance venography had normal results and workup revealed no evidence for vasculitis. Activation of the trigeminovascular system leading to release of vasoactive peptides is the likely cause of the red forehead dot and eyelid ecchymosis seen in some migraine patients.<sup>1</sup>

## AUTHOR CONTRIBUTIONS

P.K.S. examined the patient and helped revise the manuscript. N.K.S. drafted/revise the manuscript. J.T. revised the manuscript.

## STUDY FUNDING

No targeted funding reported.

## DISCLOSURE

The authors report no disclosures relevant to the manuscript. Go to [Neurology.org](http://Neurology.org) for full disclosures.

## REFERENCE

1. Sethi PK, Sethi NK, Torgovnick J. Red forehead dot syndrome and migraine. *J Headache Pain* 2007;8: 135–136.

# Neurology®

## Teaching *NeuroImages*: Red forehead dot syndrome and migraine revisited

Prahlad K. Sethi, Nitin K. Sethi and Josh Torgovnick

*Neurology* 2015;85:e28

DOI 10.1212/WNL.0000000000001762

**This information is current as of July 20, 2015**

<b>Updated Information &amp; Services</b>	including high resolution figures, can be found at: <a href="http://n.neurology.org/content/85/3/e28.full">http://n.neurology.org/content/85/3/e28.full</a>
<b>Supplementary Material</b>	Supplementary material can be found at: <a href="http://n.neurology.org/content/suppl/2015/07/17/WNL.0000000000001762.DC1">http://n.neurology.org/content/suppl/2015/07/17/WNL.0000000000001762.DC1</a>
<b>References</b>	This article cites 1 articles, 0 of which you can access for free at: <a href="http://n.neurology.org/content/85/3/e28.full#ref-list-1">http://n.neurology.org/content/85/3/e28.full#ref-list-1</a>
<b>Citations</b>	This article has been cited by 1 HighWire-hosted articles: <a href="http://n.neurology.org/content/85/3/e28.full##otherarticles">http://n.neurology.org/content/85/3/e28.full##otherarticles</a>
<b>Subspecialty Collections</b>	This article, along with others on similar topics, appears in the following collection(s): <b>All Headache</b> <a href="http://n.neurology.org/cgi/collection/all_headache">http://n.neurology.org/cgi/collection/all_headache</a> <b>Migraine</b> <a href="http://n.neurology.org/cgi/collection/migraine">http://n.neurology.org/cgi/collection/migraine</a>
<b>Permissions &amp; Licensing</b>	Information about reproducing this article in parts (figures, tables) or in its entirety can be found online at: <a href="http://www.neurology.org/about/about_the_journal#permissions">http://www.neurology.org/about/about_the_journal#permissions</a>
<b>Reprints</b>	Information about ordering reprints can be found online: <a href="http://n.neurology.org/subscribers/advertise">http://n.neurology.org/subscribers/advertise</a>

*Neurology*® is the official journal of the American Academy of Neurology. Published continuously since 1951, it is now a weekly with 48 issues per year. Copyright © 2015 American Academy of Neurology. All rights reserved. Print ISSN: 0028-3878. Online ISSN: 1526-632X.

