

Pearls & Oysters: Hemicrania epileptica

Unfolding the mystery of an unremitting migraine

Zubeda Sheikh, MBBS,
MD
Hlynur Georgsson, MD
David Marks, MD

Correspondence to
Dr. Sheikh:
sheikhzb@njms.rutgers.edu

A 38-year-old woman presented with a right-sided throbbing headache associated with visual symptoms, nausea, vomiting, photophobia, and phonophobia. She had experienced migraines since her teenage years characterized by monthly unilateral headache associated with nausea and photophobia. The current headache had started with symptoms she recognized as her regular monthly migraine, but it had uncharacteristically persisted for 3 days. She also described a persistent aura of “pixelated 3-dimensional objects” and “colored pinwheels,” which she had not experienced with her previous headaches. Two days into the headache, she had developed a defect in her left visual field and had narrowly missed hitting a tree on that side while driving. At the time of presentation to us, she had already undergone a head CT, which was reported normal, and she was prescribed prednisone, sumatriptan, and oxycodone for management of status migrainosus, without benefit.

Our initial evaluation found an obese woman wearing dark glasses due to photophobia. The neurologic examination revealed visual acuity of 20/25 bilaterally, no papilledema, left homonymous hemianopsia, and a horizontal nystagmus with a fast component to the left. Laboratory workup was significant for anemia, ketonuria secondary to vomiting and dehydration, and positive antinuclear antibody (1:80) with speckled pattern. The remainder of her rheumatologic workup was normal.

A brain MRI showed thickened cortex in the right occipital lobe on T2 fluid-attenuated inversion recovery (FLAIR) (figure, A) as well as hyperintense signal on diffusion-weighted imaging (DWI) (figure, B) with subtle corresponding apparent diffusion coefficient hypointensity, isolated to the same cortex. Isolated cortical involvement with sparing of the white matter suggested that the findings were unlikely to be due to arterial ischemic infarction. Her visual symptoms worsened, and she variously described them as a “kaleidoscope-like effect,” with “yellow visual fields” and “right side of my brother’s body is melting away.” Her persistent complex visual symptoms with colored 3-dimensional figures and distortions (metamorphopsia) were more typical for visual hallucinations of occipital epilepsy rather than migrainous aura. EEG was

obtained and she was found to be in partial status epilepticus with an ictal focus in the right occipital and parietal cortices (figure, C). She was treated with lorazepam and loaded with levetiracetam with significant improvement in the headache over the next 24 hours. Topiramate was added to the regimen as a dual agent for seizure and migraine prophylaxis. She was discharged home headache-free but with a mild residual hemianopsia. This fully resolved at 3-month follow-up, and a repeat MRI showed complete resolution of the previously noted findings. Levetiracetam was withdrawn at follow-up and she was maintained on topiramate monotherapy.

The final diagnosis was partial status epilepticus from the right occipitoparietal cortex with ictal hemianopsia and hemicrania epileptica. It is debatable whether the seizure was precipitated by migraine, constituting migrainopsia, or her migraines were always an epileptic phenomenon. Topiramate was chosen for prophylaxis because it is a dual agent against both epilepsy and migraine.

PEARLS Hemicrania epileptica (HE) is recognized as an ipsilateral headache phenomenon (in the *International Classification of Headache Disorders [ICHD]* classification) with migrainous features but occurring as an ictal manifestation of focal epileptic seizures.¹

Diagnostic criteria²:

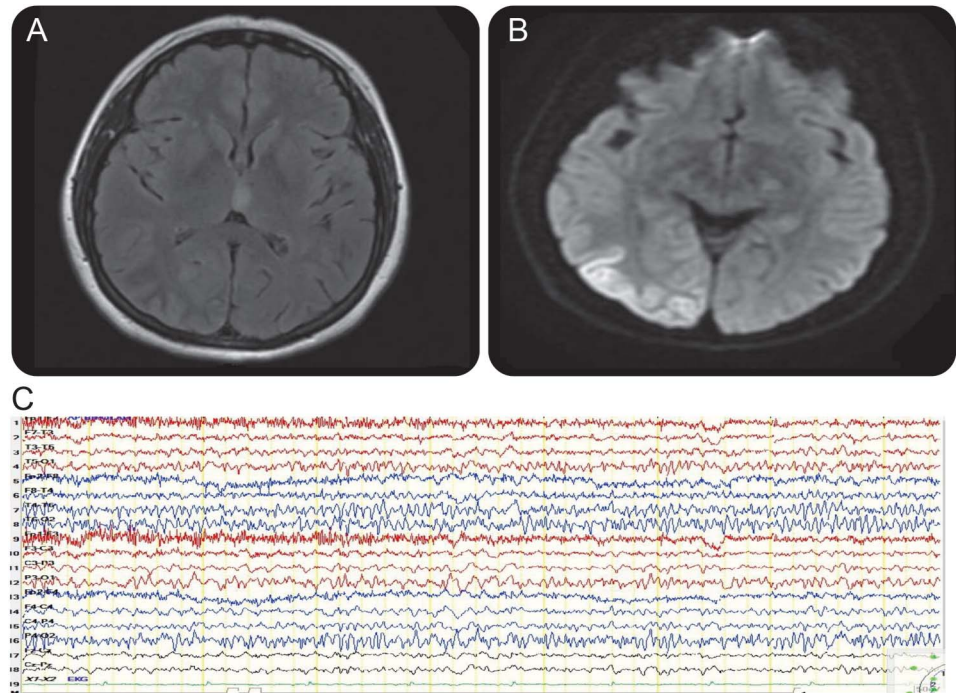
- A. Any headache, fulfilling criterion C.
- B. Patient experiencing a partial epileptic seizure.
- C. Evidence of causation demonstrated by both of the following:
 1. Headache has developed simultaneously with onset of a partial seizure.
 2. Either or both of the following:
 - a. Headache has significantly improved immediately after the partial seizure has terminated.
 - b. Headache is ipsilateral to ictal discharge.
- D. Not better accounted for by another *ICHD-3* diagnosis.

Parisi et al. identified 5 potential HE cases in the literature from 1988. In these cases, migraine

From the Department of Neurology, Rutgers–New Jersey Medical School, Newark.

Go to Neurology.org for full disclosures. Funding information and disclosures deemed relevant by the authors, if any, are provided at the end of the article.

Figure Right occipital seizure on EEG and resultant changes on MRI



T2 fluid-attenuated inversion recovery showing thickening of cortex in right occipital lobe (A), restricted diffusion in right occipital cortex (B), and EEG showing seizure from right occipital and parietal cortices (C).

appeared to be the sole manifestation of nonconvulsive status epilepticus; 4 patients showed partial status in occipital lobes in the EEG.¹ None of these patients met the *ICHD-2* diagnostic criteria for HE. Seizure-induced neuroimaging changes were not described in these cases. Our patient had a persistent headache with migrainous features ipsilateral to the side of ictal activity that improved after appropriate antiepileptics were started and was not better accounted for by any other *ICHD-3* diagnosis; therefore, this classifies as hemicrania epileptica. Our patient's headache was prolonged as she was in focal status and she also had neuroimaging changes secondary to focal status epilepticus.

OY-STERS The typical migrainous visual aura starts in the central visual field described as flickering, uncolored, zigzag lines, then moving toward the periphery leaving a scotoma. The aura usually lasts more than 4 minutes and less than 30 minutes. Visual hallucinations secondary to occipital seizures are more complex, mainly colored and circular in nature, occurring in the periphery of the temporal contralateral visual field, becoming larger and moving horizontally toward the ipsilateral visual field. Complex visual hallucinations with distorted imagery can occur when the visual association areas are involved. These ictal visual symptoms are shorter in duration, lasting 30 seconds to 3 minutes.³⁻⁵

EEG should be considered in all patients with headache who exhibit both positive and negative

visual symptoms and the positive visual symptoms have the complex characteristics described above for ictal visual symptoms.

Evidence of cortical edema or thickening on FLAIR and restricted diffusion on DWI limited to the cortex with sparing of white matter may be attributed to ongoing focal seizures and is one of the described transient peri-ictal MRI abnormalities.⁶

AUTHOR CONTRIBUTIONS

Dr. Sheikh designed, drafted, and revised the manuscript and created the figure. Dr. Georgsson revised and edited the manuscript. Dr. Marks edited the manuscript for intellectual content and approved all final changes.

STUDY FUNDING

No targeted funding reported.

DISCLOSURE

The authors report no disclosures relevant to the manuscript. Go to Neurology.org for full disclosures.

REFERENCES

1. Belcastro V, Striano P, Kasteleijn-Nolst Trenité DG, Villa MP, Parisi P. Migraine, hemicrania epileptica, post-ictal headache and "ictal epileptic headache": a proposal for terminology and classification revision. *J Headache Pain* 2011;12:289-294.
2. Headache Classification Committee of the International Headache Society (IHS). The International Classification of Headache Disorders, 3rd edition. *Cephalalgia* 2013;33:629-808.

3. Panayiotopoulos CP, Sharoqi IA, Agathonikou A. Occipital seizures imitating migraine aura. *J R Soc Med* 1997;90:255–257.
4. Panayiotopoulos CP. Visual aura of migraine versus visual occipital lobe seizures. *Cephalalgia* 2012;32:654.
5. Panayiotopoulos CP. Visual phenomena and headache in occipital epilepsy: a review, a systematic study and differentiation from migraine. *Epileptic Disord* 1999;1:205–216.
6. Kim JA, Chung JI, Yoon PH, et al. Transient MR signal changes in patients with generalized tonicoclonic seizure or status epilepticus: periictal diffusion-weighted imaging. *AJNR Am J Neuroradiol* 2001;22:1149–1160.

Neurology®

Pearls & Oy-sters: Hemicrania epileptica: Unfolding the mystery of an unremitting migraine

Zubeda Sheikh, Hlynur Georgsson and David Marks

Neurology 2015;85:e190-e192

DOI 10.1212/WNL.0000000000002215

This information is current as of December 14, 2015

Updated Information & Services	including high resolution figures, can be found at: http://n.neurology.org/content/85/24/e190.full
References	This article cites 6 articles, 0 of which you can access for free at: http://n.neurology.org/content/85/24/e190.full#ref-list-1
Citations	This article has been cited by 1 HighWire-hosted articles: http://n.neurology.org/content/85/24/e190.full##otherarticles
Subspecialty Collections	This article, along with others on similar topics, appears in the following collection(s): EEG; see Epilepsy/Seizures http://n.neurology.org/cgi/collection/eeg_see_epilepsy-seizures Migraine http://n.neurology.org/cgi/collection/migraine MRI http://n.neurology.org/cgi/collection/mri Partial seizures http://n.neurology.org/cgi/collection/partial_seizures Status epilepticus http://n.neurology.org/cgi/collection/status_epilepticus
Permissions & Licensing	Information about reproducing this article in parts (figures, tables) or in its entirety can be found online at: http://www.neurology.org/about/about_the_journal#permissions
Reprints	Information about ordering reprints can be found online: http://n.neurology.org/subscribers/advertise

Neurology® is the official journal of the American Academy of Neurology. Published continuously since 1951, it is now a weekly with 48 issues per year. Copyright © 2015 American Academy of Neurology. All rights reserved. Print ISSN: 0028-3878. Online ISSN: 1526-632X.

