

ADCY5 mutations are another cause of benign hereditary chorea



Niccolo E. Mencacci, MD*
Roberto Erro, MD*
Sarah Wiethoff, MD
Joshua Hersheson, MRCP
Mina Ryten, MRCP, PhD
Bettina Balint, MD
Christos Ganos, MD
Maria Stamelou, MD, PhD
Niall Quinn, MD, FRCP
Henry Houlden, PhD, FRCP
Nicholas W. Wood, PhD, FRCP, FMedSci
Kailash P. Bhatia, MD, FRCP

Correspondence to
Dr. Erro:
r.erro@ucl.ac.uk

ABSTRACT

Objective: To determine the contribution of *ADCY5* mutations in cases with genetically undefined benign hereditary chorea (BHC).

Methods: We studied 18 unrelated cases with BHC (7 familial, 11 sporadic) who were negative for *NKX2-1* mutations. The diagnosis of BHC was based on the presence of a childhood-onset movement disorder, predominantly characterized by chorea and no other major neurologic features. *ADCY5* analysis was performed by whole-exome sequencing or Sanger sequencing. *ADCY5* and *NKX2-1* expression during brain development and in the adult human brain was assessed using microarray analysis of postmortem brain tissue.

Results: The c.1252C>T; p.R418W mutation was identified in 2 cases (1 familial, 1 sporadic). The familial case inherited the mutation from the affected father, who had a much milder presentation, likely due to low-grade somatic mosaicism. The mutation was de novo in the sporadic case. The clinical presentation of these cases featured nonparoxysmal generalized chorea, as well as dystonia in the most severely affected, but no facial myokymia. We observed significant progression of symptoms in *ADCY5* mutation carriers, in contrast to BHC secondary to *NKX2-1* mutations. The difference in the clinical course is mirrored by the brain expression data, showing increasing *ADCY5* expression in the striatum during brain development, whereas *NKX2-1* shows an opposite trend.

Conclusions: Our study identifies mutations in *ADCY5*, the gene previously linked to familial dyskinesia with facial myokymia, as a cause of familial and sporadic BHC. *ADCY5* genetic analysis should be performed in cases with a benign choreiform movement disorder even in the absence of facial myokymia. **Neurology® 2015;85:80-88**

GLOSSARY

ADCY5 = adenylate cyclase 5 gene; **BHC** = benign hereditary chorea; **DFDM** = familial dyskinesia with facial myokymia; **mRNA** = messenger RNA; **OMIM** = Online Mendelian Inheritance in Man; **WES** = whole-exome sequencing.

Benign hereditary chorea (BHC) (OMIM 118700) is a rare and poorly delineated syndrome, clinically characterized by onset of symptoms in infancy or early childhood, relatively little clinical progression, and absence of other major neurologic deficits, in particular prominent cognitive decline.^{1,2}

Mutations in the *NKX2-1* gene (OMIM 600635) were identified in 2002 as a major cause of familial and sporadic BHC.^{3,4} However, a number of families with BHC do not carry mutations in *NKX2-1*, suggesting that other genes may be responsible for this syndrome.⁵⁻⁸

Familial dyskinesia with facial myokymia (DFDM) (OMIM 606703) was first described by Fernandez et al.⁹ in 2001. They reported a 5-generation kindred with 18 members affected with an autosomal dominant movement disorder, mainly characterized by childhood or early adolescent onset of hyperkinetic movements and perioral and periorbital myokymia. The disease locus was

Supplemental data
at Neurology.org

*These authors contributed equally to this work.

From the Department of Molecular Neuroscience (N.E.M., S.W., J.H., M.R., H.H., N.W.W.) and Sobell Department of Motor Neuroscience and Movement Disorders (R.E., B.B., C.G., M.S., N.Q., K.P.B.), UCL Institute of Neurology, London, UK; IRCCS Istituto Auxologico Italiano (N.E.M.), Department of Neurology and Laboratory of Neuroscience—Department of Pathophysiology and Transplantation, “Dino Ferrari” Centre, Università degli Studi di Milano; Dipartimento di Scienze Neurologiche e del Movimento (R.E.), Università di Verona, Italy; Department of Neurology (B.B.), University Hospital Heidelberg; Department of Neurology (C.G.), University Medical Centre Hamburg-Eppendorf, Hamburg, Germany; Neurology Clinic (M.S.), Attiko Hospital, University of Athens; and Movement Disorders Department (M.S.), Hygeia Hospital, Athens, Greece.

Go to Neurology.org for full disclosures. Funding information and disclosures deemed relevant by the authors, if any, are provided at the end of the article.

subsequently mapped to chromosome 3p21-3q21,¹⁰ and recently a missense variant in the adenylate cyclase 5 gene (*ADCY5*; OMIM 600293) was identified by next-generation sequencing as the causative mutation.¹¹

Of note, before the identification of facial myokymia as one of the core features, individuals from the original FDFM kindred had been described as affected with familial essential (“benign”) chorea.¹² Given the phenotypic overlap between FDFM and BHC, we wondered whether *ADCY5* mutations could be detected in cases clinically diagnosed with BHC but lacking mutations in *NKX2-1*. We therefore performed a comprehensive mutational analysis of *ADCY5* in a cohort of *NKX2-1*–negative cases with a BHC phenotype.

METHODS **Standard protocol approvals, registrations, and patient consents.** The study was approved by the UCL ethics committee (UCLH project 06/N076), and written informed consent was obtained from all participants.

Patients. All cases included in this study were evaluated in the Movement Disorder Center of the National Hospital for Neurology and Neurosurgery, Queen Square, London.

We studied 18 consecutive unrelated cases, including 7 with an autosomal dominant family history and 11 sporadic. All participants in the study were assessed by neurologists with significant expertise in movement disorders (N.Q. and K.P.B.). BHC was clinically diagnosed based on the presence of a movement disorder, with onset before the age of 20 years, predominantly characterized by chorea in the absence of other major neurologic features (i.e., cognitive decline, ataxia, spasticity, or peripheral neuropathy). Medical history was negative for toxin exposure and drugs known to cause chorea.

Basic diagnostic evaluations, including MRI of the brain, CSF analysis, acanthocytes, antistreptolysin titer, copper, ceruloplasmin, and α -fetoprotein, were unremarkable. All cases were negative for mutations in the *NKX2-1* gene and the Huntington disease triplet repeat expansion. DRPLA, SCA17, and HDL2 expansions were excluded in familial cases. *SGCE* mutations were excluded when myoclonus-dystonia was suspected due to the presence of dystonic features.

Genetic analysis. After informed consent was given, DNA was extracted from peripheral lymphocytes following a standard protocol. DNA of patients was analyzed either by whole-exome sequencing (WES) or by direct Sanger sequencing of the 21 coding exons and flanking intronic regions of *ADCY5* (RefSeq accession number NM_183357). WES and Sanger sequencing methods are detailed in the supplementary methods (appendix e-1 on the *Neurology*[®] Web site at Neurology.org). Variants identified by WES were confirmed by Sanger sequencing. Segregation analysis was performed in parents and other relatives in mutation-positive cases.

Expression profiling of *ADCY5* and *NKX2-1* in brain tissue. Regional distribution of *ADCY5* and *NKX2-1* messenger RNA (mRNA) expression in the normal adult human brain was determined using microarray analysis of human postmortem brain tissue from the UK Human Brain Expression Consortium

as previously described.¹³ This dataset is based on exon array profiling of 1,231 samples from 10 brain areas originating from 134 control individuals. *ADCY5* and *NKX2-1* mRNA expression changes during the course of human brain development were assessed by accessing the data available through the Human Brain Transcriptome database.^{14,15}

RESULTS **Identification of *ADCY5* mutations.** Analysis by WES or Sanger sequencing of the *ADCY5* coding sequence revealed 4 different heterozygous mutations.

The pathogenic c.1252C>T; p.R418W variant was identified in 2 unrelated cases. This amino acid change has been previously reported in association with FDFM,¹⁶ is absent in all publicly available datasets of population controls (dbSNP, 1000 Genomes project, NHLBI exome variant server and Exome Aggregation Consortium), and is consistently predicted pathogenic by in silico prediction tools (PolyPhen-2, SIFT, and MutationTaster).

Another novel missense variant (c.2117C>T; p.A706V) was identified in the index case of a pedigree with autosomal dominant BHC. The mutation was predicted benign and tolerated respectively by PolyPhen-2 and SIFT, but disease-causing by MutationTaster. Segregation analysis in the family showed that the mutation was absent in the affected mother and had been inherited from the unaffected father, ruling out any pathogenic relevance.

Finally, a variant in the 5′ untranslated region (c.1-5G>C) together with the missense variant c.29C>T; p.P10L (rs143905423) was detected in a sporadic case of African ancestry (unknown phase of the 2 mutations). Both variants are reported with a minor allele frequency $\geq 1\%$ in control individuals of African ancestry as reported by the Exome Aggregation Consortium, suggesting that both variants are likely to be neutral.

Clinical presentations of cases with pathogenic *ADCY5* mutations. Clinical information of the patients with pathogenic *ADCY5* mutations identified in this study and of those previously reported in the literature is summarized in the table.

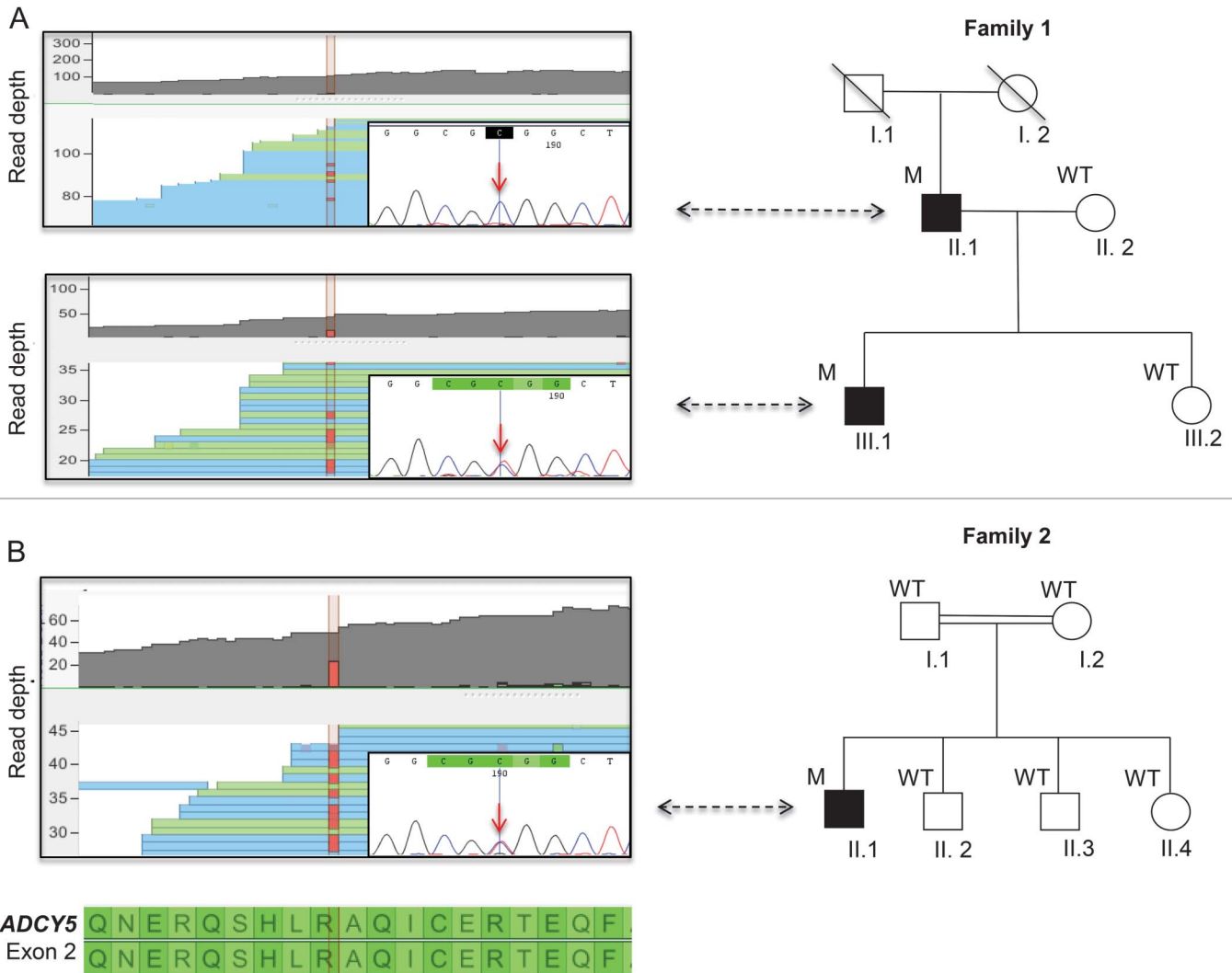
Family 1. The clinical description of this pedigree has been previously reported.¹⁷ The index case is a 36-year-old British man (subject III-1; figure 1A). His birth and early development throughout infancy were normal. Around age 1, he progressively developed brief choreic movements at rest, affecting the face and the 4 limbs (video 1, segment 1A). Movements were markedly exacerbated by excitement, stress, or tiredness. Around the age of 18, he also developed painful spasms of the 4 limbs, particularly frequent and severe upon awakening. Symptoms progressed over the years and clinical examination at the age of 28 (video 1, segment 1B) revealed dysarthric speech and severe abnormal involuntary movements comprising generalized chorea with facial

Table Clinical features of cases with pathogenic ADCY5 mutations described in this study and reported in the literature

| | This study | | | Literature | | | | |
|---|--|--|--|---|---|---------------------------|--|-----------------------------|
| | Family 1/subject II-1 | Family 1/subject III-1 | Family 2/subject II-1 | Original FDFM pedigree ⁹ | Subject ID1 ¹⁶ | Subject UW1 ¹⁶ | Subject II-1 ²⁰ | Subject III-1 ²⁰ |
| Ethnic origin | UK-Caucasian | UK-Caucasian | UK-Pakistani | US-Caucasian | US-Caucasian | US-Caucasian | France | France |
| Age at onset | 1 y | 1 y | 2 y | Early childhood to late adolescence | 2 y | 5 y | 6 mo | 4 y |
| Age at examination, y | 64 | 36 | 22 | Range 7-52 | 15 | 18 | 39 | 15 |
| Mutation | c.1252C>T; p.R418W (low-level mosaicism) | c.1252C>T; p.R418W | c.1252C>T; p.R418W | c.2176G>A; p.A726T | c.1252C>T; p.R418W | c.1252C>T; p.R418W | c.2088+1G>A; p? | c.2088+1G>A; p? |
| Symptoms at onset | Chorea | Chorea | Chorea and lower limb dystonia | Paroxysmal chorea | Hypotonia and paroxysmal chorea | Chorea | Chorea and lower limb dystonia | Falls while walking |
| Developmental milestones | Normal | Normal | Delayed | Normal | Delayed | Normal | Normal | Normal |
| Dysarthria | No | Yes | Yes | No | Yes | No | No | No |
| Facial dyskinesias | Few facial twitches | Chorea | Chorea | Chorea, eyelid and perioral twitches in some members | Perioral and periorbital dyskinesias | Few facial twitches | Chorea | Chorea |
| EMG | No myokymia | No myokymia | NA | Proven myokymia only in some members | NA | NA | NA | NA |
| Chorea | Yes, mild | Yes, severe and worsened by action and anxiety | Yes, severe and worsened by action and anxiety | Yes, mild to moderate and worsened by stress | Paroxysmal chorea, worsened by anxiety | Yes | Yes, mild | Yes, moderate |
| Dystonia | No | Yes | Yes | Yes, only in some members | Yes | Yes | Yes | Yes |
| Other features | Gaze impersistence, difficulty initiating saccades | Gaze impersistence, difficulty initiating saccades | Gaze impersistence | Head tremor and epileptic seizures in some members | Intermittent tremors, myoclonic jerks, hyperreflexia and limb hypertonia | No | Enhanced tendon reflexes and bilateral extensor plantar reflexes | Hypotonia, pyramidal signs |
| Paroxysmal events | Ballistic episodes and spasms upon awakening | Ballistic episodes and spasms upon awakening | Ballistic episodes and spasms at night | Dyskinetic episodes triggered by anxiety/stress in some members | Myoclonic jerks and ballistic movements arising from sleep stages N2 and N3 | No | No | No |
| Gait | Mild difficulty on tandem walking | Abnormal due to lower limb choreo-dystonia | Abnormal due to lower limb choreo-dystonia | Normal | Severely affected with progressive deterioration | Normal | Unsteady gait | Normal |
| Extraneural involvement (cardiac, respiratory, or thyroid) | No | No | No | 5 subjects died of congestive heart failure at a relatively young age | No | No | No | No |

Abbreviations: FDFM = familial dyskinesia with facial myokymia; NA = not available.

Figure 1 Pedigree and genetic results of families 1 (A) and 2 (B) with *ADCY5* pathogenic mutations



Affected individuals in the pedigree are indicated by filled symbols. On the left is the visual output of the whole-exome sequencing data and Sanger sequencing results in the 3 affected individuals carrying the c.1252C>T; p.R418W mutation. In the top section of each box, the read depth of the exonic portion of *ADCY5* involved by the mutation is shown. In the bottom part of each box, samples of the reads carrying the mismatching allele are displayed. The mutant T replacing a C is highlighted in red. Sanger sequencing failed to show the mutation in individual II-1 of family 1. Of note, whole-exome sequencing showed that approximately 8% of reads (9/110) carried the mutated allele in individual II-1 of family 1, indicating parental low-level somatic mosaicism. M = mutated; WT = wild-type.

grimacing and marked dystonic elements. Both chorea and dystonia were present at rest, but action significantly exacerbated movements in the limbs. Eye movements were abnormal with gaze impersistence and use of head thrust to initiate saccades. Gait was unsteady with both choreic and dystonic features, but cerebellar testing was normal. He never displayed facial myokymia and EMG of periorbital and perioral regions failed to show either myokymia or other signs of motor neuron hyperexcitability. Over the years, different medications were tried without major improvements, including trihexyphenidyl, tetrabenazine, baclofen, levodopa, and clonazepam. He is currently on a combination of trihexyphenidyl (3 mg/d) and tetrabenazine (75 mg/d), which he finds helpful in reducing the intensity and frequency of the spasms.

His 64-year-old father (subject II-1; figure 1A) also developed involuntary movements in the first year of life. His involuntary movements mainly consisted of generalized chorea, with no dystonic posturing and overall he has always been much less affected than the son (video 1, segments 1A and 2).

Besides chorea, on examination, he had marked ocular and motor impersistence and tandem walking difficulties. Cerebellar testing was otherwise normal. At the last follow-up, when he was 61, occasional twitches were observed in the periorbital areas (video 1, segment 2), but an EMG performed on the same day did not show myokymia. A low dose of tetrabenazine was tried but was not tolerated because of the development of depression. He is currently taking trihexyphenidyl (7.5 mg/d), with satisfactory control of

the dyskinesias. Higher doses were not tolerated because of the occurrence of cognitive difficulties.

There was no history of movement disorders in other family members, including both paternal grandparents of the index case.

The heterozygous *ADCY5* c.1252C>T; p.R418W mutation was found by WES and confirmed by direct sequencing in subject III-1. No other possibly pathogenic variants in genes linked to chorea or other movement disorders were observed.

Sanger sequencing unexpectedly failed to detect the mutation in the affected father (figure 1A). Mosaicism has been previously reported in patients with mild presentation of mendelian disorders.¹⁸ We therefore suspected that Sanger sequencing might have missed the mutation in the father because of low-grade somatic mosaicism.

Because next-generation sequencing has been shown to be a more sensitive method to detect this type of mutation,^{18,19} WES was performed also in subject II-1.

Of note, this revealed the presence of the mutated allele in 9 of 110 sequence reads (approximately 8% vs 40% in his son; figure 1A), demonstrating the presence of low-level somatic mosaicism. This suggests that possibly the mutation arose in the father during early stages of embryogenesis. The unaffected mother and sister of the index case were wild-type by Sanger sequencing analysis.

Family 2. This is a 22-year-old man of Pakistani ethnicity (subject II-1; figure 1B). He is the son of a consanguineous marriage (parents are first-degree cousins) and he is the first of 4 siblings. He is the only affected member in the family. He had delayed motor milestones with walking at approximately 20 months. Since then, his gait has always been abnormal, being mainly characterized by arching of the trunk, walking on tiptoes, and inversion of both feet. Around the age of 2, he developed constant involuntary movements involving all 4 limbs and trunk, which became progressively more evident over the years. Movements were largely exacerbated by stress and anxiety. Around the age of 10, he developed “fits” of violent hyperkinetic movements and painful spasms of all 4 limbs, mainly occurring at night. A polysomnographic study performed to investigate their nature excluded any epileptic activity and showed that the attacks occurred when the patient was fully awake.

On examination (video 2), he had moderate generalized chorea at rest and intermittent distal dystonic posturing in the 4 limbs. The hyperkinetic movements were dramatically increased by action. Gait was unsteady, but cerebellar testing was otherwise normal. Cranial nerve examination showed ocular impersistence, and frequent facial choreic movements

were also observed. The patient declined an EMG of the facial muscles. He is currently taking trihexyphenidyl (30 mg/d) and tetrabenazine (50 mg/d), which partially reduced the intensity of the dyskinesias and the frequency of the spasms.

WES and subsequent Sanger sequencing analysis showed the presence in the affected case of the *ADCY5* c.1252C>T; p.R418W change in the heterozygous state (figure 1B). The mutation had likely occurred de novo, as Sanger sequencing showed its absence in both healthy parents and in the 3 unaffected siblings. Mutations in other genes associated with chorea or other movement disorders were excluded.

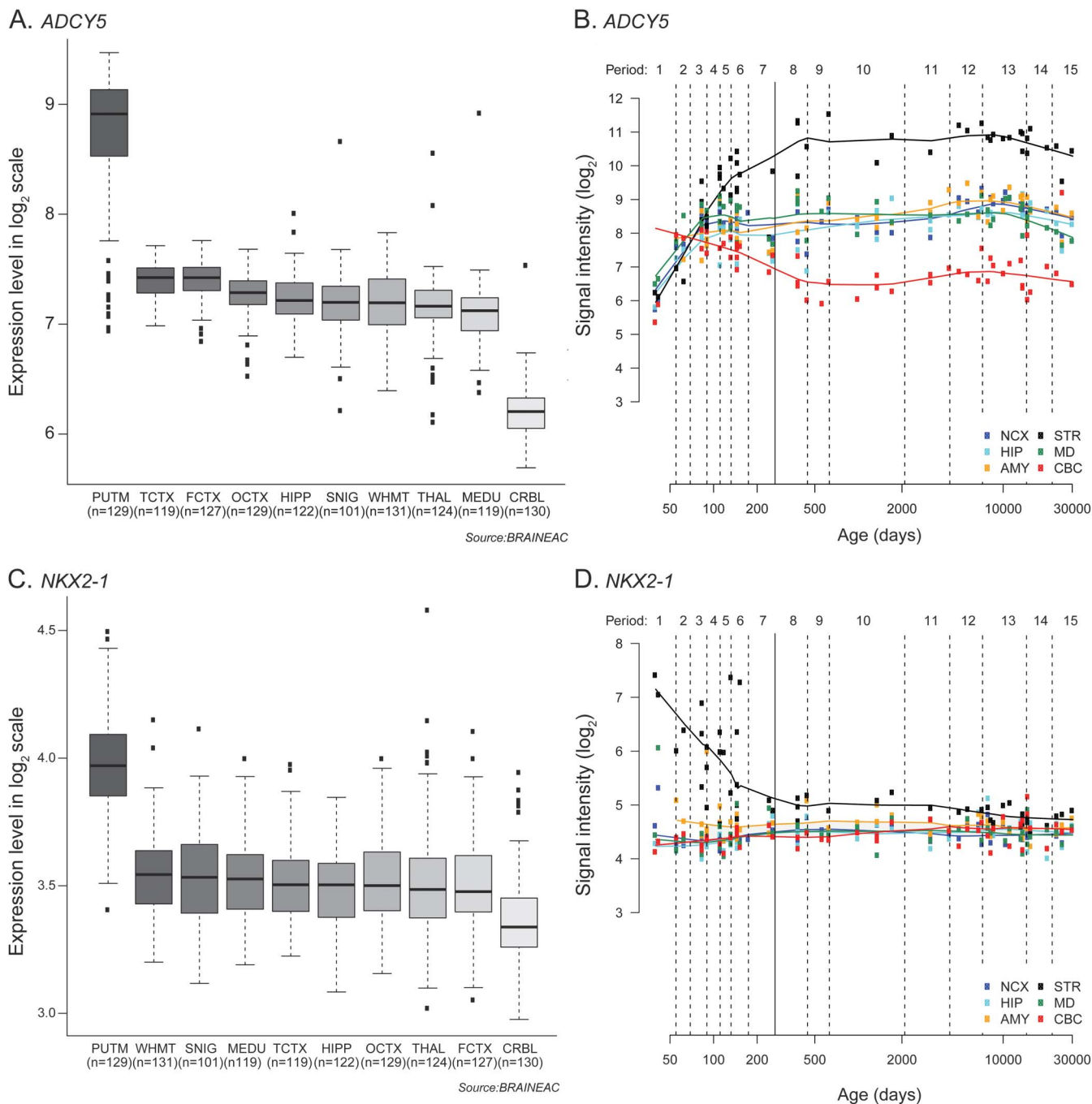
Brain expression data. To investigate the differences in the phenotype and clinical course between BHC due to *ADCY5* and *NKX2-1* mutations, we analyzed and compared expression of the 2 genes across multiple brain regions and during the course of development.

Consistent with the observed phenotype, mainly characterized by chorea and dystonia with preserved cognition and no other major neurologic features, both *ADCY5* and *NKX2-1* mRNA expression profiling in 10 brain regions showed the highest expression in the putamen relative to other brain regions (figure 2A). When comparing *ADCY5* with *NKX2-1* expression, we observed that *ADCY5* has a much higher expression in adult striatum. Furthermore, longitudinal analysis of mRNA expression during brain development showed opposite trends for *ADCY5* and *NKX2-1*, with *ADCY5* expression progressively increasing in the striatum from 50 to 500 days postconceptualization and *NKX2-1* progressively decreasing (figure 2D).

DISCUSSION Recently, a gain-of-function heterozygous missense mutation in *ADCY5* (c.2176G>A; p.A726T) was recognized as the genetic cause in the original FDFM pedigree.¹¹ The phenotype of the affected members of this family consisted of hyperkinetic movements starting from early childhood to late adolescence. A distinctive feature of this disorder was the presence of prominent periorbital and perioral facial myokymia.⁹

After the identification of *ADCY5* as the responsible gene in the original FDFM pedigree, the same group described a second pathogenic missense variant in *ADCY5* (c.1252C>T; p.R418W), which occurred de novo in 2 unrelated individuals with a sporadic complex hyperkinetic movement disorder.¹⁶ The phenotype of these cases shared some features with the original FDFM pedigree, but it was more severe and further encompassed delayed motor milestones, axial hypotonia, and progressive gait difficulties in one case. More recently, a splice-site mutation in *ADCY5* was identified in a family with autosomal dominant early-onset chorea, dystonia, and pyramidal signs.²⁰

Figure 2 Graphical summary of brain expression data



(A, B) Boxplots of *ADCY5* and *NKX2-1* messenger RNA (mRNA) expression levels in 10 adult brain regions. The expression levels are based on exon array experiments and are plotted on a \log_2 scale (y-axis). This plot shows significant variation in *ADCY5* and *NKX2-1* transcript expression across the 10 CNS regions analyzed: putamen (PUTM), frontal cortex (FCTX), temporal cortex (TCTX), occipital cortex (OCTX), hippocampus (HIPPI), substantia nigra (SNIG), medulla (specifically inferior olivary nucleus, MEDU), intralobular white matter (WHMT), thalamus (THAL), and cerebellar cortex (CRBL). *ADCY5* and *NKX2-1* mRNA expression is higher in the putamen than in all other brain regions and *ADCY5* expression in the putamen is significantly higher than *NKX2-1*. (C, D) Graphs to show *ADCY5* and *NKX2-1* longitudinal mRNA expression in 6 brain regions during the course of human brain development. The expression levels are based on exon array experiments and are plotted on a \log_2 scale (y-axis). The brain regions analyzed are the striatum (STR), amygdala (AMY), neocortex (NCX), hippocampus (HIP), mediodorsal nucleus of the thalamus (MD), and cerebellar cortex (CBC). The plots show increasing expression of *ADCY5* mRNA during human brain development, particularly in the striatum, from 50 to 500 days postconceptualization and an opposite trend for *NKX2-1*.

We report here the results of the *ADCY5* mutational analysis in a cohort of *NKX2-1*-negative sporadic and familial cases with a BHC-like presentation. These cases had previously been extensively

investigated for genetic and acquired causes of chorea, without reaching a conclusive diagnosis.

We identified 3 cases from 2 unrelated pedigrees bearing the same pathogenic change c.1252C>T;

p.R418W. The clinical phenotype of these cases predominantly featured generalized chorea, although with significant intra- and interfamilial phenotypic variability.

As previously observed in other cases with the *ADCY5* p.R418W mutation, 2 of the 3 subjects with the mutation (individual III-1 from family 1 and individual II-1 from family 2) presented with severe choreo-dystonic dyskinesias, which were significantly more disabling than those of individuals carrying the p.A726T mutation from the original FDFM pedigree.

Subject II-1 from family 1 had conversely a milder presentation, with little functional impact from the dyskinesias. Furthermore, he had isolated chorea and no dystonic features. Of note, this milder presentation was reflected by the WES data, showing in the latter case a significantly reduced number of reads carrying the mutated allele. This suggests low-level somatic mosaicism as the likely explanation for the mitigated phenotype.

In some of the previously described cases with *ADCY5* mutations, dyskinesias were reported as paroxysmal in the initial phase of the disease.^{9,16} Conversely, we show that dyskinesias were not paroxysmal, but constantly present from the onset of symptoms in the 3 cases we report, albeit markedly influenced by emotional states and action. It is of interest that all 3 cases developed episodes of violent ballistic movements and spasms later during the disease course. The episodes were particularly frequent at night or upon awakening. Similar episodes were also reported by Chen et al.¹⁶ in individual ID1 (carrier of the p.R418W mutation), suggesting that this may be a specific feature of the *ADCY5*-related movement disorder.

Facial myokymia has been suggested to be a distinctive feature of *ADCY5*-related disorder. However, an EMG study of the facial muscles performed in both affected subjects from family 1 (both presenting facial involuntary movements) did not show myokymia or other signs of motor neuron hyperexcitability. Although the subject from family 2 refused to undergo EMG, his facial hyperkinesias were clinically deemed to be choreiform in nature (video 2). This indicates that patients with *ADCY5* mutations may present facial choreiform movements in the absence of myokymia. Consistent with this, facial myokymia was neither described in affected members from the original FDFM kindred nor recognized as a prominent feature in the other *ADCY5* mutation carriers who were subsequently reported (table).

Even though the clinical presentation of patients with *ADCY5* mutations is consistent with the clinical definition of BHC, some clinical clues may help to recognize and differentiate *ADCY5* mutation carriers from BHC cases due to mutations in *NKX2-1*.

First, although both conditions can have extraneural involvement, *NKX2-1* carriers often present with pulmonary symptoms or evidence of endocrine defects,²¹ whereas cardiac heart failure has been observed in some affected individuals from the original FDFM pedigree.¹¹ *ADCY5* overexpression has also been shown to lead to cardiomyopathy in a mouse model.²²

Second, the clinical progression between the 2 disorders seems to be different. BHC cases secondary to *NKX2-1* mutations tend to remain relatively mildly affected and often improve after childhood,²¹ while we show here that *ADCY5* mutation carriers may present significant progression of symptoms, at least until adult age. This difference in the clinical progression is nicely mirrored by the brain transcriptome data. The analysis and comparison of *ADCY5* and *NKX2-1* mRNA regional brain expression showed that, although both genes are most highly expressed in the adult striatum, *ADCY5* levels progressively increase during brain development whereas *NKX2-1* levels show an opposite trend.

Third, prominent dystonic posturing is present in the most severely affected cases with *ADCY5* mutations and may dominate the clinical picture as the disease progresses (video 1, section 1B). Mild dystonic features can also be observed in some *NKX2-1* cases,^{23,24} but they are generally not as severe as we observed in *ADCY5* mutation carriers. Lastly, *ADCY5*-related dyskinesias are dramatically worsened by action, excitement, or stress. This feature likely reflects the biological role of adenylyl cyclase 5. This enzyme catalyzes the formation of cAMP (cyclic adenosine monophosphate) upon β -adrenergic receptor stimulation via G proteins in striatal cells, and pathogenic mutations seem to increase the cyclase activity.¹⁶

Our study demonstrates that *ADCY5* mutations are responsible for familial and sporadic BHC and further delineates the phenotype associated with *ADCY5* mutations. A diagnosis of *ADCY5*-related disorder should be suspected when evaluating patients with a BHC-like presentation, regardless of the presence of facial myokymia. Differences in the clinical presentation may be attributed to distinct molecular effects of different mutations, although somatic mosaicism may explain intrafamilial phenotypic variability, as shown in family 1. We also suggest that the term FDMD should not be used to refer to *ADCY5*-related movement disorder because myokymia may often not be part of the phenotype.

Given the possible reported association of *ADCY5* mutations with cardiac involvement, it will be fundamental to closely follow up *ADCY5* mutation carriers in order to prevent or adequately treat potential cardiac complications.

We confirm the usefulness of WES in the molecular diagnosis of rare and genetically heterogeneous

movement disorders, such as BHC. WES should be considered in the diagnostic workup of BHC after the exclusion of acquired causes in sporadic cases and mutations in the genes most frequently associated with choreic syndromes.²⁵ In particular, repeat expansions (e.g., Huntington disease, SCA17 [spinocerebellar ataxia 17], DRPLA [dentatorubral-pallidoluysian atrophy]) should be ruled out before performing WES because these mutations are not easily detected with this technology.

AUTHOR CONTRIBUTIONS

Niccolo E. Mencacci: drafting the manuscript for content, including medical writing for content, study concept and design, analysis and interpretation of data, acquisition of data. Roberto Erro: drafting the manuscript for content, including medical writing for content, study concept and design, analysis and interpretation of data, acquisition of data. Sarah Wiethoff: revising the manuscript for content, including medical writing for content, analysis and interpretation of data, acquisition of data. Joshua Hershenson: revising the manuscript for content, including medical writing for content, analysis and interpretation of data, acquisition of data. Mina Ryten: revising the manuscript for content, including medical writing for content, analysis and interpretation of data. Bettina Balint: revising the manuscript for content, including medical writing for content, interpretation of data. Christos Ganos: revising the manuscript for content, including medical writing for content, interpretation of data. Maria Stamelou: revising the manuscript for content, including medical writing for content, interpretation of data. Niall Quinn: revising the manuscript for content, including medical writing for content, analysis and interpretation of data, acquisition of data. Henry Houlden: revising the manuscript for content, including medical writing for content, supervision. Nicholas W. Wood: revising the manuscript for content, including medical writing for content, supervision. Kailash P. Bhatia: revising the manuscript for content, including medical writing for content, study concept, interpretation of data, acquisition of data, supervision.

STUDY FUNDING

This project was supported by the National Institute for Health Research University College London Hospitals Biomedical Research Centre. This study was also supported by the Wellcome Trust/Medical Research Council Joint Call in Neurodegeneration award (WT089698) to the Parkinson's Disease Consortium (UKPDC), whose members are from the UCL Institute of Neurology, University of Sheffield, and the Medical Research Council Protein Phosphorylation Unit at the University of Dundee.

DISCLOSURE

N. Mencacci is funded by an MRC-Wellcome Trust grant. R. Erro has been partly supported by COST Action BM1101 (reference: ECOST-STSM-BM1101-160913-035934) and has received travel grants by Ipsen. S. Wiethoff, J. Hershenson, M. Ryten, and B. Balint report no disclosures relevant to the manuscript. C. Ganos receives academic research support from Deutsche Forschungsgemeinschaft (MU1692/2-1 and GA 2031/1-1) and European Science Foundation; commercial research support: travel grants by Actelion, Ipsen, Pharm Allergan, and Merz Pharmaceuticals. M. Stamelou, N. Quinn, H. Houlden, and N. Wood report no disclosures relevant to the manuscript. K. Bhatia receives royalties from publication of Oxford Specialist Handbook of *Parkinson's Disease and Other Movement Disorders* (Oxford University Press, 2008) and of *Marsden's Book of Movement Disorders* (Oxford University Press, 2012). He received funding for travel from GlaxoSmithKline, Orion Corporation, Ipsen, and Merz Pharmaceuticals. Go to Neurology.org for full disclosures.

ONLINE RESOURCES

1000 Genomes project: www.1000genomes.org
dbSNP: www.ncbi.nlm.nih.gov/projects/SNP
Exome Aggregation Consortium: <http://exac.broadinstitute.org>
Human Brain Transcriptome: <http://hbatlas.org/>

MutationTaster: <http://www.mutationtaster.org/>
NHLBI Exome Variant Server EVS: evs.gs.washington.edu
PolyPhen-2: <http://genetics.bwh.harvard.edu/pph2/>
SIFT: <http://sift.jcvi.org/>
UK Human Brain Expression Consortium: <http://www.braineac.org/>

Received December 8, 2014. Accepted in final form March 9, 2015.

REFERENCES

1. Kleiner-Fisman G, Lang AE. Benign hereditary chorea revisited: a journey to understanding. *Mov Disord* 2007; 22:2297–2305.
2. Schrag A, Quinn NP, Bhatia KP, Marsden CD. Benign hereditary chorea: entity or syndrome? *Mov Disord* 2000; 15:280–288.
3. Breedveld GJ, van Dongen JW, Danesino C, et al. Mutations in TITF-1 are associated with benign hereditary chorea. *Hum Mol Genet* 2002;11:971–979.
4. Gras D, Jonard L, Roze E, et al. Benign hereditary chorea: phenotype, prognosis, therapeutic outcome and long term follow-up in a large series with new mutations in the TITF1/NKX2-1 gene. *J Neurol Neurosurg Psychiatry* 2012;83:956–962.
5. Breedveld GJ, Percy AK, MacDonald ME, et al. Clinical and genetic heterogeneity in benign hereditary chorea. *Neurology* 2002;59:579–584.
6. Bauer P, Kreuz FR, Burk K, et al. Mutations in TITF1 are not relevant to sporadic and familial chorea of unknown cause. *Mov Disord* 2006;21:1734–1737.
7. Shimohata T, Hara K, Sanpei K, et al. Novel locus for benign hereditary chorea with adult onset maps to chromosome 8q21.3 q23.3. *Brain* 2007;130:2302–2309.
8. Thorwarth A, Schnittert-Hubener S, Schrupf P, et al. Comprehensive genotyping and clinical characterisation reveal 27 novel NKX2-1 mutations and expand the phenotypic spectrum. *J Med Genet* 2014;51:375–387.
9. Fernandez M, Raskind W, Wolff J, et al. Familial dyskinesia and facial myokymia (FDFM): a novel movement disorder. *Ann Neurol* 2001;49:486–492.
10. Raskind WH, Matsushita M, Peter B, et al. Familial dyskinesia and facial myokymia (FDFM): follow-up of a large family and linkage to chromosome 3p21-3q21. *Am J Med Genet B Neuropsychiatr Genet* 2009;150B:570–574.
11. Chen YZ, Matsushita MM, Robertson P, et al. Autosomal dominant familial dyskinesia and facial myokymia: single exome sequencing identifies a mutation in adenylyl cyclase 5. *Arch Neurol* 2012;69:630–635.
12. Bird TD, Carlson CB, Hall JG. Familial essential (“benign”) chorea. *J Med Genet* 1976;13:357–362.
13. Trabzuni D, Ryten M, Walker R, et al. Quality control parameters on a large dataset of regionally dissected human control brains for whole genome expression studies. *J Neurochem* 2011;119:275–282.
14. Johnson MB, Kawasawa YI, Mason CE, et al. Functional and evolutionary insights into human brain development through global transcriptome analysis. *Neuron* 2009;62: 494–509.
15. Kang HJ, Kawasawa YI, Cheng F, et al. Spatio-temporal transcriptome of the human brain. *Nature* 2011;478:483–489.
16. Chen YZ, Friedman JR, Chen DH, et al. Gain-of-function ADCY5 mutations in familial dyskinesia with facial myokymia. *Ann Neurol* 2014;75:542–549.
17. Sleigh G, Lindenbaum RH. Benign (non-paroxysmal) familial chorea: paediatric perspectives. *Arch Dis Child* 1981;56: 616–621.

18. Beicht S, Strobl-Wildemann G, Rath S, et al. Next generation sequencing as a useful tool in the diagnostics of mosaicism in Alport syndrome. *Gene* 2013;526:474–477.
19. Miyatake S, Koshimizu E, Hayashi YK, et al. Deep sequencing detects very-low-grade somatic mosaicism in the unaffected mother of siblings with nemaline myopathy. *Neuromuscul Disord* 2014;24:642–647.
20. Carapito R, Paul N, Untrau M, et al. A de novo ADCY5 mutation causes early-onset autosomal dominant chorea and dystonia. *Mov Disord* 2015;30:423–427.
21. Inzelberg R, Weinberger M, Gak E. Benign hereditary chorea: an update. *Parkinsonism Relat Disord* 2011;17:301–307.
22. Ho D, Yan L, Iwatsubo K, Vatner DE, Vatner SF. Modulation of beta-adrenergic receptor signaling in heart failure and longevity: targeting adenylyl cyclase type 5. *Heart Fail Rev* 2010;15:495–512.
23. Armstrong MJ, Shah BB, Chen R, Angel MJ, Lang AE. Expanding the phenomenology of benign hereditary chorea: evolution from chorea to myoclonus and dystonia. *Mov Disord* 2011;26:2296–2297.
24. Peall KJ, Lumsden D, Kneen R, et al. Benign hereditary chorea related to NKX2.1: expansion of the genotypic and phenotypic spectrum. *Dev Med Child Neurol* 2014;56:642–648.
25. Wild EJ, Tabrizi SJ. The differential diagnosis of chorea. *Pract Neurol* 2007;7:360–373.

Save These Dates for AAN CME Opportunities!

Mark these dates on your calendar for exciting continuing education conferences by the American Academy of Neurology. Learn more at AAN.com/conferences.

2015 Sports Concussion Conference

- July 24–26, 2015, Denver, Colorado, Colorado Convention Center

AAN Fall Conference

- October 16–18, 2015, Las Vegas, NV, The Cosmopolitan of Las Vegas

AAN Annual Meeting

- April 15–21, 2016, Vancouver, BC, Canada, Vancouver Convention Centre

Introducing Stackly

Organize. Disseminate. Collaborate. Discover.



With simple tools for collecting, organizing, and sharing research materials, Stackly is the new center of your research world.

- Share what you find and discover what others share
- Collaborate with colleagues on topics that matter to you most

Stackly will integrate with your web browser and work directly with all Neurology® Journals as well as other publication sites. Access Stackly on the home page and to the right of each article. Visit <http://www.neurology.org/site/includefiles/homepage/stackly.xhtml> to learn more and start stacking for FREE.

Neurology[®]

ADCY5 mutations are another cause of benign hereditary chorea

Niccolo E. Mencacci, Roberto Erro, Sarah Wiethoff, et al.

Neurology 2015;85;80-88 Published Online before print June 17, 2015

DOI 10.1212/WNL.0000000000001720

This information is current as of June 17, 2015

| | |
|---|--|
| Updated Information & Services | including high resolution figures, can be found at: http://n.neurology.org/content/85/1/80.full |
| Supplementary Material | Supplementary material can be found at: http://n.neurology.org/content/suppl/2015/06/17/WNL.000000000001720.DC1 http://n.neurology.org/content/suppl/2015/07/03/WNL.000000000001720.DC2 |
| References | This article cites 25 articles, 6 of which you can access for free at: http://n.neurology.org/content/85/1/80.full#ref-list-1 |
| Citations | This article has been cited by 4 HighWire-hosted articles: http://n.neurology.org/content/85/1/80.full##otherarticles |
| Subspecialty Collections | This article, along with others on similar topics, appears in the following collection(s): All Genetics http://n.neurology.org/cgi/collection/all_genetics Chorea http://n.neurology.org/cgi/collection/chorea Dystonia http://n.neurology.org/cgi/collection/dystonia |
| Permissions & Licensing | Information about reproducing this article in parts (figures, tables) or in its entirety can be found online at: http://www.neurology.org/about/about_the_journal#permissions |
| Reprints | Information about ordering reprints can be found online: http://n.neurology.org/subscribers/advertise |

Neurology® is the official journal of the American Academy of Neurology. Published continuously since 1951, it is now a weekly with 48 issues per year. Copyright © 2015 American Academy of Neurology. All rights reserved. Print ISSN: 0028-3878. Online ISSN: 1526-632X.

