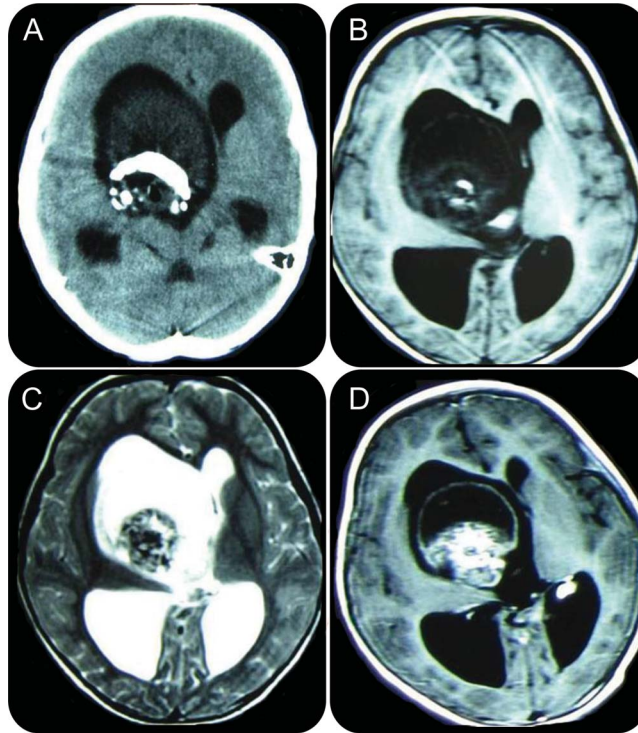


Mystery Case: Giant mature teratoma of the lateral ventricle in a child

Jin Li, MD
ZhiGang Lan, MD
JianGuo Xu, MD

Correspondence to
Dr. Xu:
hxswjim@163.com

Figure 1 Brain CT and MRI



Axial CT scan shows a mass lesion with heterogeneous density and huge calcification in the right lateral ventricle (A). Cranial MRI, T1-weighted axial (B) and T2-weighted axial (C), shows a mass lesion with low and high signal intensity. Contrast-enhanced images show heterogeneous enhancement of the lesion (D).

A 3-year-old girl was admitted with a 1-month history of headache. Neurologic examination was normal. Cranial CT revealed a mass with huge calcification in the right lateral ventricle (figure 1A). MRI demonstrated a lesion with low and high signal intensity and heterogeneous enhancement (figure 1, B–D). A right frontal craniotomy was performed. The right ventricle was found to be filled with sebaceous glands, hair, fat globules, a full set of teeth, tongue, and gastrointestinal glands (figure 2, A–D). Histologic examination confirmed a mature teratoma. Postoperative MRI demonstrated total tumor resection (figure 2, E and F). A mature teratoma located in the lateral ventricle with a full set of teeth is extremely rare.^{1,2}

AUTHOR CONTRIBUTIONS

Dr. Li: data collection, drafting of manuscript. Dr. Lan: data collection, review of literature. Dr. Xu: revision of manuscript, concept of manuscript.

STUDY FUNDING

No targeted funding reported.

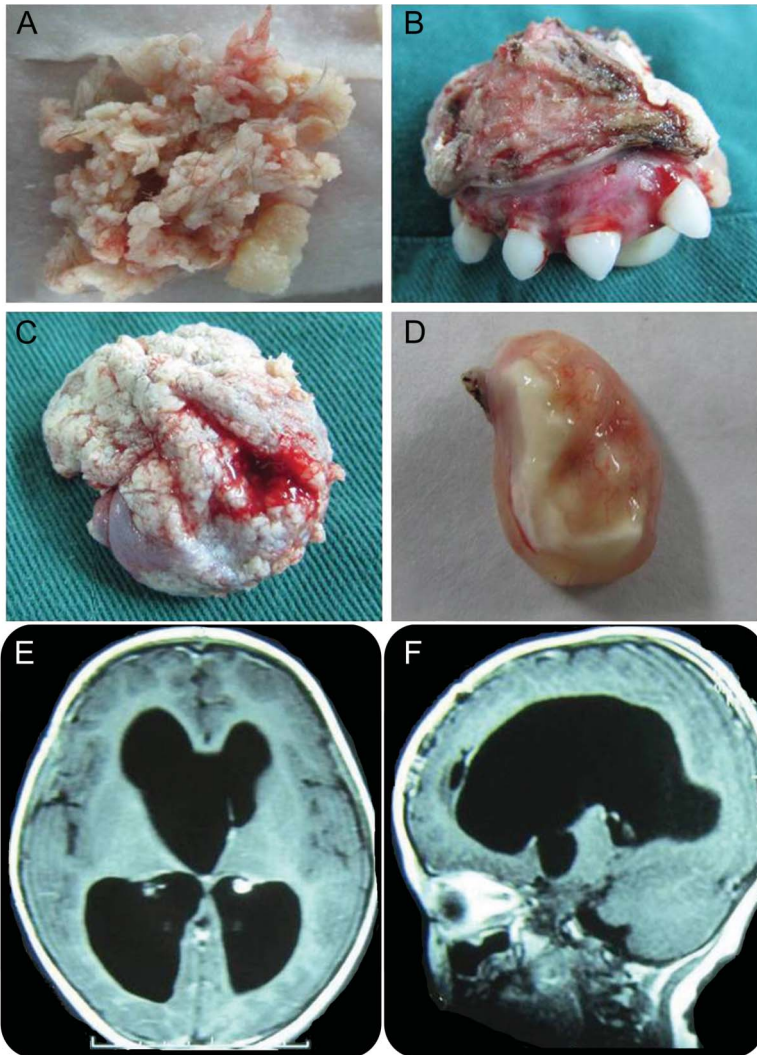
DISCLOSURE

The authors report no disclosures relevant to the manuscript. Go to Neurology.org for full disclosures.

REFERENCES

- Selçuki M, Attar A, Yüceer N, Tuna H, Cakiroğlu E. Mature teratoma of the lateral ventricle: report of two cases. *Acta Neurochir* 1998;140:171–174.

Figure 2 Intraoperative findings and postoperative brain MRI



The resected samples show the sebaceous glands and hair (A), a full set of teeth (B), tongue (C), and gastrointestinal glands (D). Postoperative MRI, contrast axial (E) and sagittal (F) images, shows total tumor resection.

2. Lai PH, Hsu SS, Lo YS, Ho JT. Mature teratoma of the lateral ventricle in adulthood: preoperative CT and MRI diagnosis. *Neurology* 2006;66:E25–E26.

MYSTERY CASE RESPONSES

The Mystery Case series was initiated by the *Neurology*[®] Resident & Fellow Section to develop the clinical reasoning skills of trainees. Residency programs, medical student preceptors, and individuals were invited to use this Mystery Case as an educational tool. Responses were solicited through a group e-mail sent to the American Academy of Neurology Consortium of Neurology Residents and Fellows and through social media.

All the responses we received came from individuals rather than groups. A total of 33% of respondents correctly identified the lesion as a teratoma. The most complete response came from Violet M. Aroon, who pointed out that the heterogeneous lesion likely contains fat and soft tissue based on its signal characteristics on T1 and T2 MRI.

This case highlights the value of MRI in characterizing intraventricular mass lesions, which may be essential in guiding subsequent clinical management.

Andrew Schepmyer, MD
University of British Columbia, Vancouver, Canada

Neurology®

Mystery Case: Giant mature teratoma of the lateral ventricle in a child

Jin Li, ZhiGang Lan and JianGuo Xu

Neurology 2014;83:e60-e61

DOI 10.1212/WNL.0000000000000637

This information is current as of July 28, 2014

Updated Information & Services	including high resolution figures, can be found at: http://n.neurology.org/content/83/5/e60.full
References	This article cites 2 articles, 1 of which you can access for free at: http://n.neurology.org/content/83/5/e60.full#ref-list-1
Subspecialty Collections	This article, along with others on similar topics, appears in the following collection(s): All Pediatric http://n.neurology.org/cgi/collection/all_pediatric CT http://n.neurology.org/cgi/collection/ct MRI http://n.neurology.org/cgi/collection/mri Primary brain tumor http://n.neurology.org/cgi/collection/primary_brain_tumor Surgical therapy-tumor http://n.neurology.org/cgi/collection/surgical_therapytumor
Permissions & Licensing	Information about reproducing this article in parts (figures, tables) or in its entirety can be found online at: http://www.neurology.org/about/about_the_journal#permissions
Reprints	Information about ordering reprints can be found online: http://n.neurology.org/subscribers/advertise

Neurology® is the official journal of the American Academy of Neurology. Published continuously since 1951, it is now a weekly with 48 issues per year. Copyright © 2014 American Academy of Neurology. All rights reserved. Print ISSN: 0028-3878. Online ISSN: 1526-632X.

