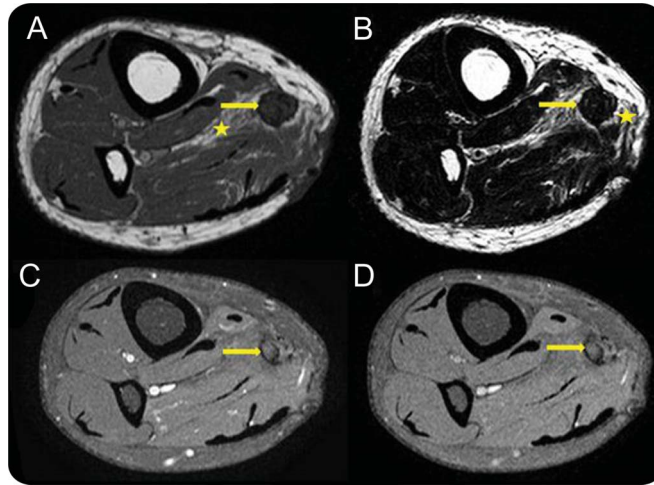


# Teaching NeuroImages: Posttraumatic neuroma-in-continuity of the right tibial nerve

Sathya Narayanan, MBBS  
Radha Sarawagi, MD

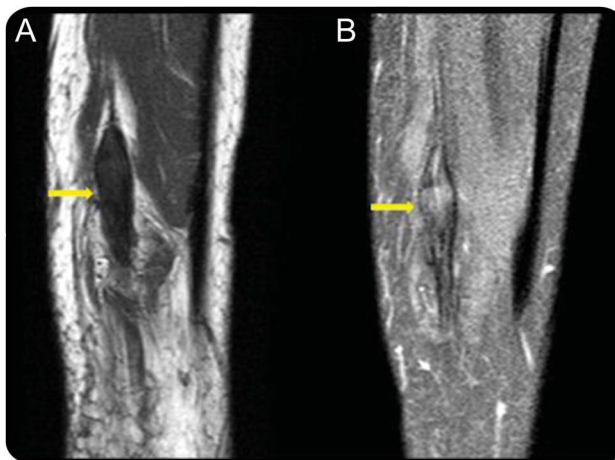
Correspondence to  
Dr. Narayanan:  
sathyadr88@gmail.com

**Figure 1** MRI right leg



Axial T1-weighted (A) and T2-weighted (B) MRI of the right leg show thickened tibial nerve (arrow) isointense to muscles with perineural scarring (asterisk). Axial T1-weighted fat suppressed pregadolinium (C) and postgadolinium contrast images (D) reveal no significant enhancement of the lesion.

**Figure 2** MRI right leg



Sagittal T1-weighted precontrast without fat suppression (A) and T1-weighted postcontrast fat-suppressed (B) MRI show fusiform thickening of the tibial nerve with nerve continuity on either side without significant enhancement of the lesion.

A 40-year-old man with a history of penetrating injury to the right lower leg complained of shooting pain along the distribution of the tibial nerve and the small nodule beneath the cutaneous scar. MRI demonstrated

nonenhancing fusiform thickening of the tibial nerve, which was isointense to muscle with perineural scarring (figures 1 and 2). The features were characteristic of posttraumatic neuroma-in-continuity.

Download teaching  
slides: [Neurology.org](http://Neurology.org)

From the Department of Radiology, Mahatma Gandhi Medical College and Research Institute, Pondicherry, India.

Go to [Neurology.org](http://Neurology.org) for full disclosures. Funding information and disclosures deemed relevant by the authors, if any, are provided at the end of the article.

Posttraumatic neuromas are divided into neuroma-in-continuity and end-bulb neuroma. Neuroma-in-continuity is fusiform thickening of nerve due to injury or chronic friction of intact nerve. End-bulb neuroma occurs in completely transected nerve, which is not in apposition with distal nerve.<sup>1</sup>

Perineural fibrosis, T2 hypointensity, and absence of contrast enhancement (figure 2) differentiate neuroma-in-continuity from nerve sheath tumors.<sup>2</sup>

#### **AUTHOR CONTRIBUTIONS**

Sathya Narayanan: data acquisition, drafting of manuscript. Radha Sarawagi: data acquisition, drafting and revising of manuscript, concept of the manuscript.

#### **STUDY FUNDING**

No targeted funding reported.

#### **DISCLOSURE**

The authors report no disclosures relevant to the manuscript. Go to [Neurology.org](http://Neurology.org) for full disclosures.

#### **REFERENCES**

1. Mark D, Murphey MD, Smith WS, et al. Imaging of musculoskeletal neurogenic tumors: radiologic-pathologic correlation. *Radiographics* 1999;19:1253–1280.
2. Chhabra A, Andreisek G, Soldatos T, et al. MR neurography: past, present, and future. *AJR Am J Roentgenol* 2011; 197:583–591.

# Neurology®

## Teaching NeuroImages: Posttraumatic neuroma-in-continuity of the right tibial nerve

Sathya Narayanan and Radha Sarawagi

*Neurology* 2014;82:e198-e199

DOI 10.1212/WNL.0000000000000472

**This information is current as of June 2, 2014**

<b>Updated Information &amp; Services</b>	including high resolution figures, can be found at: <a href="http://n.neurology.org/content/82/22/e198.full">http://n.neurology.org/content/82/22/e198.full</a>
<b>Supplementary Material</b>	Supplementary material can be found at: <a href="http://n.neurology.org/content/suppl/2014/06/01/82.22.e198.DC1">http://n.neurology.org/content/suppl/2014/06/01/82.22.e198.DC1</a>
<b>References</b>	This article cites 2 articles, 0 of which you can access for free at: <a href="http://n.neurology.org/content/82/22/e198.full#ref-list-1">http://n.neurology.org/content/82/22/e198.full#ref-list-1</a>
<b>Subspecialty Collections</b>	This article, along with others on similar topics, appears in the following collection(s): <b>All Clinical Neurology</b> <a href="http://n.neurology.org/cgi/collection/all_clinical_neurology">http://n.neurology.org/cgi/collection/all_clinical_neurology</a> <b>Clinical neurology examination</b> <a href="http://n.neurology.org/cgi/collection/clinical_neurology_examination">http://n.neurology.org/cgi/collection/clinical_neurology_examination</a> <b>Neuropathic pain</b> <a href="http://n.neurology.org/cgi/collection/neuropathic_pain">http://n.neurology.org/cgi/collection/neuropathic_pain</a> <b>Peripheral nerve trauma</b> <a href="http://n.neurology.org/cgi/collection/peripheral_nerve_trauma">http://n.neurology.org/cgi/collection/peripheral_nerve_trauma</a> <b>Peripheral neuropathy</b> <a href="http://n.neurology.org/cgi/collection/peripheral_neuropathy">http://n.neurology.org/cgi/collection/peripheral_neuropathy</a>
<b>Permissions &amp; Licensing</b>	Information about reproducing this article in parts (figures, tables) or in its entirety can be found online at: <a href="http://www.neurology.org/about/about_the_journal#permissions">http://www.neurology.org/about/about_the_journal#permissions</a>
<b>Reprints</b>	Information about ordering reprints can be found online: <a href="http://n.neurology.org/subscribers/advertise">http://n.neurology.org/subscribers/advertise</a>

*Neurology*® is the official journal of the American Academy of Neurology. Published continuously since 1951, it is now a weekly with 48 issues per year. Copyright © 2014 American Academy of Neurology. All rights reserved. Print ISSN: 0028-3878. Online ISSN: 1526-632X.

