

Risk of cerebral arteriovenous malformation rupture during pregnancy and puerperium

OPEN

Xing-ju Liu, MD
Shuo Wang, MD
Yuan-li Zhao, MD
Mario Teo, MD
Peng Guo, MD
Dong Zhang, MD
Rong Wang, MD
Yong Cao, MD
Xun Ye, MD
Shuai Kang, MD
Ji-Zong Zhao, MD

Correspondence to
Dr. Ji-Zong Zhao:
Zhaojz205@gmail.com
or Dr. Liu:
liuxingju006@sina.com

ABSTRACT

Objective: To determine whether the risk of arteriovenous malformation (AVM) rupture is increased during pregnancy and puerperium.

Methods: Participants included 979 female patients with intracranial AVM admitted to Beijing Tiantan Hospital between 1960 and 2010. Two neurosurgery residents reviewed medical records for each case. Of them, 393 patients with ruptured AVM between 18 and 40 years of age were used for case-crossover analysis. Number of children born and clinical information during pregnancy and puerperium were retrieved to identify whether AVM rupture occurred during this period.

Results: Of the 979 women, 797 hemorrhages occurred during 25,578 patient-years of follow-up, yielding an annual hemorrhage rate of 3.11%. The annual AVM hemorrhage rate in patients aged 18 to 40 years ($n = 579$) was 2.78%, lower than the rate in other age groups (odds ratio = 0.75, 95% confidence interval 0.65–0.86, $p < 0.05$). Of the 393 patients with rupture of AVM aged 18 to 40 years, 12 hemorrhages occurred in 12 patients over 452 pregnancies, yielding a hemorrhage rate of 2.65% per pregnancy or 3.32% per year. Among the remaining 381 patients, 441 hemorrhages occurred during 10,627 patient-years of follow-up, yielding an annual hemorrhage rate of 4.14%. The odds ratio for rupture of AVM during pregnancy and puerperium, compared with the control period, was 0.71 (95% confidence interval 0.61–0.82).

Conclusions: No increased risk of hemorrhage was found in patients with cerebral AVM during pregnancy and the puerperium. We therefore would not advise against pregnancy in women with intracranial AVM. *Neurology*® 2014;82:1798–1803

GLOSSARY

AVM = arteriovenous malformation; **CI** = confidence interval; **DSA** = digital subtraction angiography; **OR** = odds ratio.

Hemorrhagic stroke is a serious complication during pregnancy and puerperium that has a substantial maternal mortality of 35% to 83%, contributing to more than 5% to 12% of all maternal deaths.¹ Previous studies suggested that pregnancy and puerperium were associated with an increased risk of stroke.^{2–4} The rupture of cerebral aneurysm and arteriovenous malformation (AVM) were the main causes.^{5–7} In a prospective and population-based study, researchers found that pregnancy did not increase AVM bleed rates, but risk of intracranial hemorrhage was increased during the postpartum period.⁸ Some other studies also found that pregnancy did not increase the risk of hemorrhage from an AVM.^{9,10} Recently, another study reported the rate of intracranial hemorrhage from AVM was 8.1% per pregnancy, higher than the annual hemorrhage rate of AVM in female patients¹¹; however, this study had a limited sample size. Given the increasing number of reported cases of intracranial hemorrhage from AVM during pregnancy and puerperium, we undertook this study to assess whether the risk of AVM rupture is increased during pregnancy and 6 weeks after delivery.

From the Department of Neurosurgery, Beijing Tiantan Hospital (X.-j.-L., S.W., Y.-l.Z., M.T., D.Z., R.W., Y.C., X.Y., S.K., J.-Z.Z.), and Department of Neurosurgery, Beijing Chao-Yang Hospital (P.G.), Capital Medical University, Beijing, China; and Department of Neurosurgery (M.T.), Institute of Neurological Science, Glasgow, UK.

Go to Neurology.org for full disclosures. Funding information and disclosures deemed relevant by the authors, if any, are provided at the end of the article. The Article Processing Charge was paid by the authors.

This is an open access article distributed under the terms of the Creative Commons Attribution-Noncommercial No Derivative 3.0 License, which permits downloading and sharing the work provided it is properly cited. The work cannot be changed in any way or used commercially.

METHODS Study population. Patients were selected from a prospectively collected database of 979 consecutive female patients with a confirmed angiographic or histologic diagnosis of an AVM referred to Beijing Tiantan Hospital from 1960 to 2010. The Beijing Tiantan Hospital served as the referral center for all pregnant women with cerebral AVM rupture in the region of Beijing.

Study design and data analysis. We conducted a case-crossover design, using cases at previous time points as their own controls. In this design, the risk of cerebral AVM rupture during pregnancy and puerperium (exposure period) was compared with the risk excluding pregnancy and puerperium (the control period). In China, more than 99% of women choose to conceive a child between ages 18 and 40 years¹²; therefore, only patients with AVM rupture aged 18 to 40 years were used in the case-crossover design ($n = 393$), and the first 18 years of age were subtracted from the person-time at risk. For each patient, the person-time of exposure period was calculated from the first week of pregnancy to 6 weeks after pregnancy (10 months). The person-time excluding pregnancy and puerperium periods was estimated by subtracting the exposure period from the total person-time. For example, the total person-time at risk for a woman of 28 years who had 2 children was calculated as $28 - 18$ years, the time of exposure period was 2×10 months, and the control period was $(28 - 18) \times 12 - 2 \times 10$ months.

To identify the occurrence of AVM rupture during pregnancy and puerperium, 2 neurosurgery residents reviewed the history of intracranial bleeding and clinical records for each case. In patients with AVM rupture during pregnancy or puerperium, we collected information on maternal age, parity, gestational age, and Glasgow Outcome Scale scores at admission, modes of delivery, treatment, and maternal and fetal outcome. Maternal outcome was categorized according to the 5-point Glasgow Outcome Scale. Fetal outcome was according to the Apgar score on delivery for 1-5-10 minutes: scores 3 and below are generally regarded as critically low, 4-6 fairly low, and 7-10 generally normal.

Recent studies have reported that AVM is a genetic disease¹³⁻¹⁶; therefore, patient-years of follow-up were calculated from birth until AVM obliteration. Annual hemorrhage rate was calculated as the ratio of the number of hemorrhages to total number of patient-years of follow-up. Using case-crossover analysis, the ratio of the observed frequency of hemorrhage in the exposure period to the frequency in the control period was used to calculate estimates

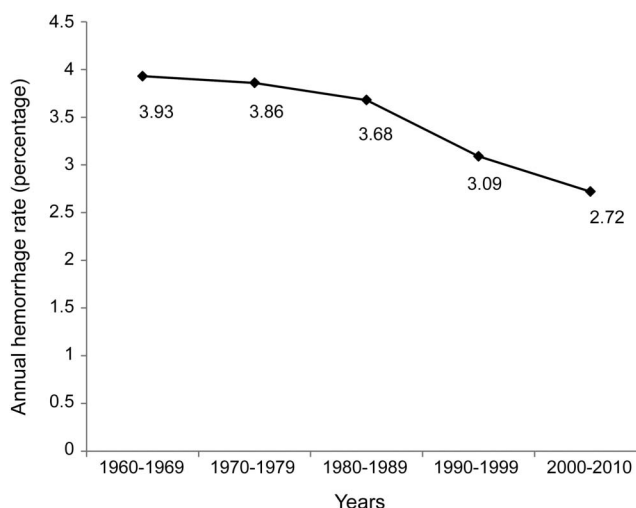
of the odds ratio (OR). ORs and 95% confidence intervals (CIs) for association between pregnancy and the rupture of AVM were estimated using a Mantel-Haenszel estimator¹⁷ (SPSS software, version 16.0; SPSS Inc., Chicago, IL).

Standard protocol approvals, registrations, and patient consents. This study received approval from the Beijing Tiantan Hospital Research Ethics Committee. Written informed consent was obtained from all participants or their guardians (for each patient, written informed consent was completed after admission).

RESULTS Of a total of 979 patients (mean age 26.1 ± 12.4 years), 797 hemorrhages occurred during 25,578 patient-years of follow-up, yielding an annual hemorrhage rate of 3.11%. Of the 579 patients aged 18 to 40 years, 456 hemorrhages occurred during 16,367 patient-years of follow-up, yielding an annual hemorrhage rate of 2.78%, which is lower than the rate in other age groups (OR = 0.75, 95% CI 0.65-0.86, $p < 0.05$). Overall, the annual bleeding rate of AVM decreased year by year in the female patients (figure 1). The characteristics of all patients are shown in table 1, and the age distribution of all patients is shown in figure 2.

There were 393 patients with AVM rupture between the ages of 18 and 40 years. Of them, 54 patients had previous bleeding, and 24 patients (6.1%) received AVM treatment before the first pregnancy, including surgical resection ($n = 18$), gamma knife ($n = 4$), and interventional therapy ($n = 2$). Twelve hemorrhages occurred in 12 patients over 452 pregnancies, yielding a hemorrhage rate of 2.65% per pregnancy or 3.32% per year. Among the remaining 381 patients, 441 hemorrhages occurred during 10,627 patient-years of follow-up, yielding an annual hemorrhage rate of 4.14%. The OR for rupture of AVM during pregnancy and puerperium in patients with AVM,

Figure 1 Changes of annual hemorrhage rate during the past 50 years



Characteristics	No. of patients (%) (n = 979)
Age, y	
Mean ± SD	26.1 ± 12.4
1-17	269 (27.5)
18-40	579 (59.1)
>40	131 (13.4)
Spetzler-Martin grade of AVM	
I-II	321 (32.8)
III-IV	564 (57.6)
V-VI	94 (9.6)
Location of AVM	
Supratentorial	911 (93)
Infratentorial	68 (7.0)
Initial symptoms	
Hemorrhage	587 (60.0)
Hemorrhage and seizure	107 (10.9)
Seizure	153 (15.6)
Other symptoms	132 (13.5)

Abbreviation: AVM = arteriovenous malformation.

compared with the period of time excluding pregnancy and puerperium, was 0.71 (95% CI 0.61–0.82).

Of the 12 patients with AVM rupture during pregnancy and puerperium, headache, vomiting, limb dysfunction, and altered consciousness were the main clinical manifestations. Eleven patients were in antepartum, including 6 in the second trimester and 5 in the third trimester. The mean gestation time was 26.3 ± 7.6 weeks (range 15 to 38 weeks). Only one patient had rupture of AVM in postpartum.

There was no case in the first trimester or during delivery (figure 3).

All patients received emergency CT brain scans and 9 patients underwent emergency digital subtraction angiography (DSA) examinations to confirm the cerebral AVMs. Two patients were confirmed by pathology after operation and one patient was previously diagnosed with a cerebral AVM by DSA. Eight patients had a gestation age of less than 35 weeks. Of them, 4 patients chose to continue pregnancy, 3 of them delivered a healthy baby by cesarean section weeks later, and one delivered a premature baby at 31 weeks; the other 4 patients chose abortion considering the potential biological effects of radiation exposure after extensive counseling.

All patients were managed by multidisciplinary care teams (neurosurgery, neurology, obstetrics and gynecology, pediatrics, intensive care). Nine patients received surgical interventions, including 6 (50%) emergency surgical clot evacuation and resections of AVM, one elective surgical resection of AVM 3 months after cesarean delivery, one decompressive craniotomy, and one gamma knife. There were 4 fetal deaths (4 abortions) and no maternal deaths in the surgical treatment group. Three patients were managed conservatively, 2 with Spetzler-Martin grade V or VI AVM and one with a grade III AVM with a small stable intracranial hemorrhage. Of those managed conservatively, one maternal death occurred. The characteristics of the 12 patients, location of the AVM, mode of delivery, treatment, and maternal and fetal outcome are summarized in table 2.

DISCUSSION In the present study, we did not find an increased risk of AVM rupture in patients aged 18 to 40 years, which were the prime childbearing ages in the Chinese population. The case-crossover

Figure 2 Age distribution of the patients

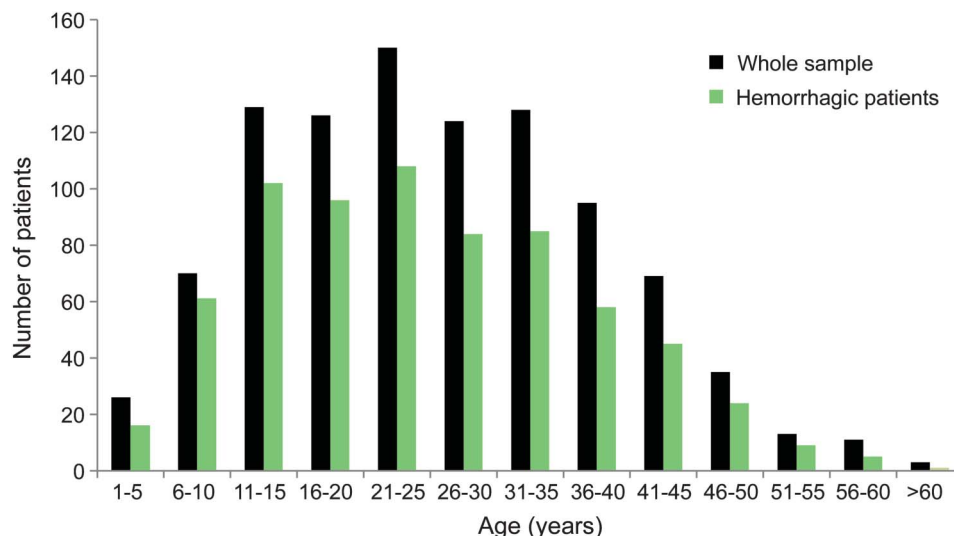
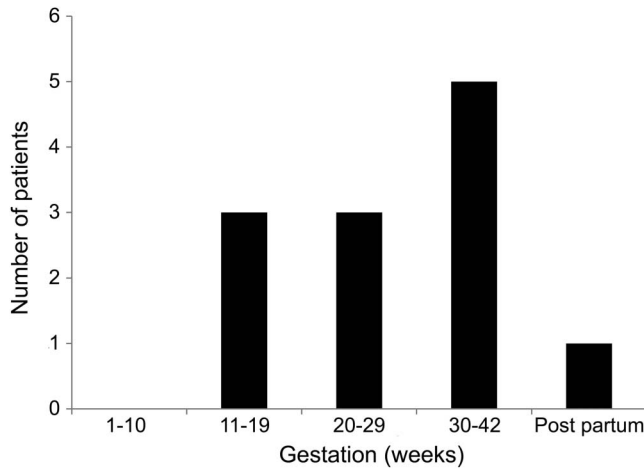


Figure 3 Distribution of gestation weeks of the 12 patients with arteriovenous malformation rupture during pregnancy



analysis using the time of pregnancy and the puerperium as a trigger also did not reveal an increased risk of AVM rupture in patients aged 18 to 40 years. The annual rate of hemorrhage in these patients was similar to the rate reported by natural-history studies of untreated AVM.¹⁸⁻²⁰ These findings show that pregnancy is not associated with an increased risk of intracranial AVM rupture. Therefore, based on our data, we would not advise

against pregnancy in women with intracranial AVMs. However, the issues facing patients with a ruptured AVM in pregnancy remained challenging.

Several predictors of hemorrhage in patients with an untreated cerebral AVM have been established, including patient age, AVM location, and deep venous drainage.²¹ Recently, there is an increasing number of reported cases of AVM rupture during pregnancy and puerperium,^{1,9-11,22-24} and in some studies, it was assumed that pregnancy was a risk factor for AVM rupture. In an earlier study, researchers reviewed 113 young patients with intracranial stroke aged 15 to 45 years and found that pregnancy posed a risk for AVM rupture.²³ However, another study did not find that the natural history of AVM was altered by pregnancy.²⁴ A recent study reviewed 54 women with cerebral AVM and found 4 patients with hemorrhages that occurred over 62 pregnancies.¹¹ The results revealed that the rate of AVM rupture during pregnancy was higher than the annual hemorrhage rate. However, an important limitation of these studies was the small sample size. In this study, we included a larger sample size and used a case-crossover design to analyze the risk of AVM rupture during pregnancy and puerperium. To our knowledge, cases act as their own controls in a case-crossover study design. Only patients having an event

Table 2 Summary of the 12 patients with AVM rupture during pregnancy and puerperium

Patient no.	Age, y	Parity	Gestation wk	CT scan	DSA	S-M grade	Treatment of AVM	Time and mode of delivery	Patient GOS score	Fetal outcome	
										Apgar score, 1-5-10 min	Weight, g
1	40	G2P1	38	L temporal ICH and IVH	No	V	Conservative	38 wk, CS	1	7-8-9	3,250
2	21	G1P0	5 wk after CS	L temporal ICH	Yes	III	Gamma knife	38 wk, CS	5	10-10-10	3,520
3	22	G2P1	18	L frontal ICH	Yes	III	Emergency SR after abortion	Abortion	5	—	—
4	25	G4P1	24	L basal ganglia ICH	Yes	VI	Conservative	31 wk, CS	3	4-6-8	1,700
5	30	G1P0	15	L parietal ICH	Yes	III	Emergency SR	Abortion	4	—	—
6	34	G1P0	35	R temporal ICH	Yes	III	Conservative	35 wk, CS	3	10-10-10	2,860
7	35	G2P1	32	L cerebellum ICH	Yes	III	SR 3 mo after CS	36 wk, CS	5	9-10-10	3,120
8	28	G1P0	26	R parietal ICH and IVH	Yes	V	Decompressive craniotomy	Abortion	2	—	—
9	28	G2P1	20	L frontal and parietal ICH	Yes	III	Emergency SR	35 wk, CS	4	8-9-10	2,560
10	30	G1P0	19	L frontal and parietal ICH	No	III	Emergency SR after abortion	Abortion	3	—	—
11	31	G2P0	32	L parietal ICH	No	IV	Emergency SR after CS	32 wk, CS	4	6-7-8	1,840
12	21	G1P0	30	R frontal ICH	Yes	III	Emergency SR	36 wk, CS	5	6-8-9	2,530

Abbreviations: AVM = arteriovenous malformation; CS = cesarean section; DSA = digital subtraction angiography; G = gravida; GOS = Glasgow Outcome Scale; ICH = intracerebral hemorrhage; IVH = intraventricular hemorrhage; P = para; S-M = Spetzler-Martin; SR = surgical resection.

of interest were enrolled and their exposures were intermittent. Pregnancy and the puerperium are transient and the rupture of AVM is abrupt. Therefore, the exposure during pregnancy and the puerperium is a valid trigger that can be used in a case-crossover study.²⁵

In this study, most patients presented with intracranial hemorrhages in the second and third gestational trimester, accounting for 91.6% of all the patients (figure 3). No case of AVM rupture occurred in the first trimester or during delivery. Although we did not find an increased risk of AVM rupture during pregnancy and the puerperium, we found that the AVM rupture occurred more frequently in late gestational age. This may be correlated with the more extensive changes of hemodynamic parameters, coagulative function, and vessel wall in the third trimester of pregnancy.

Because of small samples and sparse data about the treatment of AVM rupture during pregnancy and puerperium, the management of these patients is very difficult and controversial. Timely and accurate diagnosis of intracranial AVM is of utmost importance. At present, DSA is the gold standard in diagnosing AVM and CT scan is the preferred method in diagnosing intracranial hemorrhage. However, fetal radiation exposure is the major concern when using these examinations. In our group, there were no cases of radiation-induced fetal malformation in patients who chose to continue pregnancy after CT and DSA examinations. Several studies have indicated that the effective radiation dose to the fetus during DSA was very small.^{26–28} Recent studies about radiation exposure and pregnancy also demonstrated that a brain CT can be performed with lead shielding of the abdomen and pelvis.²⁹ Although the additional radiation dose to the fetus from CT and DSA under lead shielding might be small, especially during middle to late pregnancy, further studies with a high level of evidence are needed to confirm this.

At present, there is no Class I or II evidence to guide the treatment of intracranial AVM in women during pregnancy. The timing of surgical intervention is controversial.³⁰ Dias and Sekhar¹ reported that early surgical resection of AVM did not have a better outcome during pregnancy compared with conservative treatment. In this study, one maternal death was encountered in the 12 patients with AVM rupture during pregnancy (8.3% maternal mortality). This seemingly high maternal mortality was in keeping with other large AVM series that quoted approximately 10% risk of death with initial AVM rupture.²⁴ No maternal death occurred in the 6 patients who received emergent surgical resections of AVM (table 2). However, emergency surgical resection of AVM is not the first choice for all patients. For patients with Spetzler-Martin grade V or VI,²⁴ conservative treatment was

preferred because of very high morbidity and mortality associated with operating on these lesions. According to our experience, for patients with grades I to IV AVM, urgent surgical evacuation of the intracranial hematoma and resection of AVM should be performed if signs of brain herniation occur. For patients of later pregnancy, surgical intervention can be performed after cesarean delivery. Furthermore, close collaboration among multidisciplinary teams including the departments of neurology, neurosurgery, obstetrics and anesthesiology, pediatrics, and intensive care has been important for the management of this group of patients.

A strength of this study is that it included a large sample size of female patients with intracranial AVM. We used a case-crossover design to compare the risk of rupture of AVM during pregnancy and puerperium with the risk excluding this period for the cohort of women aged 18 to 40 years. However, we are aware that the single-center retrospective design of this study is one of its limitations, and the study includes exclusively Chinese patients. Second, there might be some patients who had a bleed but were admitted to a different hospital or died before reaching our hospital; therefore, a case ascertainment bias may exist. Third, we did not include patients who might have received AVM resection before 18 years of age in the case-crossover analysis, and these patients would have lower risk of a bleed during pregnancy. In addition, we did not follow up the young patients who presented with hemorrhage before pregnancy to determine whether hemorrhage occurred again during a subsequent pregnancy, so the study cannot answer the question of whether one or more pregnancies increase the risk of AVM rupture. However, we believe that this would be a very small possibility because most patients would have surgical resection of the AVM before their next pregnancy.

Our data suggest that the risk of cerebral AVM rupture is not increased during pregnancy and the puerperium. Therefore, we would not advise against pregnancy in patients with intracranial AVM. However, we found that AVM rupture usually occurred in late gestational age; therefore, more attention should be provided to maintain relative hemodynamic stability in these patients during mid to late pregnancy. The issues facing patients with ruptured AVM in pregnancy remained challenging and required multidisciplinary management including neurosurgeons, obstetricians, pediatricians, and intensivists.

AUTHOR CONTRIBUTIONS

Dr. Xing-ju Liu: study design, acquisition, data collection, analysis, and writing the manuscript. Professor Shuo Wang: study design and critical revision of the manuscript. Dr. Yuan-li Zhao: data interpretation and manuscript revision. Dr. Mario Teo: data interpretation, critical revision of the manuscript for important intellectual content. Drs. Peng Guo and Dong Zhang: data collection, analysis, and interpretation. Dr. Rong Wang: data

collection and analysis. Drs. Yong Cao, Xun Ye, and Shuai Kang: data analysis and interpretation. Professor Ji-Zong Zhao: study concept, design, supervision, and critical revision of the manuscript.

STUDY FUNDING

Supported by the “12th Five-Year Plan” National Science and Technology supporting plan (2011BAI08B00), and the Beijing Municipal Science and Technology Commission (D101107049310001).

DISCLOSURE

X. Liu reports no disclosures relevant to the manuscript. S. Wang serves as vice chairman of the Neurosurgical Society of the Chinese Medical Association, and received institutional support from the National Science and Technology supporting plan. Y. Zhao, M. Teo, P. Guo, D. Zhang, R. Wang, Y. Cao, Y. Xun, and S. Kang report no disclosures relevant to the manuscript. J. Zhao serves as former chairman of the Neurosurgical Society of the Chinese Medical Association and president of the National Research Center of Neurological Diseases, and received institutional support from the National Science and Technology supporting plan and National 973 Plan Project. Go to Neurology.org for full disclosures.

Received November 1, 2013. Accepted in final form February 10, 2014.

REFERENCES

1. Dias MS, Sekhar LN. Intracranial hemorrhage from aneurysms and arteriovenous malformations during pregnancy and the puerperium. *Neurosurgery* 1990;27:855–865.
2. Kittner SJ, Stern BJ, Feeser BR, et al. Pregnancy and the risk of stroke. *N Engl J Med* 1996;335:768–774.
3. Ros HS, Lichtenstein P, Bellocco R, et al. Increased risks of circulatory diseases in late pregnancy and puerperium. *Epidemiology* 2001;12:456–460.
4. Sharshar T, Lamy C, Mas J. Incidence and causes of strokes associated with pregnancy and puerperium: a study in public hospitals of Ile de France. *Stroke* 1995;26:930–936.
5. Davie CA, O'Brien P. Stroke and pregnancy. *J Neurol Neurosurg Psychiatry* 2008;79:240–245.
6. Tiel GA, Rinkel GJ, vander Bom JG, Algra A, Klijn CJ. The risk of aneurysmal subarachnoid hemorrhage during pregnancy, delivery, and the puerperium in the Utrecht population: case-crossover study and standardized incidence ratio estimation. *Stroke* 2009;40:1148–1151.
7. James AH, Bushnell CD, Jamison MG, Myers ER. Incidence and risk factors for stroke in pregnancy and the puerperium. *Obstet Gynecol* 2005;106:509–516.
8. Bateman BT, Schumacher HC, Bushnell CD, et al. Intracerebral hemorrhage in pregnancy: frequency, risk factors, and outcome. *Neurology* 2006;67:424–429.
9. Horton JC, Chambers WA, Lyons SL, et al. Pregnancy and the risk of hemorrhage from cerebral arteriovenous malformations. *Neurosurgery* 1990;27:867–871.
10. Uchida K, Terada S, Akasofu K, et al. Cerebral arteriovenous malformations in a pregnancy with twins: case report. *Neurosurgery* 1992;31:780–782.
11. Gross BA, Du R. Hemorrhage from arteriovenous malformations during pregnancy. *Neurosurgery* 2012;71:349–355.
12. Qiu X, He J, Qiu L, Larson CP, Xia H, Lam KB. Willingness of pregnant women to participate in a birth cohort study in China. *Int J Gynaecol Obstet* 2013;122:216–218.
13. Sturiale CL, Gatto I, Puca A, et al. Association between the rs1333040 polymorphism on the chromosomal 9p21 locus and sporadic brain arteriovenous malformations. *J Neurol Neurosurg Psychiatry* 2013;84:1059–1062.
14. Young WL, Yang GY. Are there genetic influences on sporadic brain arteriovenous malformations? *Stroke* 2004;35:2740–2745.
15. Hademenos GJ, Alberts MJ, Awad I, et al. Advances in the genetics of cerebrovascular disease and stroke. *Neurology* 2001;56:997–1008.
16. Nishida T, Faughnan ME, Krings T, et al. Brain arteriovenous malformations associated with hereditary hemorrhagic telangiectasia: gene-phenotype correlations. *Am J Med Genet* 2012;158:2829–2834.
17. Rothman KJ, Greenland S, Lash TL. *Modern Epidemiology*, 3rd ed. Philadelphia: Lippincott Williams & Wilkins; 2008.
18. Brown RD, Wiebers DO, Forbes G, et al. The natural history of unruptured intracranial arteriovenous malformations. *J Neurosurg* 1988;68:352–357.
19. Ondra SL, Troupp H, George ED, Schwab K. The natural history of symptomatic arteriovenous malformations of the brain: a 24-year follow-up assessment. *J Neurosurg* 1990;73:387–391.
20. da Costa L, Wallace MC, Ter Brugge KG, O'Kelly C, Willinsky RA, Tymianski M. The natural history and predictive features of hemorrhage from brain arteriovenous malformations. *Stroke* 2009;40:100–105.
21. Stapf C, Mast H, Sciacca RR, et al. Predictors of hemorrhage in patients with untreated brain arteriovenous malformation. *Neurology* 2006;66:1350–1355.
22. Liu XJ, Wang S, Zhao YL, Zhang D, Zhao JZ. A single-center study of hemorrhagic stroke caused by cerebrovascular disease during pregnancy and puerperium in China. *Int J Gynaecol Obstet* 2011;113:82–83.
23. Bevan H, Sharma K, Bradley W. Stroke in young adults. *Stroke* 1990;21:382–386.
24. Spetzler RF, Martin NA. A proposed grading system for arteriovenous malformations. *J Neurosurg* 1986;65:476–483.
25. Maclure M. The case-crossover design: a method for studying transient effects on the risk of acute events. *Am J Epidemiol* 1991;133:144–153.
26. Marshman LA, Rai MS, Aspoas AR. Comment to “Endovascular treatment of ruptured intracranial aneurysms during pregnancy: report of three cases”. *Arch Gynecol Obstet* 2005;272:93.
27. Le TT, Haskal ZJ, Holland GA, et al. Endovascular stent placement and magnetic resonance angiography for management of hypertension and renal artery occlusion during pregnancy. *Obstet Gynecol* 1995;85:822–825.
28. Sanchez-Ramos L, Chami YG, Bass TA, et al. Myocardial infarction during pregnancy: management with transluminal coronary angioplasty and metallic intracoronary stents. *Am J Obstet Gynecol* 1994;171:1392–1393.
29. Cynthia H, McCollough CH, Schueler BA, et al. Radiation exposure and pregnancy: when should we be concerned? *Radiographics* 2007;27:909–917.
30. Trivedi RA, Kirkpatrick PJ. Arteriovenous malformations of the cerebral circulation that rupture in pregnancy. *J Obstet Gynaecol* 2003;23:484–489.

Neurology®

Risk of cerebral arteriovenous malformation rupture during pregnancy and puerperium

Xing-ju Liu, Shuo Wang, Yuan-li Zhao, et al.

Neurology 2014;82;1798-1803 Published Online before print April 23, 2014

DOI 10.1212/WNL.0000000000000436

This information is current as of April 23, 2014

Updated Information & Services	including high resolution figures, can be found at: http://n.neurology.org/content/82/20/1798.full
References	This article cites 29 articles, 10 of which you can access for free at: http://n.neurology.org/content/82/20/1798.full#ref-list-1
Citations	This article has been cited by 1 HighWire-hosted articles: http://n.neurology.org/content/82/20/1798.full##otherarticles
Subspecialty Collections	This article, along with others on similar topics, appears in the following collection(s): Arteriovenous malformation http://n.neurology.org/cgi/collection/arteriovenous_malformation Case control studies http://n.neurology.org/cgi/collection/case_control_studies Intracerebral hemorrhage http://n.neurology.org/cgi/collection/intracerebral_hemorrhage Risk factors in epidemiology http://n.neurology.org/cgi/collection/risk_factors_in_epidemiology
Permissions & Licensing	Information about reproducing this article in parts (figures, tables) or in its entirety can be found online at: http://www.neurology.org/about/about_the_journal#permissions
Reprints	Information about ordering reprints can be found online: http://n.neurology.org/subscribers/advertise

Neurology® is the official journal of the American Academy of Neurology. Published continuously since 1951, it is now a weekly with 48 issues per year. Copyright © 2014 American Academy of Neurology. All rights reserved. Print ISSN: 0028-3878. Online ISSN: 1526-632X.

