

Pearls & Oysters: An unusual case of varicella-zoster virus cerebellitis and vasculopathy

Francesca Calabria, MD
Francesca Zappini, MD
Gaetano Vattermi, MD,
PhD
Michele Tinazzi, MD,
PhD

Correspondence to
Dr. Calabria:
francescacalabria@live.it

PEARLS

1. CNS complications of varicella-zoster virus (VZV) occur mainly in immunocompromised or elderly patients and include meningitis, myelitis, acute encephalitis, vasculopathy, and, rarely, cerebellitis.^{1–8}
2. Clinical diagnosis of VZV neurologic disorders is confirmed by virologic analysis with the detection of VZV DNA or anti-VZV immunoglobulin G (IgG) antibody in the CSF.^{6,7}

OY-STERS

1. Neurologists should be aware of the possibility of CNS involvement following VZV reactivation even in immunocompetent patients.
2. Antiviral treatment should be started as soon as clinical diagnosis is suspected because therapy can lead to partial or complete resolution of the neurologic deficits.⁷

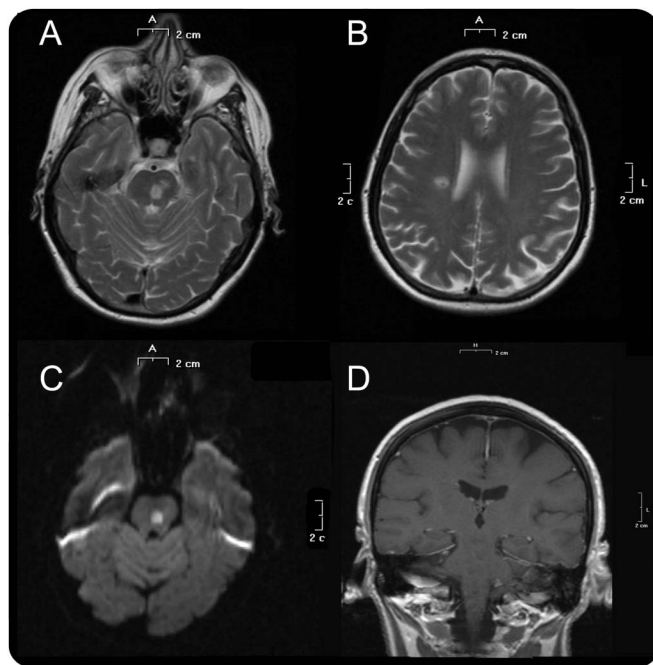
CASE REPORT A 67-year-old woman presented with unsteadiness and dizziness of gradual onset. Two weeks before presentation, the patient had a painful vesicular rash at the left ear followed within 9 days by acute left peripheral facial palsy; a diagnosis of Ramsay Hunt syndrome (RHS) was made and oral valacyclovir was started. A few days after initiating valacyclovir, she developed gait instability, which gradually worsened. Her medical history disclosed well-controlled diabetes mellitus and hypertension, and therapy included metformin, ramipril, hydrochlorothiazide, and acetylsalicylic acid. On neurologic examination, the patient was unable to stand and walk unassisted; she had a wide-based gait, predominantly left-sided limb ataxia, and bilateral dysidiadochokinesia. On cranial nerve examination, the patient had a left lower motor neuron facial palsy and had pain in all 3 branches of the left trigeminal nerve. Deep tendon reflexes, strength, and sensation were normal. Head CT displayed hypodensity of the left medial pons, and, because of suspected CNS involvement by VZV, the patient was treated with IV acyclovir (10 mg/kg 3 times daily) for 10 days. Brain MRI, performed the second day of therapy,

revealed one lesion in the left pons, one in the left mid-brain, and one in the right periventricular area. All 3 lesions were hyperintense on T2 and diffusion-weighted imaging sequences and hypointense on apparent diffusion coefficient, consistent with recent ischemic lesions (figure). No other supratentorial or cerebellar lesions were seen. Magnetic resonance angiography (MRA) was normal. Absolute lymphocyte count was 550/ μ L (normal 0.95–4.40) with inversion of the CD4+:CD8+ T-cell ratio. CSF analysis showed 40 leukocytes/ μ L (mainly mononuclear cells), 40 erythrocytes/ μ L, protein 0.46 g/L (normal 0.15–0.45), and glucose 99 mg/dL (normal 45–80). CSF VZV PCR was positive and anti-VZV IgG antibody was detected in the CSF. PCR tests for other neurotropic viruses were negative. Common causes of stroke including atherosclerosis or dissection were excluded. After 2 days of treatment with IV acyclovir, the patient's symptoms improved and at discharge she had no difficulty in standing and walked with unilateral support. Facial pain was treated successfully with carbamazepine 400 mg/day. At the last follow-up 3 months later, the patient walked without support, retained a mild facial weakness, and denied facial pain after she gradually ceased carbamazepine.

DISCUSSION We describe a healthy, immunocompetent adult patient who developed herpes zoster that progressed to cerebellar ataxia and trigeminal neuropathic pain. Brain MRI findings of focal ischemic lesions in the brainstem and right hemisphere are inconsistent with cerebellar involvement, while trigeminal dysfunction presumably results from the lesion in the left pons. Based on 1) the evidence of MRI abnormalities; 2) the detection of VZV DNA and anti-VZV IgG antibody in the CSF; 3) the improvement of symptoms following acyclovir treatment; and 4) the exclusion of alternative cause for acute cerebellar ataxia and stroke, the patient was diagnosed with VZV cerebellitis and multifocal vasculopathy. Therefore, we hypothesize that in our patient the reactivation of VZV from the geniculate

From the Department of Neurological, Neuropsychological, Morphological and Movement Sciences, Section of Clinical Neurology, University of Verona, Italy.

Go to Neurology.org for full disclosures. Funding information and disclosures deemed relevant by the authors, if any, are provided at the end of the article.



(A) Hyperintensity on T2-weighted sequences at the pons. (B) Periventricular lesion on T2-weighted sequences. (C) Diffusion-weighted imaging hyperintensity of the pons lesion. (D) No enhancement after IV gadolinium.

ganglion causing RHS was followed by anterograde transaxonal spread of virus through the sensory pathways to both cerebellum and cerebral arteries, causing cerebellitis and trigeminal impairment, respectively. Although the average time from rash to the onset of neurologic symptoms and signs in VZV vasculopathy is typically a few months, they can occur simultaneously or within a week.⁶ TIAs and stroke are not uncommon after VZV reactivation in adults even without rash, and vasculopathy is caused by viral infection of the blood vessels.^{5–7} In our patient, MRA did not document any focal narrowing or stenosis in the large and medium cerebral arteries, suggesting that disease exclusively affected small arteries in this patient. Acute cerebellar ataxia as a result of VZV is extremely rare in adults and it has not been reported following herpes zoster.¹ Indeed, 3 adult

patients with VZV cerebellitis without a history of rash have been described in the literature.

We report a virologically documented case of double CNS complications occurring with VZV reactivation and emphasize the importance of recognizing this neurologic disorder susceptible to improvement with antiviral therapy.

AUTHOR CONTRIBUTIONS

F. Calabria: collecting data, drafting/revising the manuscript. F. Zappini: collecting data/revising the manuscript. G. Vattermi: drafting/revising the manuscript. M. Tinazzi: drafting/revising the manuscript.

STUDY FUNDING

No targeted funding reported.

DISCLOSURE

The authors report no disclosures relevant to the manuscript. Go to Neurology.org for full disclosures.

REFERENCES

1. Gilden D, Cohrs RJ, Mahalingam R, Nagel MA. Neurological disease produced by varicella zoster virus reactivation without rash. *Curr Top Microbiol Immunol* 2010;342:243–253.
2. Gilden D, Nagel MA, Mahalingam R, et al. Clinical and molecular aspects of varicella zoster virus infection. *Future Neurol* 2009;4:103–117.
3. Eskiizmir G, Uz U, Taskiran E, Unlu H. Herpes zoster oticus associated with varicella zoster virus encephalitis. *Laryngoscope* 2009;119:628–630.
4. Steiner I, Kennedy PG, Pachner AR. The neurotropic herpes viruses: herpes simplex and varicella-zoster. *Lancet Neurol* 2007;6:1015–1028.
5. De Broucker T, Mailles A, Chabrier S, Morand P, Stahl JP; Steering Committee and Investigators Group. Acute varicella zoster encephalitis without evidence of primary vasculopathy in a case-series of 20 patients. *Clin Microbiol Infect* 2012;18:808–819.
6. Nagel MA, Cohrs RJ, Mahalingam R, et al. The varicella zoster virus vasculopathies: clinical, CSF, imaging, and virologic features. *Neurology* 2008;70:853–860.
7. Gilden D, Cohrs RJ, Mahalingam R, Nagel MA. Varicella zoster virus vasculopathies: diverse clinical manifestations, laboratory features, pathogenesis, and treatment. *Lancet Neurol* 2009;8:731–740.
8. Shuching H, Melanie W, Todd C, et al. Acyclovir responsive brain stem disease after the Ramsay Hunt syndrome. *J Neurol Sci* 2004;217:111–113.

Neurology®

Pearls & Oy-sters: An unusual case of varicella-zoster virus cerebellitis and vasculopathy

Francesca Calabria, Francesca Zappini, Gaetano Vattermi, et al.

Neurology 2014;82:e14-e15

DOI 10.1212/WNL.0000000000000011

This information is current as of January 13, 2014

Updated Information & Services	including high resolution figures, can be found at: http://n.neurology.org/content/82/2/e14.full
References	This article cites 8 articles, 1 of which you can access for free at: http://n.neurology.org/content/82/2/e14.full#ref-list-1
Subspecialty Collections	This article, along with others on similar topics, appears in the following collection(s): Trigeminal neuralgia http://n.neurology.org/cgi/collection/trigeminal_neuralgia
Permissions & Licensing	Information about reproducing this article in parts (figures, tables) or in its entirety can be found online at: http://www.neurology.org/about/about_the_journal#permissions
Reprints	Information about ordering reprints can be found online: http://n.neurology.org/subscribers/advertise

Neurology® is the official journal of the American Academy of Neurology. Published continuously since 1951, it is now a weekly with 48 issues per year. Copyright © 2014 American Academy of Neurology. All rights reserved. Print ISSN: 0028-3878. Online ISSN: 1526-632X.

