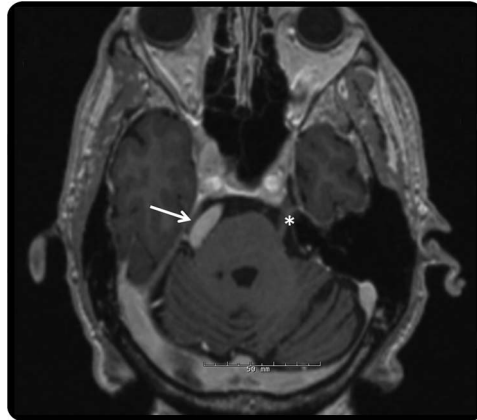


# Teaching NeuroImages: Concurrent hemifacial spasm and trigeminal neuralgia due to vertebrobasilar dolichoectasia

Shaheen E. Lakhan, MD,  
PhD, MS, Med

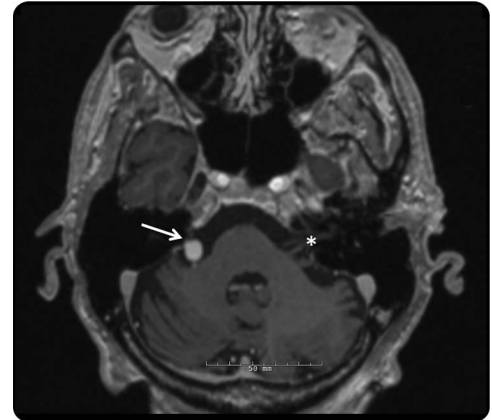
Correspondence to  
Dr. Lakhan:  
slakhan@gnif.org

**Figure 1** Brain MRI, 3D magnetization-prepared rapid acquisition, axial view



MRI demonstrates dolichoectatic basilar artery distorting the right trigeminal nerve at the level of the mid pons (arrow). For reference, contralateral trigeminal nerve displayed with asterisk.

**Figure 2** Brain MRI, 3D magnetization-prepared rapid acquisition, axial view



MRI demonstrates dolichoectatic basilar artery distorting the right facial nerve at the cerebellopontine angle (arrow). For reference, contralateral facial nerve displayed with asterisk.

A 64-year-old man reported a 2-week worsening of a 2-year history of paroxysmal, lancinating right facial pain and spasms. Head CT demonstrated a tortuous and ectatic vertebral-basilar system. MRI confirmed a dolichoectatic basilar artery that distorted the right trigeminal (figure 1) and facial nerve roots (figure 2). He failed conservative medical management including carbamazepine, oxcarbazepine, and levetiracetam. He underwent Gamma Knife radiosurgery with a few months of pain relief and was offered botulinum neurotoxin injection for spasms.

This case represents a rare presentation of concurrent hemifacial spasm and trigeminal neuralgia linked to an ectatic basilar artery.<sup>1</sup>

#### STUDY FUNDING

No targeted funding reported.

#### DISCLOSURE

Dr. Lakhan serves on the American Academy of Neurology's Distance Learning Subcommittee and is an editorial team member of the Resident & Fellow Section of *Neurology*<sup>®</sup>. Go to [Neurology.org](http://Neurology.org) for full disclosures.

#### REFERENCE

1. Kwon HM, Lee YS. Dolichoectasia of the intracranial arteries. *Curr Treat Options Cardiovasc Med* 2011;13:261–267.

# Neurology®

## Teaching NeuroImages: Concurrent hemifacial spasm and trigeminal neuralgia due to vertebrobasilar dolichoectasia

Shaheen E. Lakhani

*Neurology* 2013;81:e52

DOI 10.1212/WNL.0b013e3182a1aeb

**This information is current as of August 19, 2013**

<b>Updated Information &amp; Services</b>	including high resolution figures, can be found at: <a href="http://n.neurology.org/content/81/8/e52.full">http://n.neurology.org/content/81/8/e52.full</a>
<b>Supplementary Material</b>	Supplementary material can be found at: <a href="http://n.neurology.org/content/suppl/2013/08/14/81.8.e52.DC1">http://n.neurology.org/content/suppl/2013/08/14/81.8.e52.DC1</a>
<b>References</b>	This article cites 1 articles, 0 of which you can access for free at: <a href="http://n.neurology.org/content/81/8/e52.full#ref-list-1">http://n.neurology.org/content/81/8/e52.full#ref-list-1</a>
<b>Subspecialty Collections</b>	This article, along with others on similar topics, appears in the following collection(s): <b>All Movement Disorders</b> <a href="http://n.neurology.org/cgi/collection/all_movement_disorders">http://n.neurology.org/cgi/collection/all_movement_disorders</a> <b>Other cerebrovascular disease/ Stroke</b> <a href="http://n.neurology.org/cgi/collection/other_cerebrovascular_disease__stroke">http://n.neurology.org/cgi/collection/other_cerebrovascular_disease__stroke</a> <b>Trigeminal neuralgia</b> <a href="http://n.neurology.org/cgi/collection/trigeminal_neuralgia">http://n.neurology.org/cgi/collection/trigeminal_neuralgia</a>
<b>Permissions &amp; Licensing</b>	Information about reproducing this article in parts (figures, tables) or in its entirety can be found online at: <a href="http://www.neurology.org/about/about_the_journal#permissions">http://www.neurology.org/about/about_the_journal#permissions</a>
<b>Reprints</b>	Information about ordering reprints can be found online: <a href="http://n.neurology.org/subscribers/advertise">http://n.neurology.org/subscribers/advertise</a>

*Neurology*® is the official journal of the American Academy of Neurology. Published continuously since 1951, it is now a weekly with 48 issues per year. Copyright © 2013 American Academy of Neurology. All rights reserved. Print ISSN: 0028-3878. Online ISSN: 1526-632X.

