



## In Focus

### Spotlight on the August 20 Issue

**Robert A. Gross, MD, PhD, FAAN**  
Editor-in-Chief, *Neurology*<sup>®</sup>



#### **Temporal reorganization to overcome monocular demyelination**

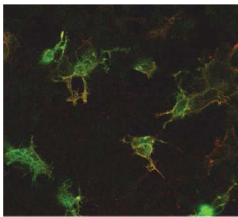
This study followed 17 patients with a diagnosis of first-ever unilateral optic neuritis and 17 controls for 12 to 26 months. Delayed latencies in the fellow eyes reflected adaptive mechanisms at the cortical level that improved binocular integration, presumably adjusting for decreases in visual perception due to optic neuritis.

See p. 702

*From editorialists Lueck & Costello: "...if confirmed by subsequent studies, this process of central temporal adaptation may represent a more widespread phenomenon by which the brain recovers from damage."*

See p. 698

#### **Anti-neurofascin antibody in patients with combined central and peripheral demyelination**



The authors screened target antigens by immunohistochemistry and immunoblotting to identify target antigens recognized by serum antibodies in combined central and peripheral demyelination (CCPD) and chronic inflammatory demyelinating

polyradiculoneuropathy cases. Anti-neurofascin antibody was frequently present in patients with CCPD; antibody-positive CCPD patients respond well to IV immunoglobulin or plasma exchange.

See p. 714

#### **Cardiovascular disease and spinal cord injury: Results from a national population health survey**

After evaluating data from 60,000 individuals and adjusting for age and sex, spinal cord injury was associated with increased odds of heart disease and stroke. These remarkably heightened odds highlight the exigent need for targeted interventions and prevention strategies addressing modifiable risk factors for cardiovascular disease in individuals with spinal cord injury.

See p. 723; Editorial, p. 700

#### **White matter hyperintensities on MRI in high-altitude U-2 pilots**

The authors evaluated imaging findings in 102 U-2 pilots and 91 controls matched for age, health, and education levels. The finding of increased volume and number of white matter hyperintensities in pilots exposed to high altitudes, without hypoxia and without clinical symptoms, suggests that our current understanding of neurologic decompression sickness is incomplete and identifies a need for additional international research.

See p. 729

#### **Impaired default network functional connectivity in autosomal dominant Alzheimer disease**

Eighty-three mutation carriers and 37 asymptomatic noncarriers from the same families underwent functional connectivity MRI (fcMRI) during resting state. Using group-independent component analysis, fcMRI was compared using mutation status and Clinical Dementia Rating. Default mode network fcMRI may prove useful as a biomarker and as a secondary endpoint in upcoming clinical trials in Alzheimer disease.

See p. 736

#### **Early seizure onset and dysplastic lesion extent independently disrupt cognitive networks**

Surgical patients with verified focal cortical dysplasia were evaluated to determine the roles of histopathology, extent of lobar involvement, hemispheric laterality, age at onset, and duration of epilepsy on cognitive functioning. Early seizure onset and pathology extent contributed separately to cognitive morbidity in children with histologically proven focal cortical dysplasia.

See p. 745

#### **The semiology of tilt-induced psychogenic pseudosyncope**

Psychogenic pseudosyncope (PPS) is a common cause of apparent transient loss of consciousness (TLOC). The authors present the semiology of PPS based on the analysis of consecutive episodes of tilt-evoked, proven PPS. Eye closure during apparent TLOC is indicative of PPS; heart rate and blood pressure are also elevated in PPS.

See p. 752

NB: "Propofol-related infusion syndrome heralding a mitochondrial disease: Case report," see p. 770. To check out other Clinical/Scientific Notes, point your browser to [www.neurology.org](http://www.neurology.org).

Podcasts can be accessed at [www.neurology.org](http://www.neurology.org)

# Neurology<sup>®</sup>

## Spotlight on the August 20 Issue

Robert A. Gross

*Neurology* 2013;81;697

DOI 10.1212/WNL.0b013e3182a1c7dd

### This information is current as of August 19, 2013

**Updated Information & Services**

including high resolution figures, can be found at:  
<http://n.neurology.org/content/81/8/697.full>

**Permissions & Licensing**

Information about reproducing this article in parts (figures, tables) or in its entirety can be found online at:  
[http://www.neurology.org/about/about\\_the\\_journal#permissions](http://www.neurology.org/about/about_the_journal#permissions)

**Reprints**

Information about ordering reprints can be found online:  
<http://n.neurology.org/subscribers/advertise>

*Neurology*® is the official journal of the American Academy of Neurology. Published continuously since 1951, it is now a weekly with 48 issues per year. Copyright © 2013 American Academy of Neurology. All rights reserved. Print ISSN: 0028-3878. Online ISSN: 1526-632X.

