



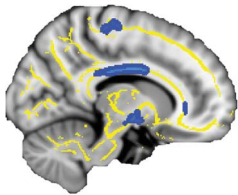
## In Focus

### Spotlight on the February 12 Issue

**Robert A. Gross, MD, PhD, FAAN**  
Editor-in-Chief, *Neurology*®



#### Whole-brain magnetic resonance spectroscopic imaging measures are related to disability in ALS



Magnetic resonance spectroscopic imaging has demonstrated cerebral N-acetylaspartate decreases as a potential biomarker of neuronal loss, but most studies have examined only a small region of interest. The Metabolite Imaging

and Data Analysis System permitted whole-brain study and linked NAA decreases within the corticospinal tract to disability in ALS.

See p. 610

From editorialists Brodtmann & Kiernan: "...these recent neuroimaging findings outline a model of ALS as a 'systems degeneration,' bringing us one step closer to an understanding of how ALS disease spread may occur."

See p. 606

#### ALS dysphagia pathophysiology: Differential botulinum toxin response ▲

The improvement after botulinum toxin type A observed in patients with isolated upper esophageal sphincter dysfunction suggests a different ALS pathophysiology of dysphagia that responds better to this treatment. Botulinum toxin type A may be an alternative to treatment with percutaneous endoscopic gastrostomy (PEG) and may prolong PEG-free time.

See p. 616

#### Prognostic factors of motor impairment, disability, and quality of life in newly diagnosed PD 📖

The authors assessed disease progression in 129 patients with newly diagnosed PD. The presence of levodopa-nonresponsive motor symptoms and cognitive dysfunction at the time of diagnosis were the main determinants of disability, showing the importance of extra-nigrostriatal pathology in PD.

See p. 627

#### Functional disturbance of the locomotor network in progressive supranuclear palsy

[<sup>18</sup>F]-FDG-PET scans were performed in 12 patients with progressive supranuclear palsy (PSP) and 12 controls during walking and at rest. Gait impairment in PSP was associated with dysfunction of the indirect, modulatory prefrontal-subthalamic-pedunculo-pontine loop of locomotor control; activity in the direct, stereotyped locomotor loop to the spinal cord with rhythmic cerebellar drive was increased.

See p. 634

#### A randomized controlled trial of intranasal ketamine in migraine with prolonged aura 📖 ▲

This study investigated the effect of 25 mg intranasal ketamine on migraine with prolonged aura in 30 migraineurs using 2 mg intranasal midazolam as an active control, with data from 3 episodes recorded. Intranasal ketamine was effective in reducing aura severity in patients with migraine with prolonged aura.

See p. 642

#### Cerebral atrophy in mild cognitive impairment and Alzheimer disease: Rates and acceleration

The authors quantified the cerebral atrophy rates and acceleration rates using 0-, 6-, 12-, 18-, 24- and 36-month MRI scans in subjects with mild cognitive impairment, subjects with mild Alzheimer disease (AD), and healthy controls. The small acceleration rates suggested a long period of transition to the pathologic losses seen in clinical AD.

See p. 648

#### CONTEMPORARY ISSUES

##### Telemedicine applications: Report of the Telemedicine Work Group of the American Academy of Neurology 📖

This article discusses telemedicine from the patient and provider perspectives; also discussed are the experience from the military, barriers to growth of telemedicine, and the importance of support from the American Academy of Neurology. Telemedicine provides opportunities for neurologists and patients to improve care and enhance neurologic practice.

See p. 670

NB: "A keratoma horn following deep brain stimulation," see p. 688. To check out other NeuroImages, point your browser to [www.neurology.org](http://www.neurology.org).

Podcasts can be accessed at [www.neurology.org](http://www.neurology.org)

# Neurology<sup>®</sup>

## Spotlight on the February 12 Issue

Robert A. Gross

*Neurology* 2013;80;605

DOI 10.1212/WNL.0b013e318283bb2d

**This information is current as of February 11, 2013**

**Updated Information & Services**

including high resolution figures, can be found at:  
<http://n.neurology.org/content/80/7/605.full>

**Permissions & Licensing**

Information about reproducing this article in parts (figures, tables) or in its entirety can be found online at:  
[http://www.neurology.org/about/about\\_the\\_journal#permissions](http://www.neurology.org/about/about_the_journal#permissions)

**Reprints**

Information about ordering reprints can be found online:  
<http://n.neurology.org/subscribers/advertise>

*Neurology*® is the official journal of the American Academy of Neurology. Published continuously since 1951, it is now a weekly with 48 issues per year. Copyright © 2013 American Academy of Neurology. All rights reserved. Print ISSN: 0028-3878. Online ISSN: 1526-632X.

