

# Mystery Case: Hemiballism in a patient with parietal lobe infarction



Meng-Chen Wu, MD  
Ruoh-Fang Yen, MD  
Chin-Hsien Lin, MD,  
PhD  
Ruey-Meei Wu, MD,  
PhD

Correspondence to  
Dr. Lin:  
chlin@ntu.edu.tw

A 60-year-old man with a history of atrial fibrillation had an acute onset of ballistic movements of the left limbs with sensory extinction (video on the *Neurology*® Web site at [www.neurology.org](http://www.neurology.org)). The patient was treated with risperidone and anticoagulant; symptoms subsided 3 days later. Brain MRI showed acute infarction of the right posterior parietal lobe (figure 1) and SPECT revealed hypoperfusion in the right frontoparietal areas (figure 2).

Hemiballism is a rare movement disorder often associated with lesions in the subthalamic nucleus (STN). Lesions outside the STN are rarely reported.<sup>1,2</sup> A disorganized sensorimotor integration in frontoparietal lobes resulting in decreased excitatory output to STN probably causes this phenomenon.

## STUDY FUNDING

No targeted funding reported.

## DISCLOSURE

The authors report no disclosures relevant to the manuscript. Go to [Neurology.org](http://Neurology.org) for full disclosures.

## REFERENCES

1. Srivastava T, Singh S, Goyal V, Shukla G, Behari M. Hemichorea-hemiballism associated with frontoparietal bleed. *J Neurol* 2006;253:653–654.
2. Mizushima N, Park-Matsumoto YC, Amakawa T, Hayashi H. A case of hemichorea-hemiballism associated with parietal lobe infarction. *Eur J Neurol* 1997;37:65–66.

**MYSTERY CASE RESPONSES** The Mystery Case series was initiated by the *Neurology*® Resident & Fellow Section to develop the clinical reasoning skills of trainees. Residency programs, medical student preceptors, and individuals were invited to use this Mystery Case as an education tool. Responses were solicited through a group e-mail sent to the American Academy of Neurology Consortium of Neurology Residents and Fellows and through social media. All the answers that we received came from individual residents rather than groups and they were all well-reasoned and thoughtful. Most respondents (over 90%) correctly identified the involuntary, large-amplitude, flinging movements of the left side limbs as hemiballismus and considered an ischemic stroke as the most likely mechanism; 30% of respondents considered lesion sites other than the STN, including basal ganglia and cortex.

The teaching point of this Mystery Case is that while most injuries causing hemiballismus occur within the subcortical nuclei (classically the STN), there are reported cases of damage to cortical structures causing hemiballismus. In addition, lesions of the STN usually produce a more severe movement disorder than lesions of other structures.<sup>1</sup>

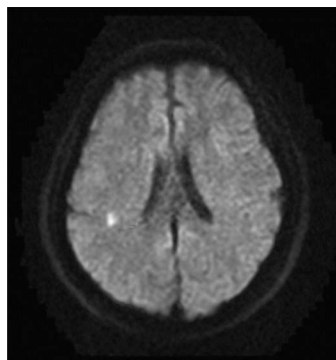
Dragos A. Nita, MD, PhD

*The Hospital for Sick Children, University of Toronto, Toronto, Canada.*

## REFERENCE

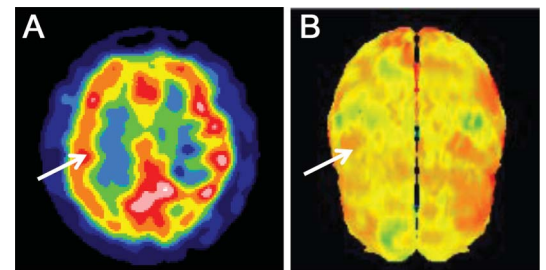
1. Postum RB, Lang AE. Hemiballism: revisiting a classic disorder. *Lancet Neurol* 2003;2:661–668.

**Figure 1** MRI of the patient's brain



Axial view of diffusion-weighted MRI at frontoparietal level.

**Figure 2** SPECT images of the patient's brain



(A) Axial view of SPECT at frontoparietal level. (B) 3D cortical perfusion SPECT image at the same level. The arrows indicate hypoperfusion of right frontoparietal regions.

Supplemental data at  
[www.neurology.org](http://www.neurology.org)

From the Departments of Neurology (M.-C.W., C.-H.L., R.-M.W.) and Nuclear Medicine (R.-F.Y.), National Taiwan University Hospital, Taipei.

# Neurology®

## Mystery Case: Hemiballism in a patient with parietal lobe infarction

Meng-Chen Wu, Ruoh-Fang Yen, Chin-Hsien Lin, et al.

*Neurology* 2013;80:e22

DOI 10.1212/WNL.0b013e31827deb11

**This information is current as of January 14, 2013**

<b>Updated Information &amp; Services</b>	including high resolution figures, can be found at: <a href="http://n.neurology.org/content/80/3/e22.full">http://n.neurology.org/content/80/3/e22.full</a>
<b>Supplementary Material</b>	Supplementary material can be found at: <a href="http://n.neurology.org/content/suppl/2013/01/12/80.3.e22.DC1">http://n.neurology.org/content/suppl/2013/01/12/80.3.e22.DC1</a>
<b>References</b>	This article cites 3 articles, 0 of which you can access for free at: <a href="http://n.neurology.org/content/80/3/e22.full#ref-list-1">http://n.neurology.org/content/80/3/e22.full#ref-list-1</a>
<b>Subspecialty Collections</b>	This article, along with others on similar topics, appears in the following collection(s): <b>All Movement Disorders</b> <a href="http://n.neurology.org/cgi/collection/all_movement_disorders">http://n.neurology.org/cgi/collection/all_movement_disorders</a> <b>Chorea</b> <a href="http://n.neurology.org/cgi/collection/chorea">http://n.neurology.org/cgi/collection/chorea</a> <b>Embolism</b> <a href="http://n.neurology.org/cgi/collection/embolism">http://n.neurology.org/cgi/collection/embolism</a> <b>MRI</b> <a href="http://n.neurology.org/cgi/collection/mri">http://n.neurology.org/cgi/collection/mri</a> <b>SPECT</b> <a href="http://n.neurology.org/cgi/collection/spect">http://n.neurology.org/cgi/collection/spect</a>
<b>Permissions &amp; Licensing</b>	Information about reproducing this article in parts (figures, tables) or in its entirety can be found online at: <a href="http://www.neurology.org/about/about_the_journal#permissions">http://www.neurology.org/about/about_the_journal#permissions</a>
<b>Reprints</b>	Information about ordering reprints can be found online: <a href="http://n.neurology.org/subscribers/advertise">http://n.neurology.org/subscribers/advertise</a>

*Neurology*® is the official journal of the American Academy of Neurology. Published continuously since 1951, it is now a weekly with 48 issues per year. Copyright © 2013 American Academy of Neurology. All rights reserved. Print ISSN: 0028-3878. Online ISSN: 1526-632X.

