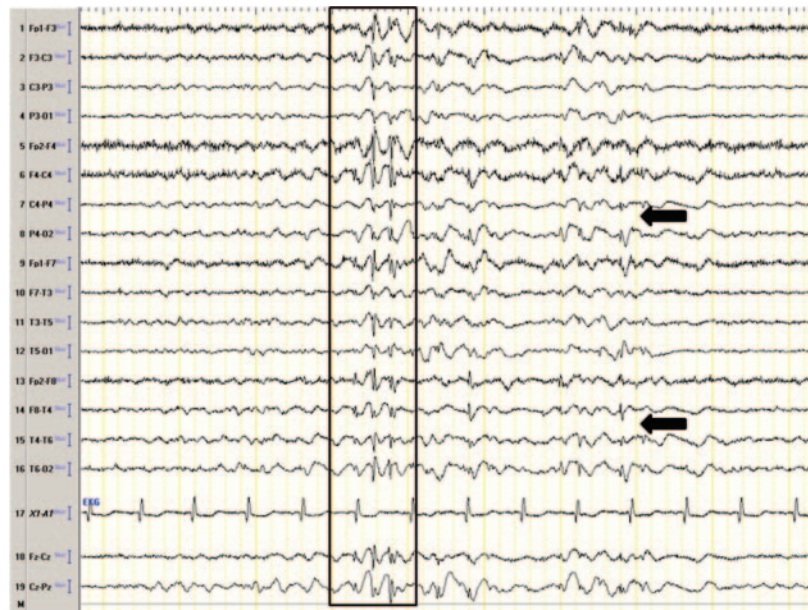

Teaching NeuroImages: Hemispheric epilepsy

Giridhar P. Kalamangalam,
MD, DPhil, FRCP
Prasuna Velur, MD

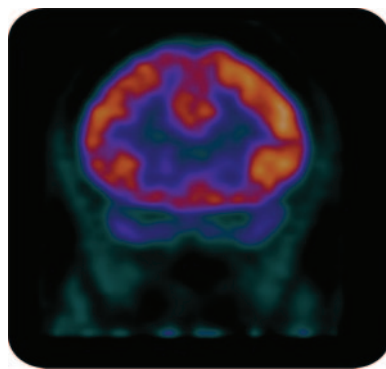
Correspondence & reprint
requests to Dr. Kalamangalam:
Giridhar.P.Kalamangalam@uth.
tmc.edu

Figure 1 Interictal epileptiform activity in drowsiness



A generalized fast spike-wave burst (boxed) with right hemispheric maximum, followed by right hemispheric spike fragments (arrows).

Figure 2 Interictal FDG-PET



Coronal view through the frontal lobes shows right-sided hypometabolism.

A 48-year-old woman was evaluated for a 40-year history of medically refractory absence and generalized tonic-clonic seizures. Neurologic examination and brain MRI were normal. Awake interictal EEG showed generalized fast spike-wave complex, always right hemispheric maximal (figure 1). Hyperventilation induced a brief period of behavioral arrest accompanying generalized EEG spike-wave activity. Interictal brain PET scan showed diffuse right hemispheric hypometabolism (figure 2). Blume¹ coined the term hemispheric epilepsy to denote a seizure syndrome in 13 patients from a database of more than 25,000. This rare condition emulates refractory idiopathic generalized epilepsy, with the exception of consistently asymmetric EEG epileptiform activity.

REFERENCE

1. Blume WT. Hemispheric epilepsy. *Brain* 1998;121:1937–1949.

Neurology[®]

Teaching *NeuroImages*: Hemispheric epilepsy

Giridhar P. Kalamangalam and Prasuna Velur

Neurology 2012;79:e111

DOI 10.1212/WNL.0b013e31826c1b8b

This information is current as of September 24, 2012

Updated Information & Services	including high resolution figures, can be found at: http://n.neurology.org/content/79/13/e111.full
References	This article cites 1 articles, 0 of which you can access for free at: http://n.neurology.org/content/79/13/e111.full#ref-list-1
Subspecialty Collections	This article, along with others on similar topics, appears in the following collection(s): All Epilepsy/Seizures http://n.neurology.org/cgi/collection/all_epilepsy_seizures EEG http://n.neurology.org/cgi/collection/eeg_ EEG; see Epilepsy/Seizures http://n.neurology.org/cgi/collection/eeg_see_epilepsy-seizures Generalized seizures http://n.neurology.org/cgi/collection/generalized_seizures PET in epilepsy http://n.neurology.org/cgi/collection/pet_in_epilepsy
Permissions & Licensing	Information about reproducing this article in parts (figures, tables) or in its entirety can be found online at: http://www.neurology.org/about/about_the_journal#permissions
Reprints	Information about ordering reprints can be found online: http://n.neurology.org/subscribers/advertise

Neurology® is the official journal of the American Academy of Neurology. Published continuously since 1951, it is now a weekly with 48 issues per year. Copyright © 2012 by AAN Enterprises, Inc.. All rights reserved. Print ISSN: 0028-3878. Online ISSN: 1526-632X.

