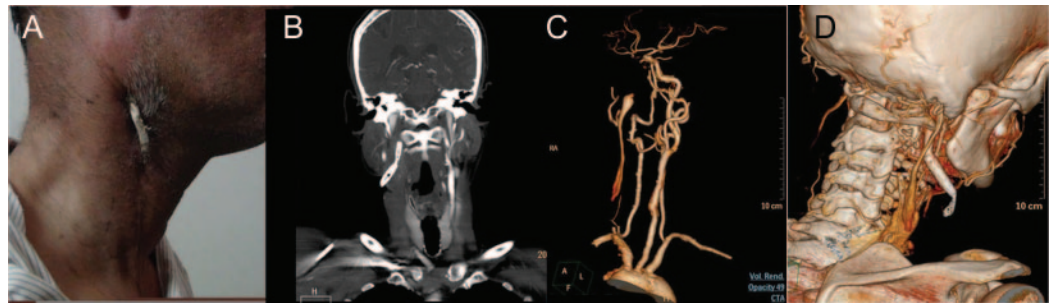


Extrusion of stent graft from the carotid artery

A major pain in the neck

Figure Imaging



(A) Photograph of patient shows stent extrusion outside neck. (B) CT coronal maximum intensity projection images show displaced stent with 1 end within the internal carotid artery and other projecting through the soft tissues of the neck to the exterior. (C) Volume rendered image demonstrates the displaced stent. (D) CT angiography (volume rendering technique) shows complete occlusion of right common carotid artery, internal carotid artery, and external carotid artery. Also seen is the displaced stent with 1 end in internal carotid artery.

A stent graft was deployed to treat a postcarotid endarterectomy pseudoaneurysm in a 52-year-old man. One and a half years later, he developed asymptomatic extrusion of the stent graft. CT angiography showed stent extrusion with occlusion of the right carotid artery (figure). The stent was explanted uneventfully. Stent extrusion is very rare.¹ Reasons for stent extrusion include stent undersizing, ongoing pseudoaneurysm expansion, or carotid blowout at the time of stent deployment.

Boby Varkey Maramattom, MD, DM, Bright Thomas, DMRD, DNBE, Vimal Iype, MS, DNBE, Kochi, Kerala, India

The authors report no disclosures relevant to the manuscript. **Go to Neurology.org for full disclosures.**

Correspondence & reprint requests to Dr. Maramattom: bobvarkey@gmail.com

1. Braulio R, Gelape CL, Brasileiro Filho G, Moreira MCV. Cardiomiopatia isquêmica terminal associada à complicação do uso de stent no tratamento de infarto agudo do miocárdio. *Rev Bras Cir Cardiovasc* 2011;26:481–484.

Neurology®

Extrusion of stent graft from the carotid artery: A major pain in the neck

Boby Varkey Maramattom, Bright Thomas and Vimal Iype

Neurology 2012;79;1186

DOI 10.1212/WNL.0b013e3182698d7c

This information is current as of September 10, 2012

Updated Information & Services	including high resolution figures, can be found at: http://n.neurology.org/content/79/11/1186.full
References	This article cites 1 articles, 0 of which you can access for free at: http://n.neurology.org/content/79/11/1186.full#ref-list-1
Subspecialty Collections	This article, along with others on similar topics, appears in the following collection(s): All Cerebrovascular disease/Stroke http://n.neurology.org/cgi/collection/all_cerebrovascular_disease_stroke
Permissions & Licensing	Information about reproducing this article in parts (figures, tables) or in its entirety can be found online at: http://www.neurology.org/about/about_the_journal#permissions
Reprints	Information about ordering reprints can be found online: http://n.neurology.org/subscribers/advertise

Neurology® is the official journal of the American Academy of Neurology. Published continuously since 1951, it is now a weekly with 48 issues per year. Copyright © 2012 by AAN Enterprises, Inc.. All rights reserved. Print ISSN: 0028-3878. Online ISSN: 1526-632X.

