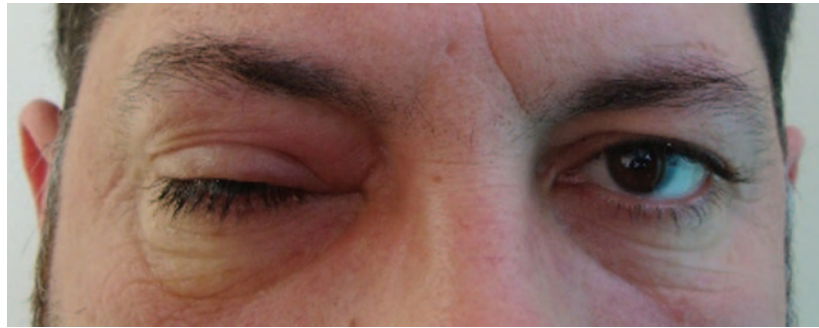

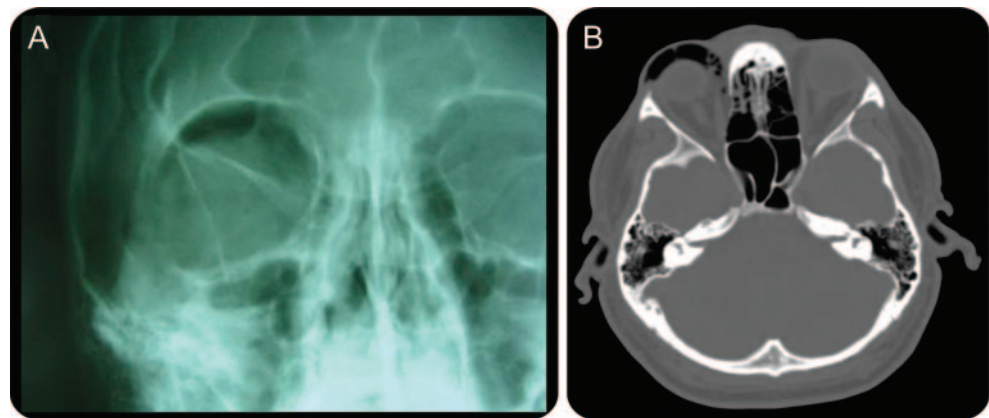
Orbital emphysema after nose blowing

Figure 1 Right eyelid emphysema



A 36-year-old man, a heavy smoker with chronic allergic rhinitis, awoke with a blocked nose. When blowing the left nostril, keeping the right one blocked, there was sudden pain over his right eye with ptosis (figure 1). Palpation over the right eyelid revealed crepitations; X-ray and CT scan (figure 2, A and B) showed air over the medial wall of the right orbit. Orbital emphysema may be due to injury.¹ Similar cases with spontaneous recovery have been reported.² We advised him not to blow his nose vigorously and to use physiologic water for nasal rinsing, followed by nasal decongestant. The ptosis resolved in 2 weeks.

Figure 2 Imaging



(A) X-ray showing air over the right eyelid. (B) CT scan showing pneumatized upper lid and a very thin layer of the right orbit medial wall.

Ridvan Alimehmeti, MD, PhD, Artan Gjika, MD, Jera Kruja, MD, PhD, Tirana, Albania

Disclosure: The authors report no disclosures.

Address correspondence and reprint requests to Dr. Jera Kruja, University Neurology Service, UHC Mother Theresa, Dibra St 372, Tirana, Albania; jkruja@gmail.com

1. Taguchi Y, Sakakibara Y, Uchida K, Kishi H. Orbital emphysema following nose blowing as a sequel of a snowboard related head injury. *Br J Sports Med* 2004;38:E28.
2. Sever M, Büyükyılmaz T. Orbital emphysema due to nose blowing. *Turk J Med Sci* 2009;39:143–145.

Neurology[®]

Orbital emphysema after nose blowing

Ridvan Alimehmeti, Artan Gjika and Jera Kruja

Neurology 2011;76;1274

DOI 10.1212/WNL.0b013e3182143523

This information is current as of April 4, 2011

Updated Information & Services	including high resolution figures, can be found at: http://n.neurology.org/content/76/14/1274.full
References	This article cites 2 articles, 0 of which you can access for free at: http://n.neurology.org/content/76/14/1274.full#ref-list-1
Subspecialty Collections	This article, along with others on similar topics, appears in the following collection(s): CT http://n.neurology.org/cgi/collection/ct
Permissions & Licensing	Information about reproducing this article in parts (figures, tables) or in its entirety can be found online at: http://www.neurology.org/about/about_the_journal#permissions
Reprints	Information about ordering reprints can be found online: http://n.neurology.org/subscribers/advertise

Neurology® is the official journal of the American Academy of Neurology. Published continuously since 1951, it is now a weekly with 48 issues per year. Copyright © 2011 by AAN Enterprises, Inc.. All rights reserved. Print ISSN: 0028-3878. Online ISSN: 1526-632X.

