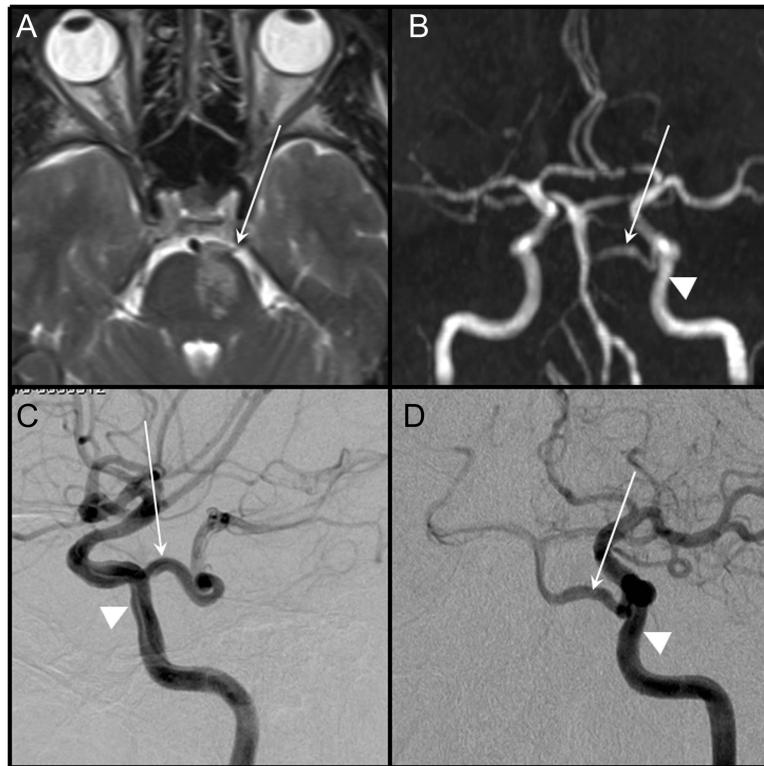


# A case of primitive trigeminal artery infarction



White arrow points to the primitive trigeminal artery (A–D). MRI, fluid-attenuated inversion recovery sequence, demonstrating the left ventral pontine infarction (A). Magnetic resonance angiography demonstrates proximal hypoplastic-stenotic vertebrobasilar system (B). Selective left internal carotid artery angiogram: lateral (C) and anteroposterior view (D) (same viewing angle as in B). Triangular arrowhead points to the left internal carotid artery (B–D).

Within minutes following an altercation with police, a 55-year-old man noted onset of speech difficulty and right-sided weakness without headache or neck pain. Dysarthria and right hemiparesis (grade 4/5) without ocular disturbance was found. Left ventral hemipontine infarction was documented from the ipsilateral tortuous primitive trigeminal artery (figure). Cerebral angiogram failed to reveal underlying arterial dissection.

Persistent anastomosis from a cavernous portion of internal cerebral artery to rostral basilar artery is unusual, with an estimated incidence of 0.2%.<sup>1</sup> Although the artery has been implicated as a conduit of a carotid artery to posterior cerebral artery distribution embolic stroke,<sup>2</sup> our case illustrates that localized occlusive process may also occur.

*Suichi Suzuki, MD, PhD, Gregory Youngnam Chang, MD, FAAN*

*From the Department of Radiology (S.S.), University of California at Irvine Medical Center, Irvine; and Department of Neurology (G.Y.C.), Barrow Neurological Institute, Phoenix, AZ.*

*Disclosure:* The authors report no disclosures.

*Address correspondence and reprint requests to Dr. Gregory Y. Chang, Barrow Neurological Institute, 500 W. Thomas Road, Suite 300, Phoenix, AZ 85013; gychang@yahoo.com*

*Received June 17, 2010. Accepted in final form August 30, 2010.*

1. Luh GY, Dean BL, Tomsick TA, Wallace RC. The persistent fetal carotid–vertebrobasilar anastomoses. *AJR Am J Roentgenol* 1999;172:1427–1432.
2. Gasecki AP, Fox AJ, Lebrun LH, et al. Bilateral occipital infarctions associated with carotid stenosis in a patient with persistent trigeminal artery: The Collaborators of the North American Carotid Endarterectomy Trial (NASCET). *Stroke* 1994;25:1520–1523.

# Neurology<sup>®</sup>

## **A case of primitive trigeminal artery infarction**

Suichi Suzuki and Gregory Youngnam Chang

*Neurology* 2010;75;S66

DOI 10.1212/WNL.0b013e3181fb3604

**This information is current as of November 1, 2010**

<b>Updated Information &amp; Services</b>	including high resolution figures, can be found at: <a href="http://n.neurology.org/content/75/18_Supplement_1/S66.full">http://n.neurology.org/content/75/18_Supplement_1/S66.full</a>
<b>References</b>	This article cites 2 articles, 1 of which you can access for free at: <a href="http://n.neurology.org/content/75/18_Supplement_1/S66.full#ref-list-1">http://n.neurology.org/content/75/18_Supplement_1/S66.full#ref-list-1</a>
<b>Subspecialty Collections</b>	This article, along with others on similar topics, appears in the following collection(s): <b>All Cerebrovascular disease/Stroke</b> <a href="http://n.neurology.org/cgi/collection/all_cerebrovascular_disease_stroke">http://n.neurology.org/cgi/collection/all_cerebrovascular_disease_stroke</a> <b>Infarction</b> <a href="http://n.neurology.org/cgi/collection/infarction">http://n.neurology.org/cgi/collection/infarction</a> <b>MRI</b> <a href="http://n.neurology.org/cgi/collection/mri">http://n.neurology.org/cgi/collection/mri</a>
<b>Permissions &amp; Licensing</b>	Information about reproducing this article in parts (figures, tables) or in its entirety can be found online at: <a href="http://www.neurology.org/about/about_the_journal#permissions">http://www.neurology.org/about/about_the_journal#permissions</a>
<b>Reprints</b>	Information about ordering reprints can be found online: <a href="http://n.neurology.org/subscribers/advertise">http://n.neurology.org/subscribers/advertise</a>

*Neurology*® is the official journal of the American Academy of Neurology. Published continuously since 1951, it is now a weekly with 48 issues per year. Copyright © 2010 by AAN Enterprises, Inc.. All rights reserved. Print ISSN: 0028-3878. Online ISSN: 1526-632X.

