

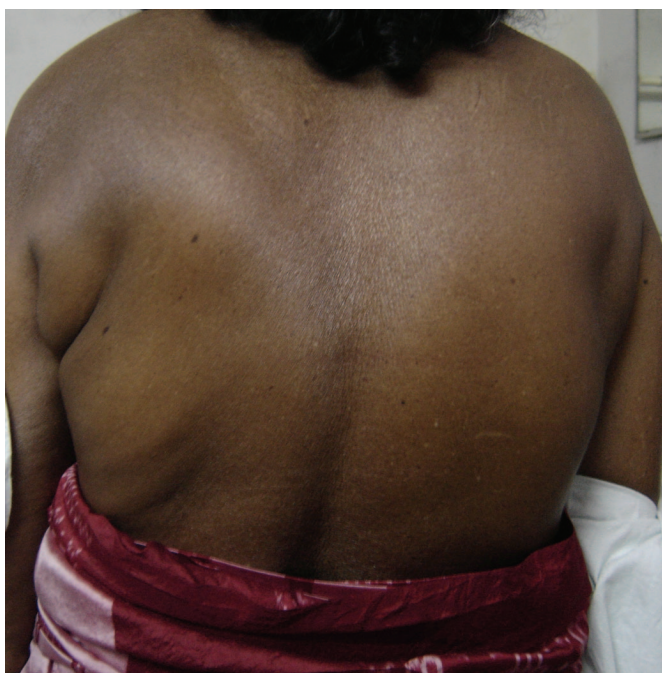

Figure 1. Contraction of the left latissimus dorsi muscle producing an accessory posterior axillary fold.

VIDEO

Postirradiation localized cramp-fasciculation syndrome

Boby Varkey Maramattom, MD, DM; and
Santhosh John Abraham, MS, FRCS, Kerala, South India

Radiation plexopathy produces numbness, weakness, and reflex changes.¹ Excess motor unit activity (EMUA) after irradiation manifests as myokymia and neuromyotonia in affected muscles.^{2,3} A 65-year-old woman presented with a pulling sensation in the left axilla and intermittent depression of the left arm of 3 to 4 months duration. Ten months earlier she had completed chemo-

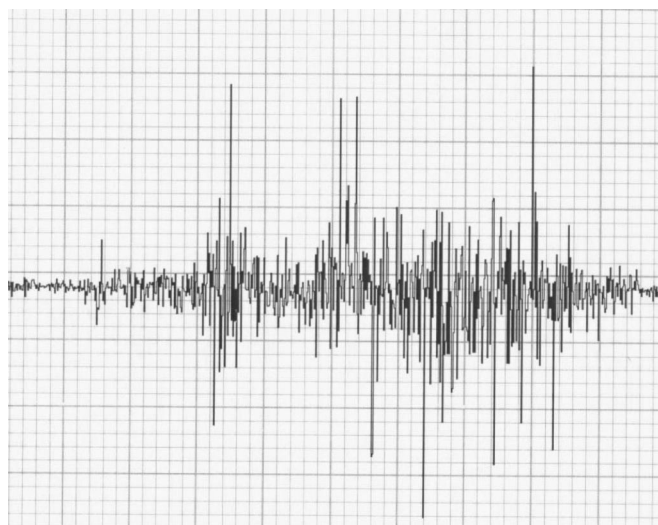


Figure 2. EMG showing cramp discharges. Sweep 500 msec/div, sensitivity 50 μ v/div. The accompanying video shows intermittent contraction of the left latissimus dorsi muscle and an accessory posterior axillary fold.

therapy and radiation therapy after a simple mastectomy for breast carcinoma 3 years earlier. On examination, frequent (2 to 3 per minute) intermittent rhythmic contractions of the left latissimus dorsi and pectoralis major muscles were seen (figure 1) (see also accompanying video). The duration of contractions ranged from 3 to 60 seconds during which her left arm was adducted and depressed and an accessory posterior axillary fold was created. No fasciculations or myokymia were observed. Nerve conduction studies showed conduction blocks in the left median and ulnar nerves across Erb's point. Needle EMG demonstrated rhythmic cramp discharges and occasional fasciculation potentials in the left latissimus dorsi, teres major, and pectoralis major muscles (figure 2). No myokymic, neuromyotonic, or fibrillation potentials were seen. MRI of the brachial plexus and cervical spinal cord were normal. The lack of pain, conduction blocks on nerve conduction study,¹ and cramp-fasciculation potentials in muscles within the radiation field suggested a diagnosis of post irradiation rhythmic muscle cramp-fasciculation disorder.

Disclosure: The authors report no conflicts of interest.

Address correspondence and reprint requests to Dr. Bobby Varkey Maramattom, Department of Neurology, Lourdes Hospital, Kochi, Kerala, South India; e-mail: bobvarkeys@yahoo.com

1. Jaekle KA. Neurological manifestations of neoplastic and radiation-induced plexopathies. *Semin Neurol* 2004;24:385-393.
2. Albers JW, Allen AA, Bastron JA, Daube JR. Limb myokymia. *Muscle Nerve* 1981;4:494-504.
3. Gutmann L. AAEM minimonograph #37. Facial and Limb myokymia. *Muscle Nerve* 1991;14:1043-1049.

Neurology[®]

Postirradiation localized cramp-fasciculation syndrome

Boby Varkey Maramattom and Santhosh John Abraham

Neurology 2006;67;E2

DOI 10.1212/01.wnl.0000218167.67121.e9

This information is current as of July 24, 2006

Updated Information & Services	including high resolution figures, can be found at: http://n.neurology.org/content/67/2/E2.full
Supplementary Material	Supplementary material can be found at: http://n.neurology.org/content/suppl/2006/07/19/67.2.E2.DC1
References	This article cites 3 articles, 0 of which you can access for free at: http://n.neurology.org/content/67/2/E2.full#ref-list-1
Subspecialty Collections	This article, along with others on similar topics, appears in the following collection(s): Anterior nerve cell disease http://n.neurology.org/cgi/collection/anterior_nerve_cell_disease Radiation therapy-tumor http://n.neurology.org/cgi/collection/radiation_therapytumor
Permissions & Licensing	Information about reproducing this article in parts (figures, tables) or in its entirety can be found online at: http://www.neurology.org/about/about_the_journal#permissions
Reprints	Information about ordering reprints can be found online: http://n.neurology.org/subscribers/advertise

Neurology® is the official journal of the American Academy of Neurology. Published continuously since 1951, it is now a weekly with 48 issues per year. Copyright . All rights reserved. Print ISSN: 0028-3878. Online ISSN: 1526-632X.

