

## Functional integration of periventricular neurons in periventricular nodular heterotopia

Lange et al. described a new filamin A mutation in a patient with periventricular nodular heterotopia. Their fMRI data indicated that ectopic neurons were functionally required in motor execution tasks.

see page 151

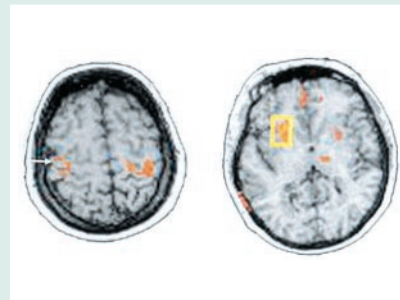
## Do heterotopic neurons think?

Commentary by Renzo Guerrini, MD

Heterotopia agglomerates of morphologically normal neurons in an abnormal site is the most common neuronal migration disorder observed in the human brain. Heterotopia can be unilateral or bilateral, diffuse or localized, subependymal or subcortical, or may extend from the subependymal region to the subcortex. Heterotopia can readily be diagnosed with MRI, showing the same signal as the normal cortex at every impulse sequence used. Although many patients with heterotopia come to medical attention because they have epileptic seizures without additional neurologic abnormalities, the spectrum of clinical presentations is wide. Usually, but not necessarily, there is some correlation between the extent of the heterotopic gray matter, the degree of cortical involvement, and the severity of clinical impairment. However, the degree of anatomic and functional impairment of the cerebral cortex overlying the area(s) of heterotopia is variable and may in turn determine the clinical picture. Early FDG-PET imaging studies had shown that heterotopia has the same metabolic activity as normal gray matter. Depth electrode studies showed that either the heterotopic cortex or the overlying cerebral

cortex, or both, can be epileptogenic.<sup>1</sup> Indeed, in patients with heterotopia and intractable temporal lobe type seizures, temporal lobectomies sparing deep heterotopic nodules were unsuccessful,<sup>2</sup> raising the suspicion that not just the epileptogenic zone but also the symptomatogenic zone might correspond to the heterotopic tissue. Previous functional MRI studies showed that subcortical band heterotopia (or double cortex), a malformation usually caused by mutations of the *DCX* gene, may be functionally active during simple sensorimotor tasks. This is not entirely surprising as in this malformation heterotopic neurons, after having partially migrated, settle close to the true cortex, from which they are separated by a thin layer of white matter and assemble in a pattern suggestive of laminar organization.<sup>3</sup>

The findings of Lange et al., using fMRI and showing that periventricular heterotopia may also be functionally integrated in motor circuits, are of remarkable interest in that in this migration disorder, often caused by mutations of the *FLN1* gene, heterotopic neurons have not migrated at all and lie in the subependymal zone, far away from the true cortex. Therefore, neurons carrying the mutated allele have lost their abil-



ity to migrate but have maintained the information that allows them to assemble in functionally active aggregates and to participate in integrated networks.

The practical implications are obvious. When considering surgical treatment of epilepsy, heterotopia, even when remote from the cortex, cannot be considered as just indolent tissue. It may have normal function as well as generate epileptic activity.

### References

1. Guerrini R, Carrozzo R. Epilepsy and genetic malformations of the cerebral cortex. *Am J Med Genet* 2001;106:160–173.
2. Li LM, Dubeau F, Andermann F, et al. Periventricular nodular heterotopia and intractable temporal lobe epilepsy: poor outcome after temporal lobe resection. *Ann Neurol* 1997;41:662–668.
3. Harding B. Gray matter heterotopia. In: Guerrini R, Andermann F, Canapicchi R, Roger J, Zifkin BG, Pfanner P. *Dysplasias of cerebral cortex and epilepsy*. Philadelphia: Lippincott-Raven, 1996;81-88.

see page 151

# Neurology<sup>®</sup>

**January 13 Highlight and Commentary**

*Neurology* 2004;62;1  
DOI 10.1212/WNL.62.1.1

**This information is current as of January 12, 2004**

|   |   |
|---|---|
| <b>Updated Information &amp; Services</b> | including high resolution figures, can be found at:<br><a href="http://n.neurology.org/content/62/1/1.full">http://n.neurology.org/content/62/1/1.full</a>  |
| <b>References</b>                         | This article cites 2 articles, 0 of which you can access for free at:<br><a href="http://n.neurology.org/content/62/1/1.full#ref-list-1">http://n.neurology.org/content/62/1/1.full#ref-list-1</a>  |
| <b>Citations</b>                          | This article has been cited by 2 HighWire-hosted articles:<br><a href="http://n.neurology.org/content/62/1/1.full##otherarticles">http://n.neurology.org/content/62/1/1.full##otherarticles</a>   |
| <b>Permissions &amp; Licensing</b>        | Information about reproducing this article in parts (figures, tables) or in its entirety can be found online at:<br><a href="http://www.neurology.org/about/about_the_journal#permissions">http://www.neurology.org/about/about_the_journal#permissions</a> |
| <b>Reprints</b>                           | Information about ordering reprints can be found online:<br><a href="http://n.neurology.org/subscribers/advertise">http://n.neurology.org/subscribers/advertise</a>   |

*Neurology*® is the official journal of the American Academy of Neurology. Published continuously since 1951, it is now a weekly with 48 issues per year. Copyright . All rights reserved. Print ISSN: 0028-3878. Online ISSN: 1526-632X.

