

# Child Neurology: Reversible Dementia in an 18-Year-Old Woman Due to Undiagnosed Cobalamin-G Deficiency

## A Case Report

Anthony M. Gacita, MD, PhD, Alma Bicknese, MD, Katherine Kim, MS, Frank Zelko, PhD, and Joshua Baker, DO  
*Neurology*® 2023;101:e215-e219. doi:10.1212/WNL.0000000000207146

### Correspondence

Dr. Baker  
jobaker@luriechildrens.org

## Abstract

Cobalamin-G deficiency is an inborn error of metabolism which disrupts the biochemical utilization of vitamin B12 to convert homocysteine to methionine in the remethylation pathway. Typically, affected patients present within the first year of life with anemia, developmental delay, and metabolic crisis. Few case reports of cobalamin-G deficiency reference a later onset phenotype primarily defined by neuropsychiatric symptoms. We report an 18-year-old woman who presented with a 4-year history of progressively worsening dementia, encephalopathy, epilepsy, and regression of adaptive functioning, with an initially normal metabolic workup. Whole-exome sequencing identified variants in the *MTR* gene, suspicious for cobalamin-G deficiency. Additional biochemical testing after genetic testing supported this diagnosis. Since treatment with leucovorin, betaine, and B12 injections, we have seen a gradual return to normal cognitive function. This case report expands the phenotypic range of cobalamin-G deficiency and offers rationale for genetic and metabolic testing in cases of dementia in the second decade of life.

---

From the Department of Genetics, Genomics, and Metabolism (A.M.G., K.K., J.B.), Department of Neurology (A.B.), and Department of Psychiatry and Behavioral Health (F.Z.), Ann & Robert H. Lurie Children's Hospital of Chicago, IL.

Go to [Neurology.org/N](https://www.neurology.org/N) for full disclosures. Funding information and disclosures deemed relevant by the authors, if any, are provided at the end of the article.

The evaluation of adolescent-onset cognitive decline (dementia) is challenging because of the broad range of possible diagnoses. Possible etiologies include early-onset neurodegenerative disease, autoimmune or paraneoplastic encephalopathies, infectious syndromes, and neurogenetic/metabolic diseases.<sup>1</sup> In patients with early-onset dementia, the exact rate of genetic/metabolic diseases is unknown. One retrospective review estimates the prevalence of genetic/metabolic disease at 11%, with 18% of cases without a final diagnosis.<sup>2</sup> Therefore, genetic/metabolic disease represents an important contributor to early onset dementia and should be considered in any pediatric patient with cognitive decline.

Cobalamin (vitamin B12) is a cofactor for 2 important enzymes: methylmalonyl CoA mutase and methionine synthase. Cobalamin requires extensive metabolism before it can be used as a cofactor. There are currently 7 known genes with mutations that cause cobalamin deficiency, *cblA* through *cblG*. Generally, mutations in these genes lead to the classic features of cobalamin deficiency including megaloblastic anemia, homocystinuria, methylmalonic aciduria, and developmental delay. The metabolic phenotypes and clinical features associated with a particular gene are variably understood, with many gene mutations being too rare to fully define. The most common defect of cobalamin metabolism is associated with mutations in the *MMACHC* gene and is termed *cblC*.<sup>3</sup> Patients with *cblC* have either an early-onset severe disease with hypotonia and seizures or late-onset presentation with extrapyramidal signs, dementia, delirium, or psychosis.<sup>4</sup>

*CblG* deficiency is caused by defects in the *MTR* gene, which encodes methionine synthase. *CblG* deficiency is mainly associated with a perinatal/childhood presentation that includes megaloblastic anemia, developmental delay, and neurologic symptoms, including seizures, lethargy, and hypotonia. Metabolic analysis usually reveals homocystinuria and hypomethioninemia with normal methylmalonic acid, folate, and B12 levels.<sup>5-7</sup> Unlike *cblC*, there is not a well-defined genotype to phenotype correlation. There are rare reports of adult-onset *cblG* disease with predominantly neuropsychiatric symptoms. One report describes a patient with neurologic symptoms and a macrocytic anemia that started at 21 years of age.<sup>8</sup> Developmental history was not consistent with the classic infantile or childhood presentation. Another report details a 34-year-old patient with a known *cblG* mutation who presented with psychiatric symptoms after months of medication nonadherence.<sup>9</sup> These reports suggest that the phenotype associated with *cblG* deficiency is not fully defined and may have a broad phenotypic range.

## Case Report

We present an 18-year-old woman with a history of developmental delay without intellectual disability who presented with a seizure followed by progressively worsening dementia, encephalopathy, and regression of adaptive functioning. She had a history of developmental delay including not walking

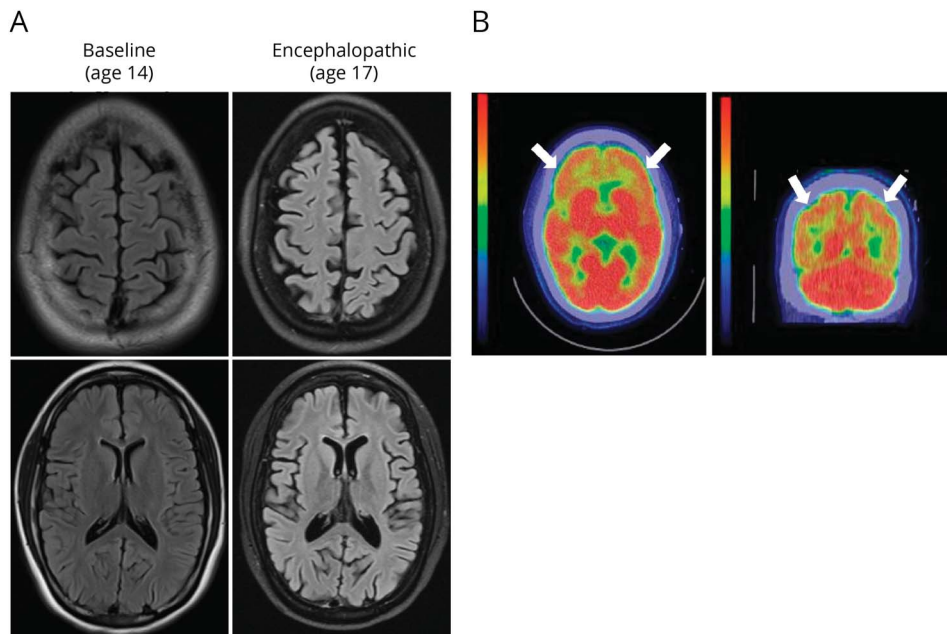
until around 18 months and said her first word at age 3. Although her early development was delayed, she caught up with developmental therapies, and at age 4, she was at the level of her peers. At age 14, she presented with a seizure described as generalized shaking while on vacation in Thailand. She was admitted to a local hospital where a brain MRI was nondiagnostic. She was diagnosed with epilepsy and started on Keppra. On returning to the United States, an EEG demonstrated bursts of spike and slow-wave discharges originating from the left frontal area, so she was continued on Keppra. A brain MRI obtained at the time was also normal (Figure, A). Once she remained seizure-free for about 2 years, her Keppra was stopped without seizure recurrence. During this time, her mother reported that the patient had difficulty with concentration and trouble finishing tasks. Her mother also noted deteriorating academic performance raising concern for a learning disability. Neuropsychologic testing revealed an IQ of 93 and achievement test scores in the high average range.

At age 16, she presented with 3 weeks of word-finding difficulties, decreased speech production, and impaired attention prompting hospitalization. Video EEG showed moderately disorganized background with slow posterior-dominant rhythm (PDR) of 7–8 Hz. She had frequent generalized rhythmic delta activity, rare focal frontal epileptic discharges, but no clinical seizures. Slow PDR and rhythmic delta are nonspecific findings supportive of a generalized encephalopathy.<sup>10</sup> A comprehensive workup including a brain MRI and serum paraneoplastic/autoimmune encephalopathy panels were nondiagnostic. She was treated with steroids and IV immunoglobulin (IVIg) for presumed seronegative autoimmune encephalitis, with modest improvement in her mental status without fully returning to baseline. Repeat neuropsychologic testing at age 17 showed a substantial decline. Her IQ at that time was measured to be 57, a decline of nearly 2.5 standard deviations from her baseline (Table).

Given the severity of her symptoms and nondiagnostic workup, additional laboratory evaluation was sent as part of a neurodegeneration/dementia workup. Broad testing was ordered including very long chain fatty acid profile, lysosomal enzyme screen, organic acid screen, plasma amino acids, plasma acylcarnitines, lactic acid, thyroid function tests, and vitamin B12 levels. All tests returned nondiagnostic. Owing to severe nature of her presentation and diagnostic uncertainty, whole-exome sequencing was sent using samples from the patient and her mother.

Later that year while awaiting whole-exome sequencing results, the patient acutely declined and was admitted to the hospital after 5 days of altered mental status. Specifically, she was sleeping 16+ hours per day and had limited, unintelligible speech and had increasing difficulty with showering and dressing. She could answer some yes-no questions but was inconsistent in following simple commands. Neurologic examination revealed intact cranial nerves, normal muscle tone and strength, intact sensation, symmetric reflexes, and down

**Figure** Clinical Data Demonstrating Neurodegeneration



(A) Example axial slices of brain T2-fluid-attenuated inversion recovery MRI sequences at baseline (age 14) and during an encephalopathic episode (age 16). Images demonstrate progressive cortical and central atrophy consistent with neurodegeneration. (B) PET-CT imaging of brain performed with F-18 fluoro-2-deoxyglucose. Image demonstrates abnormal relatively symmetric hypometabolism in the bilateral frontoparietal (white arrows) and bilateral temporal regions (not shown).

going plantars. She needed assistance to rise, and her gait was slow and shuffling. Video EEG was obtained because of concern for nonconvulsive status epilepticus. EEG was non-specific with a mildly disorganized background without a discernible posterior dominant rhythm. There was excessive theta and delta activity in the frontal and temporal lobes. Isolated independent focal spikes were seen in the frontal and

temporal regions, which prompted treatment with Keppra. A brain MRI showed diffuse parenchymal loss compared with her initial MRI at age 14 suggesting progressive neurodegeneration (Figure, A). CT PET imaging showed abnormal relatively symmetric hypometabolism in the bilateral frontoparietal and bilateral temporal regions, with relative sparing of other brain regions (Figure, B). She was again empirically treated for autoimmune encephalitis with IVIg, which modestly improved her symptoms. She was discharged to acute inpatient rehabilitation.

**Table** Neuropsychologic Test Results at Baseline During an Encephalopathic Episode and After Initiating Treatment

Measure	T1 (age 14)	T2 (age 16)	T3 (age 18)
<b>Wechsler Intelligence Scales</b>			
FSIQ	93	57	94
Verbal index	89	66	90
Perceptual index	86	52	100
<b>Grooved pegboard</b>			
Right (dominant) hand	75	27	84
Left hand	55	<20	72
<b>Woodcock-Johnson achievement</b>			
Letter-word identification	90	80	95
Sentence reading fluency	104	<40	101
Math fluency	117	79	119

Abbreviation: FSIQ = full-scale IQ. For all values, population mean = 100, SD = 15 (higher scores are better).

One month later, the results of her whole-exome sequencing became available. The patient was found to have heterozygous nonsense and missense variants within the *MTR* gene. The nonsense variant, pV132X (c.349delG), was called likely pathogenic, and the missense variant, p.A886T (c.2656G>A), was called a variant of uncertain significance (VUS) per established American College of Medical Genetics and Genomics criteria. Her missense VUS is virtually absent from population databases. In silico analysis tools indicate that this variant likely affects protein function. Although these results did not confirm *cbtG* deficiency, they were highly suspicious because of their consistency with her clinical presentation. Repeat metabolic testing showed increased plasma homocysteine and increased CSF-5-methyltetrahydrofolate, confirming her diagnosis of *cbtG* deficiency.

She started leucovorin, betaine, and B12 injections. After 2 weeks of treatment, her mother reported that she seemed more alert and more responsive and was seizure-free. Five months after initiating treatment, she is attending community college classes and repeat neuropsychologic testing revealed

recovery to baseline with an IQ of 94 (Table). Repeat imaging has not been obtained. About a year after starting treatment, she was seizure-free with several normal EEGs. Her Keppra was discontinued without seizure recurrence. Successful therapy was started around 4 years after symptom onset. She gave consent to the authors to share her medical story, so others would benefit from her experience.

## Discussion

Our patient's genetic testing revealed a pathogenic variant and variant of uncertain significance in the *MTR* gene. Nonsense variants within *MTR* are known to cause *cbIG*.<sup>11</sup> This missense variant is located within the second B12 binding domain of the methionine synthase protein. In ClinVar, other missense variants within this domain have been called pathogenic. Given that only a maternal sample was sent for whole-exome sequencing, we could not confirm the phasing of our patient's 2 variants. However, given her consistent biochemical results, it is likely that these variants are in trans and result in biallelic alteration of methionine synthase function. This patient's relatively mild phenotype argues that the A996T allele does not result in a complete loss of function but reduces function to act as a hypomorphic allele.

The initial metabolic workup of this patient did not detect abnormalities pointing to *cbIG* deficiency, namely, homocystinuria and low methionine. One possibility is error in measuring homocysteine, which has been extensively described.<sup>12,13</sup> This patient's elevations in homocysteine may also be intermittent and influenced by external factors, such as diet, as has been demonstrated in classic homocystinuria.<sup>14</sup> The hypomorphic nature of her pathogenic alleles could also result in intermittent metabolic abnormalities. These findings may explain the low sensitivity of newborn screening programs that primarily measure methionine and homocysteine to detect defects in B12 metabolism.<sup>15</sup>

Genetic/metabolic defects are important causes of neurologic dysfunction in adolescents. Atypical, late-onset presentations have been reported for many metabolic disorders.<sup>16</sup> This case illustrates that standard plasma amino acid analysis is not sufficient to rule out metabolic disease. Genetic analysis is not susceptible to the same technical and biologic variation. Genome-wide genetic analysis can detect variants in metabolic genes, which can be tested for pathogenicity with targeted metabolic testing. This case highlights the complementary nature of molecular and metabolic testing and supports a hybrid approach with early genetic testing.

## Study Funding

No targeted funding reported.

## Disclosure

The authors have no relevant disclosures. Go to Neurology.org/N for full disclosures.

## Publication History

Received by *Neurology* August 24, 2022. Accepted in final form January 19, 2023. Submitted and externally peer reviewed. The handling editor was Resident and Fellow Deputy Editor Ariel Lyons-Warren, MD, PhD.

## Appendix Authors

Name	Location	Contribution
<b>Anthony M. Gacita, MD, PhD</b>	Department of Genetics, Genomics, and Metabolism, Ann & Robert H. Lurie Children's Hospital of Chicago, IL	Drafting/revision of the manuscript for content, including medical writing for content; major role in the acquisition of data; study concept or design; analysis or interpretation of data
<b>Alma Bicknese, MD</b>	Department Neurology, Ann & Robert H. Lurie Children's Hospital of Chicago, IL	Drafting/revision of the manuscript for content, including medical writing for content; major role in the acquisition of data
<b>Katherine Kim, MS</b>	Department of Genetics, Genomics, and Metabolism, Ann & Robert H. Lurie Children's Hospital of Chicago, IL	Drafting/revision of the manuscript for content, including medical writing for content; major role in the acquisition of data
<b>Frank Zelko, PhD</b>	Department Psychiatry and Behavioral Health, Ann & Robert H. Lurie Children's Hospital of Chicago, IL	Drafting/revision of the manuscript for content, including medical writing for content; major role in the acquisition of data; analysis or interpretation of data
<b>Joshua Baker, DO</b>	Department of Genetics, Genomics, and Metabolism, Ann & Robert H. Lurie Children's Hospital of Chicago, IL	Drafting/revision of the manuscript for content, including medical writing for content; analysis or interpretation of data

## References

1. Rossor MN, Fox NC, Mummery CJ, Schott JM, Warren JD. The diagnosis of young-onset dementia. *Lancet Neurol*. 2010;9(8):793-806. doi:10.1016/s1474-4422(10)70159-9.
2. Kelley BJ, Boeve BF, Josephs KA. Young-onset dementia: demographic and etiologic characteristics of 235 patients. *Arch Neurol*. 2008;65(11):1502-1508. doi:10.1001/archneur.65.11.1502.
3. Lerner-Ellis JP, Tirone JC, Pawelek PD, et al. Identification of the gene responsible for methylmalonic aciduria and homocystinuria, *cbIC* type. *Nat Genet*. 2006;38(1):93-100. doi:10.1038/ng1683.
4. Rosenblatt DS, Aspler AL, Shevell MI, Pletcher BA, Fenton WA, Seashore MR. Clinical heterogeneity and prognosis in combined methylmalonic aciduria and homocystinuria (*cbIC*). *J Inher Metab Dis*. 1997;20(4):528-538. doi:10.1023/a:1005353530303.
5. Hallam LJ, Sawyer M, Clark A, Van der Weyden M. Vitamin B12-responsive neonatal megaloblastic anemia and homocystinuria with associated reduced methionine synthase activity. *Blood*. 1987;69(4):1128-1133. doi:10.1182/blood.v69.4.1128.bloodjournal6941128.
6. Rosenblatt DS, Thomas IT, Watkins D, Cooper BA, Erbe RW, Reynolds JF. Vitamin B12 responsive homocystinuria and megaloblastic anemia: heterogeneity in methylcobalamin deficiency. *Am J Med Genet*. 1987;26(2):377-383. doi:10.1002/ajmg.1320260216.
7. Watkins D, Rosenblatt DS. Genetic heterogeneity among patients with methylcobalamin deficiency. Definition of two complementation groups, *cbIE* and *cbIG*. *J Clin Invest*. 1988;81(6):1690-1694. doi:10.1172/jci113507.
8. Carmel R, Watkins D, Goodman SI, Rosenblatt DS. Hereditary defect of cobalamin metabolism (*cbIG* mutation) presenting as a neurologic disorder in adulthood. *N Engl J Med*. 1988;318(26):1738-1741. doi:10.1056/nejm198806303182607.
9. Hill KP, Lukonis CJ, Korson MS, Weinstein C, Thall M, Schwartz JT. Neuropsychiatric illness in a patient with cobalamin G disease, an inherited disorder of vitamin B12 metabolism. *Harv Rev Psychiatry*. 2004;12(2):116-122. doi:10.1080/10673220490447227.

10. Britton JW, Frey LC, Hopp JL, et al. The abnormal EEG. In: St. Louis EK, Frey LC, editors. *Electroencephalography (EEG): An Introductory Text and Atlas of Normal and Abnormal Findings in Adults, Children, and Infants*. American Epilepsy Society; 2016.
11. Watkins D, Ru M, Hwang HY, et al. Hyperhomocysteinemia due to methionine synthase deficiency, cblG: structure of the MTR gene, genotype diversity, and recognition of a common mutation, P1173L. *Am J Hum Genet*. 2002;71(1):143-153. doi:10.1086/341354.
12. Peterschmitt MJ, Simmons JR, Levy HL. Reduction of false negative results in screening of newborns for homocystinuria. *N Engl J Med*. 1999;341(21):1572-1576. doi:10.1056/nejm199911183412103.
13. Rosenson RS, Tangney CC. Preanalytical sources of measurement error: the conundrum of the homocysteine hypothesis. *Atherosclerosis*. 2007;194(2):520. doi:10.1016/j.atherosclerosis.2006.10.002.
14. Walter JH, Jahnke N, Remington T. Newborn screening for homocystinuria. *Cochrane Database Syst Rev*. 2015;2015(10):CD008840. doi:10.1002/14651858.CD008840.pub4.
15. Huemer M, Kozich V, Rinaldo P, et al. Newborn screening for homocystinurias and methylation disorders: systematic review and proposed guidelines. *J Inherit Metab Dis*. 2015;38(6):1007-1019. doi:10.1007/s10545-015-9830-z.
16. Wolf B. "Think metabolic" in adults with diagnostic challenges: biotinidase deficiency as a paradigm disorder. *Neurol Clin Pract*. 2017;7(6):S18-S22. doi:10.1212/cpj.0000000000000379.



# Neurology®

## Child Neurology: Reversible Dementia in an 18-Year-Old Woman Due to Undiagnosed Cobalamin-G Deficiency: A Case Report

Anthony M. Gacita, Alma Bicknese, Katherine Kim, et al.

*Neurology* 2023;101:e215-e219 Published Online before print February 16, 2023

DOI 10.1212/WNL.0000000000207146

**This information is current as of February 16, 2023**

<b>Updated Information &amp; Services</b>	including high resolution figures, can be found at: <a href="http://n.neurology.org/content/101/2/e215.full">http://n.neurology.org/content/101/2/e215.full</a>
<b>References</b>	This article cites 15 articles, 2 of which you can access for free at: <a href="http://n.neurology.org/content/101/2/e215.full#ref-list-1">http://n.neurology.org/content/101/2/e215.full#ref-list-1</a>
<b>Subspecialty Collections</b>	This article, along with others on similar topics, appears in the following collection(s): <b>Adolescence</b> <a href="http://n.neurology.org/cgi/collection/adolescence">http://n.neurology.org/cgi/collection/adolescence</a> <b>All Cognitive Disorders/Dementia</b> <a href="http://n.neurology.org/cgi/collection/all_cognitive_disorders_dementia">http://n.neurology.org/cgi/collection/all_cognitive_disorders_dementia</a> <b>All Genetics</b> <a href="http://n.neurology.org/cgi/collection/all_genetics">http://n.neurology.org/cgi/collection/all_genetics</a>
<b>Permissions &amp; Licensing</b>	Information about reproducing this article in parts (figures, tables) or in its entirety can be found online at: <a href="http://www.neurology.org/about/about_the_journal#permissions">http://www.neurology.org/about/about_the_journal#permissions</a>
<b>Reprints</b>	Information about ordering reprints can be found online: <a href="http://n.neurology.org/subscribers/advertise">http://n.neurology.org/subscribers/advertise</a>

*Neurology*® is the official journal of the American Academy of Neurology. Published continuously since 1951, it is now a weekly with 48 issues per year. Copyright © 2023 American Academy of Neurology. All rights reserved. Print ISSN: 0028-3878. Online ISSN: 1526-632X.

