

# Pearls & Oy-sters: Sequential Bilateral Hearing and Vision Loss With Optic Disc Swelling Due to Sphenoid Bone Craniofacial Fibrous Dysplasia

Joel D. Handley, MBBCh, MSc, MRCP (UK), Sachin Mathur, MRCP, FRCR, and Suresh K. Chhetri, MBBS, MD, MRCP (Neurology), FHEA, FRCP

*Neurology*® 2023;100:439-443. doi:10.1212/WNL.0000000000201663

## Correspondence

Dr. Handley  
joelhandley@doctors.org.uk

## Abstract

Bilateral optic disc swelling is a common finding but rarely associated with multiple cranial neuropathies. In this case, an 18-year-old man presented with subacute sequential hearing loss followed by subacute sequential visual loss. Clinical examination revealed bilateral optic disc swelling. Lumbar puncture revealed a normal opening pressure of 15 cmH<sub>2</sub>O. This case discusses a rare but important cause of bilateral optic disc swelling in the context of hearing loss, disequilibrium, and a normal CSF opening pressure. An overview of the literature is provided, and treatment options are discussed to guide further management of similar cases.

## Pearls

- Craniofacial fibrous dysplasia may affect the skull base and present with multiple compressive cranial neuropathies.
- Papilledema with early visual loss is atypical and should raise concerns for superimposed optic neuropathy.
- Any vision, hearing, or vestibular changes with craniofacial fibrous dysplasia warrant an urgent evaluation to consider surgical intervention.
- Corticosteroids may be considered as an empirical treatment of craniofacial fibrous dysplasia with symptomatic cranial nerve compression if surgical decompression is not possible.

## Oy-sters

- A high level of suspicion and further review of the neuroimaging is needed when the clinical picture does not correlate with initial imaging reports.
- Bilateral optic disc swelling due to localized optic nerve compression within the optic canal will be associated with a normal CSF opening pressure.
- Bilateral visual and hearing loss in a young adult is often attributed to mitochondrial or toxic etiologies; however, symmetrical compressive cranial pathology must also be excluded.
- Extensive investigation is warranted for all cases of suspected idiopathic intracranial hypertension with any atypical features, including a normal CSF opening pressure, rapid visual deterioration, male sex, normal BMI, and absence of headache.

## Case Report

An 18-year-old man presented with a 3-month history of gradual left, then right-sided hearing loss with tinnitus and disequilibrium. Two months later, he noted progressive painless left, then right visual loss. There was no relevant family or medical history. Clinical examination revealed grade 3 optic disc swelling bilaterally. This was reported as increased retinal nerve fiber layer thickness due to papilledema on optical coherence tomography. The visual acuity was 0.52 logMAR (20/66) in the right eye and 1.08 logMAR (20/240) in the left eye. The Romberg test revealed a mild body sway, and the

From the Department of Neurology (JDH, SKC), Royal Preston Hospital, Lancashire Teaching Hospitals NHS Foundation Trust, Preston, UK; and Department of Neuroradiology (SM), Royal Preston Hospital, Lancashire Teaching Hospitals NHS Foundation Trust, Preston, UK.

Go to [Neurology.org/N](https://www.neurology.org/N) for full disclosures. Funding information and disclosures deemed relevant by the authors, if any, are provided at the end of the article.

Unterberger stepping test was positive, with notable deviation to the right. This helped localize symptoms to the vestibular system. Neurologic examination was otherwise normal. Audiogram confirmed bilateral predominantly sensorineural hearing loss (Figure 1A). Visual evoked potentials revealed bilateral prolongation of the P100 cortical potentials, more so on the left side (Figure 1C). These findings raised the suspicion of a pathology involving the second and eighth cranial nerves

Routine screening bloods were all unremarkable. These included ESR, CRP, complete blood count, and coagulation screen; liver, renal, and thyroid function tests; connective tissue disease screen, ANCA, and complement levels; serum electrophoresis; and HIV, syphilis, hepatitis, and Lyme serology. The pathology test to investigate for Neuro-Behçet disease was negative. Lumbar puncture revealed normal constituents and an opening pressure of 15 cmH<sub>2</sub>O.

An MRI brain with contrast was initially reported as symmetrical bilateral optic nerve atrophy with prominence of the perioptic CSF space. The report also commented on an incidental periodontal inflammatory process and prominent bilateral anterior clinoid processes. Genetic investigations were arranged to exclude a mitochondrial disorder given the subacute sequential bilateral hearing loss and visual impairment. Testing for Leber hereditary optic neuropathy, Kearns-Sayre syndrome, MELAS (Mitochondrial Encephalopathy, Lactic Acidosis, and Stroke-like episodes), and MERRF (myoclonic epilepsy with ragged red fibers) all returned negative.

An inflammatory optic papillitis was also considered. The patient received empirical pulsed intravenous, followed by oral steroids, and the visual acuity improved (Snellen: left 20/80 from 20/200, right 20/40 from 20/120). Further review of the MRI imaging with the clinical history revealed bilateral stenosis of the optic canals leading to CSF distension of the optic nerve sheaths and a clinical picture of papilledema with visual impairment. This was secondary to hyperostosis of the anterior clinoid process (Figure 2A). There was also stenosis of the internal auditory canals due to bony hyperostosis of the petrous temporal bones with compression of the seventh and eighth cranial nerves. A CT scan and subsequent a dedicated bone SPECT scan excluded any malignant process confirmed polyostotic fibrous dysplasia involving the skull, skull base, and mandible and also excluded any malignant process. Pituitary hormone function tests were all unremarkable. These included prolactin, growth hormone, IGF-1, cortisol, ACTH, LH, and FSH.

The patient underwent an urgent endoscopic bilateral optic nerve decompression. Visual acuity initially deteriorated significantly postoperatively despite highly satisfactory postoperative appearances on imaging. This was possibly due to postoperative swelling of the optic nerves resulting in a localized compartment syndrome in the remaining portion of the optic

canal. A prompt second endoscopic procedure was undertaken to remove the remaining portion of the sphenoid bone extending distally to the optic chiasm. Abdominal adipose tissue was then inserted at the site of decompression to prevent CSF leakage. The visual acuity 3 days after the second procedure was 1.26 logMAR (20/360) at 1 meter in the right eye and just hand motion, close to the face, in the left eye. The visual acuity 1 month (38 days) after the second procedure was 1.06 logMAR (20/230) in the right eye and 1.56 logMAR (20/720) in the left eye. A repeat audiogram after 32 days was reported as normal (Figure 1B). This suggested improvement in hearing with a combination of decompressive surgery and high-dose corticosteroids which were gradually tapered over the next 3 months.

## Discussion

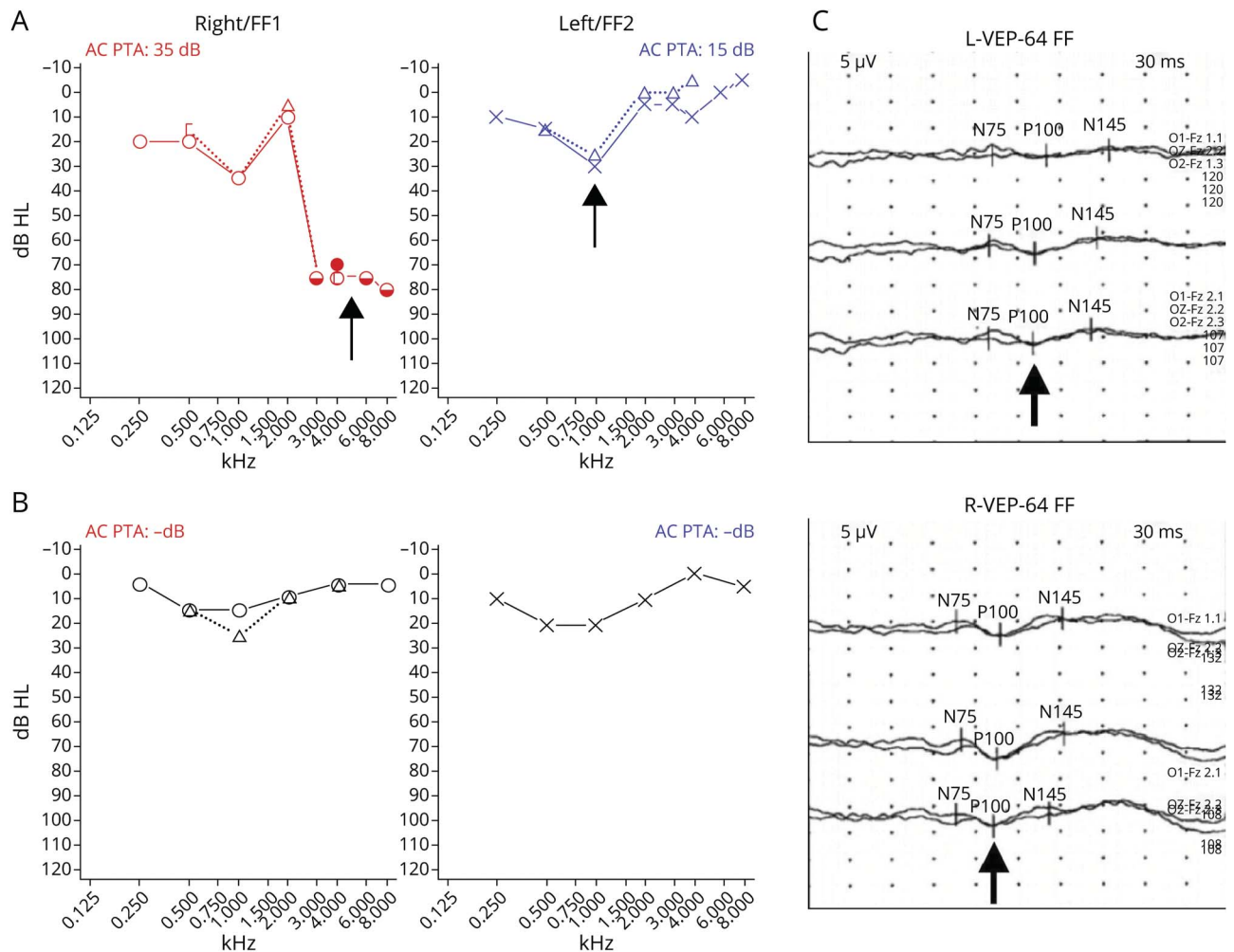
We present a rare case of craniofacial fibrous dysplasia causing bilateral hearing and visual loss with optic disc swelling which initially improved slightly with corticosteroids. We believe this to be the first case described in the literature of craniofacial fibrous dysplasia causing symptomatic bilateral compression of both the optic and vestibulocochlear cranial nerves. Fibrous dysplasia is a non-neoplastic congenital process resulting in the replacement of bone with an abnormal fibrous tissue. The condition can be monostotic or polyostotic, affecting either single or multiple bones, respectively. There is a clear predilection for the long bones, ribs, and craniofacial bones. Most lesions are usually incidental and monostotic, and asymptomatic, requiring only clinical observation and patient education.

At a molecular level, fibrous dysplasia is associated with an activating mutation in the *GNAS1* gene which is located at 20q13.2–13.3 and encodes for the alpha subunit of G protein (guanine nucleotide-binding protein).<sup>1</sup> G protein helps stimulate adenylate cyclase, which in turn regulates the production of various hormones and also the signaling pathway for osteogenesis. Interestingly, fibrous dysplasia is not inherited because the gene mutation invariably occurs after conception. Lesional tissue biopsy has the highest sensitivity (80%) in comparison with serum lymphocytes for PCR-based genetic diagnostic methods (20%–30%).<sup>2</sup>

Craniofacial dysplasia of the skull base has a wide variety of presentations including atypical facial pain, headache, sinus issues, proptosis, diplopia, strabismus, visual changes, hearing loss, and facial numbness.<sup>3</sup> Bisphosphonates have been trialed for pain reduction and to possibly slow the rate of growth, but further studies are required. Malignant transformation is very rare, and transformation to osteosarcoma and other sarcomas occurs in less than 1 percent of cases.<sup>4</sup>

A single-center case series of 10 patients with craniofacial fibrous dysplasia identified reduced visual acuity in 2 individuals, one with a coexisting contralateral vestibular

**Figure 1** Audiograms and Visual Evoked Potentials



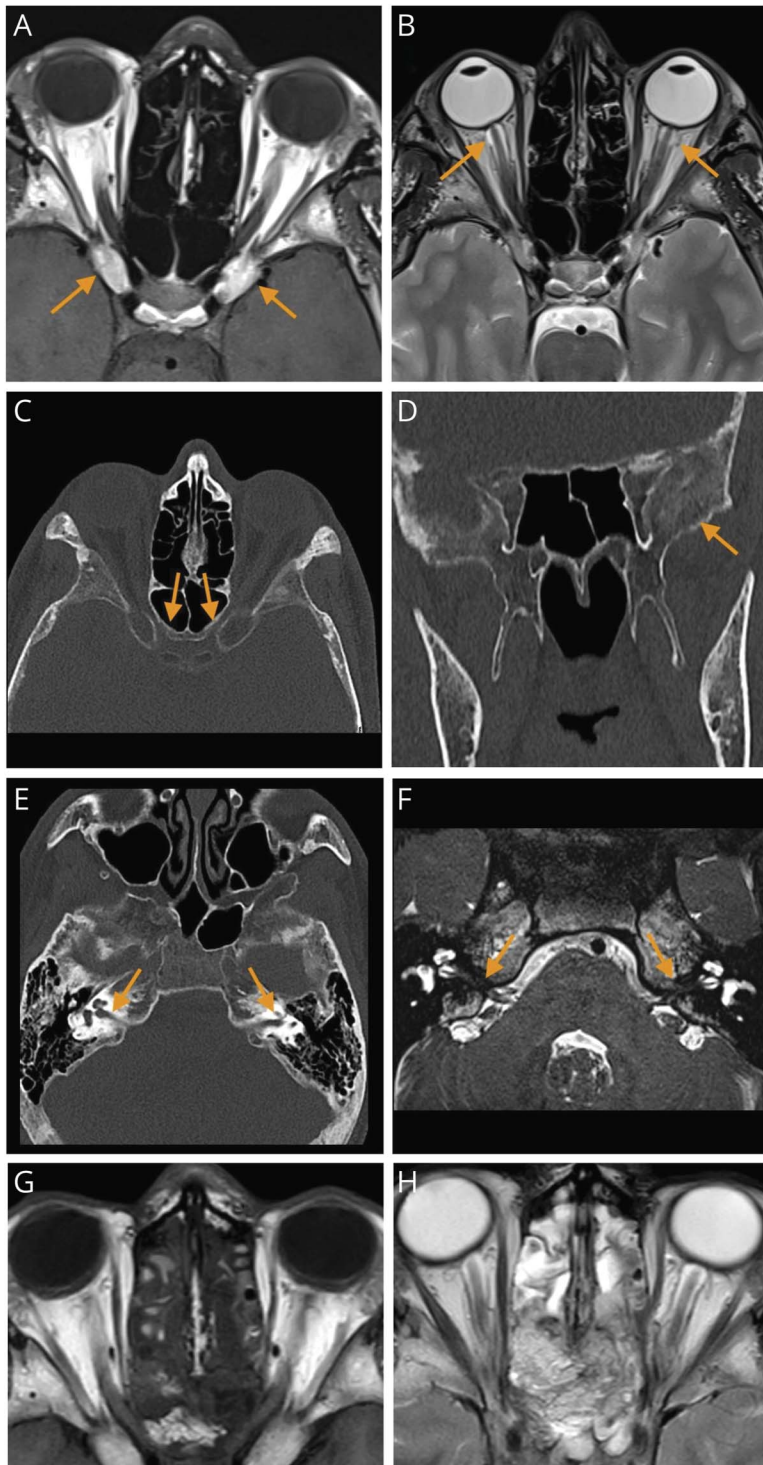
(A) Audiogram demonstrating sensorineural hearing loss at presentation. (B) Satisfactory audiogram 1 month (32 days) after the second procedure while still receiving corticosteroids. (C) Preoperative visual evoked potentials showing bilateral prolongation of the P100 cortical potentials, more so on the left side. Average P100 latencies were 165 ms on the left and 135 ms on the right.

syndrome, and the other with objective hearing loss.<sup>5</sup> A further review of 66 cases of fibrous dysplasia affecting the temporal bone identified the 2 most common presenting complaints to be headache (59%) and hearing loss (29%).<sup>6</sup> In another case series, 30 patients with fibrous dysplasia affecting the clivus presented with either headache or cranial nerve deficits; these manifested with a variety of symptoms including tinnitus, vertigo, disequilibrium, and diplopia.<sup>7</sup>

The clivus (Latin for slope) lies near the center of the brainstem and may be affected by a variety of cystic, neoplastic, meningeal, infective, traumatic, and dysplastic pathologies. Surgical approaches have previously relied on microsurgical transcranial techniques from the anterior, posterior, and lateral directions; however, endoscopic transnasal transclival approaches are becoming increasingly favored.<sup>8</sup> The management of symptomatic craniofacial

fibrous dysplasia is not established but decompressive surgery is often considered. A comprehensive meta-analysis of 241 patients with fibrous dysplasia with 86 clinically impaired optic nerves confirmed a postsurgical improvement in visual function in around two-thirds but a statistically significant postoperative visual deterioration for asymptomatic nerves.<sup>9</sup> This risk of deterioration was possibly attributed to an increased sensitivity of the already damaged optic nerve to surgical insult. Long-term follow-up of asymptomatic nerves encased with fibrous dysplasia has suggested a low risk of optic neuropathy, especially in the absence of growth hormone excess which is a statistically significant risk factor and may suggest a pathophysiologic relevance.<sup>10</sup>

Our case initially demonstrated a measurable improvement in visual acuity with corticosteroids. The only reported similar improvement involved a 22-year-old woman with



(A) Axial T1-weighted image showing hyperostosis of the anterior clinoid processes with bilateral optic canal stenosis. (B) Axial T2-weighted image showing bilateral CSF distension of the optic nerve sheaths with cupping of the optic nerve heads. The CSF distension only extends posteriorly up to the optic canals. (C) Axial CT Head with bony windows showing bilateral optic canal stenosis. (D) Coronal CT reconstruction showing bony hyperostosis with “ground glass” changes in the central skull base, typical of fibrous dysplasia. (E) Axial CT scan showing bilateral bony hyperostosis of the petrous temporal bones with stenosis of the internal auditory canals. (F) Heavily T2-weighted MRI scan of the internal auditory meatus showing bilateral compression of the seventh and eighth cranial nerves. (G) Postoperative axial T1-weighted and T2-weighted (H) images show bilateral decompression of the optic canals with persistent CSF distension of the optic nerve sheaths.

unilateral visual loss and optic neuropathy that initially improved with orbital decompression. A further recurrence of vision loss occurred in the absence of any radiologic changes 15 months later, then responded completely to a tapering dose of oral prednisolone. She was reported to remain well for 9 months after the discontinuation of steroids.<sup>11</sup> The exact mechanism for this sustained improvement remains

unknown. Corticosteroids may exert their effect by either slowing the proliferation of fibrous tissue or reducing any localized optic nerve edema. Review of our case and others in the literature highlights the risk of postsurgical deterioration. This could be mitigated by advocating for unilateral decompression of the most symptomatic nerve in the first instance. The role of empirical corticosteroids remains unclear,

but we would recommend considering their use as an emergency bridging strategy perioperatively or for lesions that are unamenable to surgery.

## Study Funding

The authors report no targeted funding.

## Disclosure

The authors report no relevant disclosures. Go to [Neurology.org/N](https://www.neurology.org/N) for full disclosures.

## Publication History

Received by *Neurology* July 26, 2022. Accepted in final form October 24, 2022. Submitted and externally peer reviewed. The handling editor was Whitley Aamodt, MD, MPH.

## Appendix Authors

Name	Location	Contribution
<b>Joel D. Handley, MBCh, MSc, MRCP (UK)</b>	Department of Neurology, Royal Preston Hospital, Lancashire Teaching Hospitals NHS Foundation Trust, Preston, UK	Drafting/revision of the manuscript for content, including medical writing for content; major role in the acquisition of data; study concept or design; analysis or interpretation of data
<b>Sachin Mathur, MRCP, FRCP</b>	Department of Neuroradiology, Royal Preston Hospital, Lancashire Teaching Hospitals NHS Foundation Trust, Preston, UK	Major role in the acquisition of data

## Appendix (continued)

Name	Location	Contribution
<b>Suresh K. Chhetri, MBBS, MD, MRCP (Neurology), FHEA, FRCP</b>	Department of Neurology, Royal Preston Hospital, Lancashire Teaching Hospitals NHS Foundation Trust, Preston, UK	Drafting/revision of the manuscript for content, including medical writing for content

## References

1. DiCaprio MR, Enneking WF. Fibrous dysplasia. Pathophysiology, evaluation, and treatment. *J Bone Joint Surg Am* 2005;87(8):1848-1864. doi: 10.2106/JBJS.D.02942
2. Boyce AM, Florenzano P, de Castro LF, Collins MT. Fibrous dysplasia/McCune-Albright syndrome. In: Adam MP, Ardinger HH, Pagon RA, et al, editors. *GeneReviews*® [Internet]. University of Washington; 2019:1993-2022.
3. Lustig LR, Holliday MJ, McCarthy EF, Nager GT. Fibrous dysplasia involving the skull base and temporal bone. *Arch Otolaryngol Head Neck Surg*. 2001;127(10):1239-1247. doi: 10.1001/archotol.127.10.1239
4. Lee J, FitzGibbon E, Chen Y, et al. Clinical guidelines for the management of craniofacial fibrous dysplasia. *Orphanet J Rare Dis*. 2012;S2:7. doi: 10.1186/1750-1172-7-S1-S2
5. Couturier A, Aumaitre O, Gilain L, Jean B, Mom T, André M. Craniofacial fibrous dysplasia: a 10-case series. *Eur Ann Otorhinolaryngol Head Neck Dis*. 2017;134(4):229-235. doi: 10.1016/j.janorl.2017.02.004
6. Frisch CD, Carlson ML, Kahue CN, et al. Fibrous dysplasia of the temporal bone: a review of 66 cases. *Laryngoscope* 2015;125(6):1438-1443. doi: 10.1002/lary.25078
7. Heman-Ackah SE, Boyer H, Odland R. Clival fibrous dysplasia: case series and review of the literature. *Ear Nose Throat J*. 2014;93(12):E4-E9. doi: 10.1177/014556131409301202
8. Pagella F, Ugolini S, Zoia C, et al. Clivus pathologies from diagnosis to surgical multidisciplinary treatment. Review of the literature. *Acta Otorhinolaryngol Ital*. 2021;41(S1):S42-S50. doi: 10.14639/0392-100X-suppl.1-41-2021-04
9. Amit M, Collins MT, FitzGibbon EJ, Butman JA, Fliss DM, Gil Z. Surgery versus watchful waiting in patients with craniofacial fibrous dysplasia—a meta-analysis. *PLoS One* 2011;6(9):e25179. doi: 10.1371/journal.pone.0025179
10. Cutler CM, Lee JS, Butman JA, et al. Long-term outcome of optic nerve encasement and optic nerve decompression in patients with fibrous dysplasia: risk factors for blindness and safety of observation. *Neurosurgery* 2006;59(5):1011-1017. doi: 10.1227/01.NEU.0000254440.02736.E3
11. Arroyo JG, Lessell S, Montgomery WW. Steroid-induced visual recovery in fibrous dysplasia. *J Clin Neuroophthalmol* 1991;11(4):259-261.

## The *Neurology*® Null Hypothesis Online Collection...

### Contributing to a transparent research reporting culture!



The *Neurology* journals have partnered with the Center for Biomedical Research Transparency (CBMRT) to promote and facilitate transparent reporting of biomedical research by ensuring that all biomedical results—including negative and inconclusive results—are accessible to researchers and clinicians in the interests of full transparency and research efficiency.

*Neurology's* Null Hypothesis Collection is a dedicated online section for well conducted negative, inconclusive, or replication studies. View the collection at: [NPub.org/NullHypothesis](https://www.neurology.org/NullHypothesis)

# Neurology®

## **Pearls & Oy-sters: Sequential Bilateral Hearing and Vision Loss With Optic Disc Swelling Due to Sphenoid Bone Craniofacial Fibrous Dysplasia**

Joel D. Handley, Sachin Mathur and Suresh K. Chhetri

*Neurology* 2023;100;439-443 Published Online before print November 30, 2022

DOI 10.1212/WNL.0000000000201663

**This information is current as of November 30, 2022**

<b>Updated Information &amp; Services</b>	including high resolution figures, can be found at: <a href="http://n.neurology.org/content/100/9/439.full">http://n.neurology.org/content/100/9/439.full</a>
<b>References</b>	This article cites 10 articles, 1 of which you can access for free at: <a href="http://n.neurology.org/content/100/9/439.full#ref-list-1">http://n.neurology.org/content/100/9/439.full#ref-list-1</a>
<b>Subspecialty Collections</b>	This article, along with others on similar topics, appears in the following collection(s): <b>All Neurotology</b> <a href="http://n.neurology.org/cgi/collection/all_neurotology">http://n.neurology.org/cgi/collection/all_neurotology</a> <b>Optic nerve</b> <a href="http://n.neurology.org/cgi/collection/optic_nerve">http://n.neurology.org/cgi/collection/optic_nerve</a>
<b>Permissions &amp; Licensing</b>	Information about reproducing this article in parts (figures, tables) or in its entirety can be found online at: <a href="http://www.neurology.org/about/about_the_journal#permissions">http://www.neurology.org/about/about_the_journal#permissions</a>
<b>Reprints</b>	Information about ordering reprints can be found online: <a href="http://n.neurology.org/subscribers/advertise">http://n.neurology.org/subscribers/advertise</a>

*Neurology*® is the official journal of the American Academy of Neurology. Published continuously since 1951, it is now a weekly with 48 issues per year. Copyright © 2022 American Academy of Neurology. All rights reserved. Print ISSN: 0028-3878. Online ISSN: 1526-632X.

