

# Teaching NeuroImage: Brain Calcification in a Young Woman With Seizures

Explore the Rare Differentials

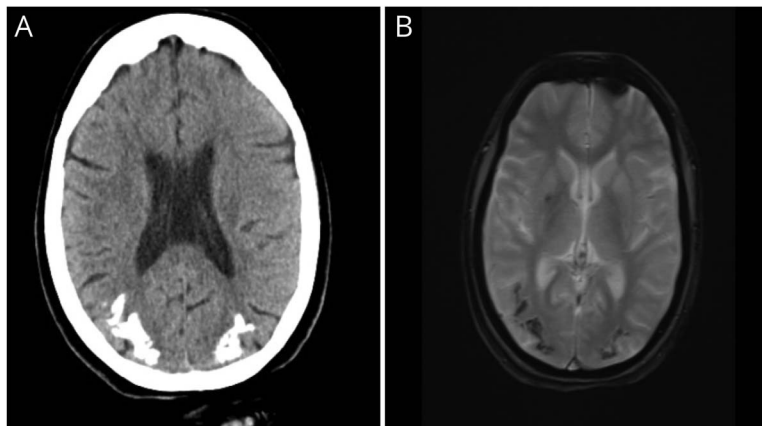
Bindu Menon, MD, Gayatri Manam, MD, Pramesh Reddy, MD, Harsha Mandalapu, MD, and A. Sudarsana, Pharm D

*Neurology*® 2023;100:397-398. doi:10.1212/WNL.0000000000201573

## Correspondence

Dr. Menon  
bindu.epilepsycare@gmail.com

**Figure** (A) CT Scan and (B) MRI (GRE) Show Bilateral Cortical and Subcortical Calcification in Parieto-occipital Regions



An 18-year-old woman presented with refractory seizures that started at the age of 10 years. There was no history of medication use for other illnesses, radiation exposure, or neurocutaneous stigma. Her CT scan and MRI (GRE) (Figure, A and B) showed bilateral cortical and subcortical calcification in parieto-occipital regions. Based on her imaging findings, celiac disease, epilepsy, and cerebral calcification (CEC) syndrome<sup>1,2</sup> was considered. This was confirmed by the presence of high antigliadin IgA (7.16U/mL), IgG (36.12 U/mL), and IgG tissue transglutaminase (645 U/mL) levels. Interictal EEG showed generalized discharges. Differentials were Sturge-Weber syndrome (SWS), congenital folate malabsorption, treatment with methotrexate and antifolate, and radiotherapy. SWS was excluded because of the absence of facial nevus, lobar atrophy, and subcortical calcification on MRI. Our patient had CEC syndrome with silent celiac disease. A gluten-free diet and antiseizure medications were recommended. She was seizure free on follow-up.

## Author Contributions

B. Menon: drafting/revision of the manuscript for content, including medical writing for content; major role in the acquisition of data; study concept or design; analysis or interpretation of data. G. Manam: analysis or interpretation of data. P. Reddy: major role in the acquisition of data; analysis or

## MORE ONLINE

### Teaching slides

[links.lww.com/WNL/C548](https://links.lww.com/WNL/C548).

From the Department of Neurology (B.M., A.S.); Department of Radiology (G.M., P.R.); and Department of Gastroenterology (H.M.), Apollo Speciality Hospitals, Nellore, India. Go to [Neurology.org/N](https://Neurology.org/N) for full disclosures.

interpretation of data. H. Mandalapu: analysis or interpretation of data. A Sudarsana: analysis or interpretation of data.

### Study Funding

The authors report no targeted funding.

### Disclosure

The authors report no disclosures relevant to the manuscript. Go to [Neurology.org/N](https://www.neurology.org/N) for full disclosures.

### Publication History

Received by *Neurology* May 24, 2022. Accepted in final form October 3, 2022. Submitted and externally peer reviewed. The handling editor was Associate Editor Roy Strowd III, MD, Med, MS.

### References

1. Bouquet F, Bouquet F, Greco L, et al. Coeliac disease, epilepsy, and cerebral calcifications. *Lancet*. 1992;340(8817):439-443.
2. Sunnikutty AP, Harding J, Nelson JC. CEC syndrome—a rare manifestation of coeliac disease. *Ulster Med J*. 2008;77(3):205-206.

---

## The *Neurology*<sup>®</sup> Null Hypothesis Online Collection...

### Contributing to a transparent research reporting culture!



The *Neurology* journals have partnered with the Center for Biomedical Research Transparency (CBMRT) to promote and facilitate transparent reporting of biomedical research by ensuring that all biomedical results—including negative and inconclusive results—are accessible to researchers and clinicians in the interests of full transparency and research efficiency.

*Neurology*'s Null Hypothesis Collection is a dedicated online section for well conducted negative, inconclusive, or replication studies. View the collection at: [NPub.org/NullHypothesis](https://Npub.org/NullHypothesis)

---



## Without Borders – A curated collection featuring advances in global neurology

This *Neurology*<sup>®</sup> special interest website is the go-to source for tracking science and politics of neurology beyond the United States, featuring up-to-the-minute blogs, scholarly perspectives, and academic review of developments and research from *Neurology* journals and other sources.

Expand your world view at [Neurology.org/woborders](https://www.neurology.org/woborders).

---

# Neurology<sup>®</sup>

## Teaching NeuroImage: Brain Calcification in a Young Woman With Seizures: Explore the Rare Differentials

Bindu Menon, Gayatri Manam, Pramesh Reddy, et al.

*Neurology* 2023;100:397-398 Published Online before print December 16, 2022

DOI 10.1212/WNL.0000000000201573

**This information is current as of December 16, 2022**

<b>Updated Information &amp; Services</b>	including high resolution figures, can be found at: <a href="http://n.neurology.org/content/100/8/397.full">http://n.neurology.org/content/100/8/397.full</a>
<b>References</b>	This article cites 2 articles, 0 of which you can access for free at: <a href="http://n.neurology.org/content/100/8/397.full#ref-list-1">http://n.neurology.org/content/100/8/397.full#ref-list-1</a>
<b>Subspecialty Collections</b>	This article, along with others on similar topics, appears in the following collection(s): <b>All Clinical Neurology</b> <a href="http://n.neurology.org/cgi/collection/all_clinical_neurology">http://n.neurology.org/cgi/collection/all_clinical_neurology</a> <b>All Epilepsy/Seizures</b> <a href="http://n.neurology.org/cgi/collection/all_epilepsy_seizures">http://n.neurology.org/cgi/collection/all_epilepsy_seizures</a> <b>All Medical/Systemic disease</b> <a href="http://n.neurology.org/cgi/collection/all_medical_systemic_disease">http://n.neurology.org/cgi/collection/all_medical_systemic_disease</a> <b>Clinical neurology history</b> <a href="http://n.neurology.org/cgi/collection/clinical_neurology_history">http://n.neurology.org/cgi/collection/clinical_neurology_history</a> <b>EEG; see Epilepsy/Seizures</b> <a href="http://n.neurology.org/cgi/collection/eeg_see_epilepsy-seizures">http://n.neurology.org/cgi/collection/eeg_see_epilepsy-seizures</a>
<b>Permissions &amp; Licensing</b>	Information about reproducing this article in parts (figures, tables) or in its entirety can be found online at: <a href="http://www.neurology.org/about/about_the_journal#permissions">http://www.neurology.org/about/about_the_journal#permissions</a>
<b>Reprints</b>	Information about ordering reprints can be found online: <a href="http://n.neurology.org/subscribers/advertise">http://n.neurology.org/subscribers/advertise</a>

*Neurology*® is the official journal of the American Academy of Neurology. Published continuously since 1951, it is now a weekly with 48 issues per year. Copyright © 2022 American Academy of Neurology. All rights reserved. Print ISSN: 0028-3878. Online ISSN: 1526-632X.

