

Teaching NeuroImage: Glioblastoma Multiforme Presenting as Optic Neuropathy

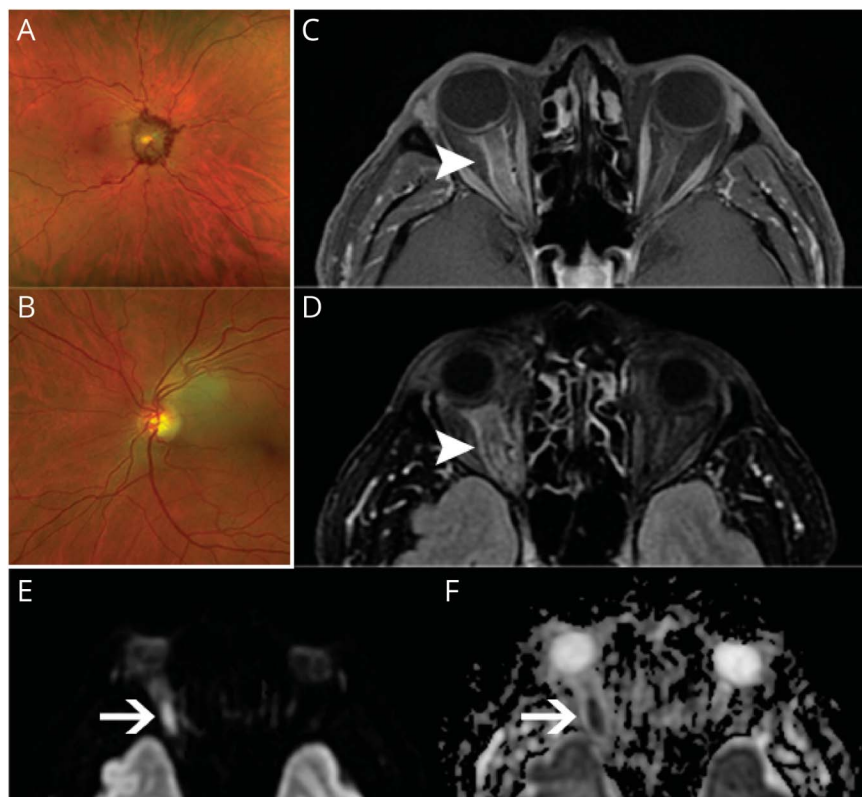
Jose Maria Cabrera-Maqueda, MD, Elianet Fonseca, MD, Maria Sepulveda, MD, PhD, Anna Camós-Carreras, MD, and Yolanda Blanco, MD, PhD

Neurology® 2023;100:94-96. doi:10.1212/WNL.0000000000201480

Correspondence

Dr. Sepulveda
msepulve@clinic.cat

Figure 1 Initial Fundus Examination



(A) Right eye: severe optic disc edema with peripapillary hemorrhages and (B) left eye: normal optic disc. (C) Post-contrast axial T1-weighted fat-suppressed orbital MRI shows thickening and perineural enhancement of the right optic nerve at onset (arrowhead). (D) FLAIR brain MRI shows an increased enlargement of the right optic nerve after 2 months of follow-up (arrowhead) and persistent enhancement on postcontrast T1-weighted image (not shown). (E) Diffusion-weighted and (F) apparent diffusion coefficient images at onset demonstrate marked diffusion restriction along the right optic nerve (arrows).

A 63-year-old man presented with sudden vision loss in the right eye. Funduscopic examination revealed right severe disc edema with peripapillary hemorrhages with no abnormality on the left (Figure 1, A and B). Orbit and brain MRI's showed an extensive enhancing lesion with restricted diffusion involving the right optic nerve (Figure 1, C–F) and FLAIR hyperintense lesions in the right hippocampus (Figure 2A) and parietal lobe (Figure 2, C and D). The patient received oral corticosteroids followed by plasma exchange. Owing to lack of clinical improvement, a new brain MRI was obtained, showing an enlargement of the lesions (Figure 2, E–H). The biopsy of the

MORE ONLINE

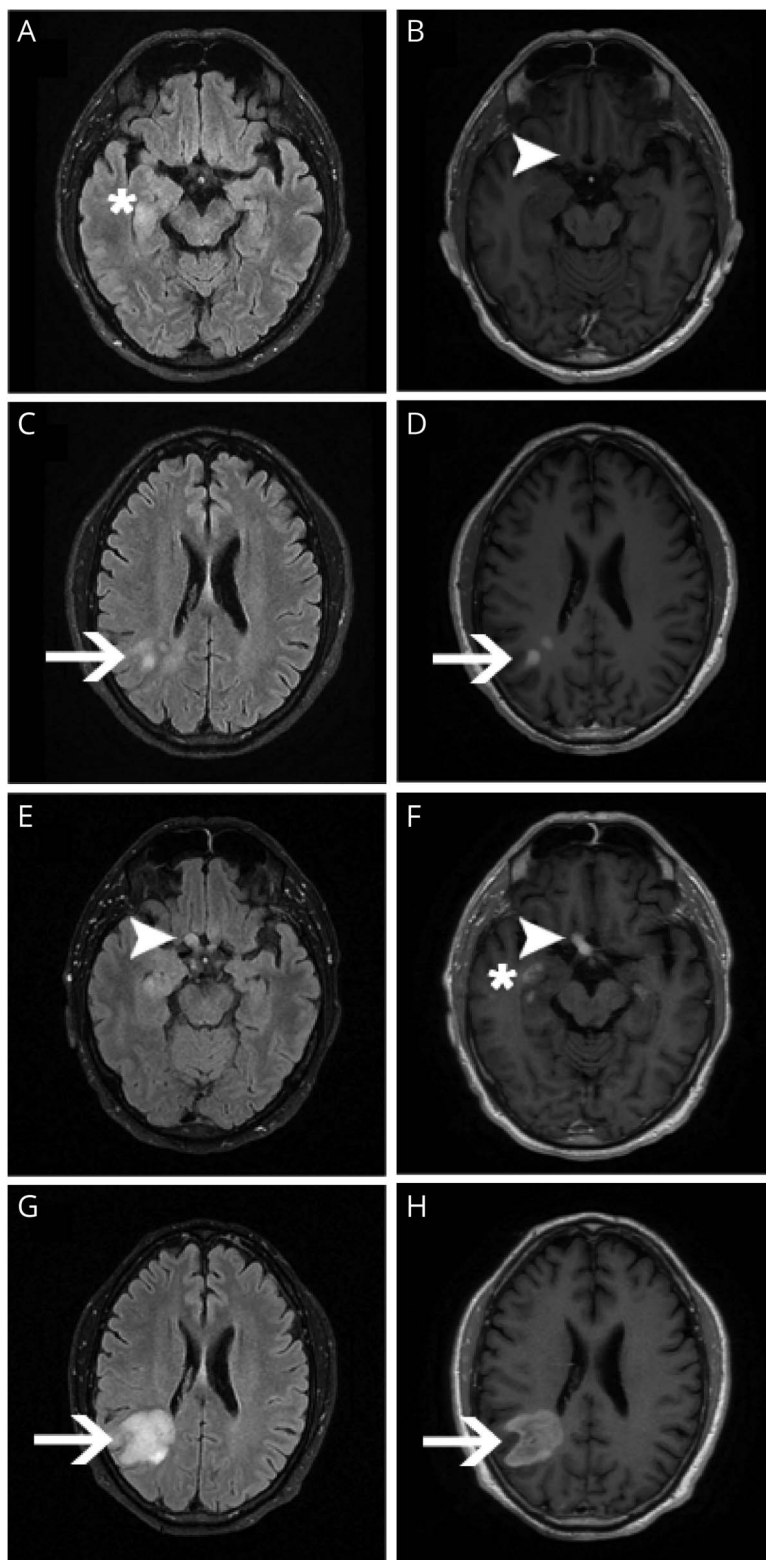
Teaching slides

links.lww.com/WNL/C439

From the Center of Neuroimmunology (J.M.C.-M., M.S., Y.B.), Service of Neurology, Laboratory of Advanced Imaging in Neuroimmunological Diseases, Hospital Clínic of Barcelona, Institut d'Investigacions Biomèdiques August Pi i Sunyer (IDIBAPS), and Universitat de Barcelona; Department of Neurology (E.F.), School of Medicine, Pontificia Universidad Católica de Chile; and Department of Ophthalmology (A.C.-C.), Hospital Clínic of Barcelona, Spain.

Go to Neurology.org/N for full disclosures. Funding information and disclosures deemed relevant by the authors, if any, are provided at the end of the article.

Figure 2 Axial FLAIR (A, C, E, G) and Gadolinium-Enhanced T1-Weighted (B, D, F, H) Brain MRI at Onset (A–D) and 2 Months Later (E–H)



Initial MRI shows increased FLAIR signal in the hippocampus (A, asterisk), with no apparent infiltration of the chiasm (B, arrowhead), and in the right parietal lobe (C, arrow) with contrast enhancement (D, arrow). Follow-up MRI shows thickening (E, arrowhead) and enhancement of the chiasm (F, arrowhead) and hippocampal lesion (F, asterisk) and enlargement of the parietal lesions (G, arrows) with contrast enhancement (H, arrow).

parietal lesion confirmed the diagnosis of glioblastoma multiforme (GBM). Visual deficit as initial presentation of GBM is rare (13%).¹ A neoplastic origin of an optic neuropathy should be considered in enlarged optic nerve with persistent enhancement and marked MRI diffusion restriction.²

Study Funding

The authors report no targeted funding.

Disclosure

J.M. Cabrera received speaking honoraria from Sanofi; E. Fonseca received funding from ECTRIMS Clinical Training Fellowship Programme; M. Sepulveda received speaking honoraria from Roche, Biogen, and UCB Pharma and travel reimbursement from Biogen, Sanofi, and Zambon for national and international meetings; A. Camós-Carreras has nothing to disclose; Y. Blanco received speaking honoraria from Biogen, Merck, Novartis, and Genzyme. Go to Neurology.org/N for full disclosures.

Publication History

Received by *Neurology* April 27, 2022. Accepted in final form September 13, 2022. Submitted and externally peer reviewed. The handling editor was Roy Strowd III, MD, Med, MS.

Appendix Authors

Name	Location	Contribution
Jose Maria Cabrera-Maqueda, MD	Center of Neuroimmunology, Service of Neurology, Laboratory of Advanced Imaging in Neuroimmunological Diseases, Hospital Clínic of Barcelona, Institut d'Investigacions Biomèdiques August Pi i Sunyer (IDIBAPS), and Universitat de Barcelona, Spain	Drafting/revision of the manuscript for content, including medical writing for content; major role in the acquisition of data; study concept or design; analysis or interpretation of data

Appendix (continued)

Name	Location	Contribution
Eliana Fonseca, MD	Department of Neurology, School of Medicine, Pontificia Universidad Católica de Chile	Drafting/revision of the manuscript for content, including medical writing for content; major role in the acquisition of data; study concept or design; analysis or interpretation of data
Maria Sepulveda, MD, PhD	Center of Neuroimmunology, Service of Neurology, Laboratory of Advanced Imaging in Neuroimmunological Diseases, Hospital Clínic of Barcelona, Institut d'Investigacions Biomèdiques August Pi i Sunyer (IDIBAPS), and Universitat de Barcelona, Spain	Drafting/revision of the manuscript for content, including medical writing for content; major role in the acquisition of data; study concept or design; analysis or interpretation of data
Anna Camós-Carreras, MD	Department of Ophthalmology, Hospital Clínic of Barcelona, Spain	Drafting/revision of the manuscript for content, including medical writing for content; major role in the acquisition of data
Yolanda Blanco, MD, PhD	Center of Neuroimmunology, Service of Neurology, Laboratory of Advanced Imaging in Neuroimmunological Diseases, Hospital Clínic of Barcelona, Institut d'Investigacions Biomèdiques August Pi i Sunyer (IDIBAPS), and Universitat de Barcelona, Spain	Drafting/revision of the manuscript for content, including medical writing for content; major role in the acquisition of data

References

- Gilard V, Tebani A, Dabaj I, et al. Diagnosis and management of glioblastoma: a comprehensive perspective. *J Pers Med*. 2021;11(4):258. DOI: 10.3390/jpm11040258
- Ramakrishnan MS, Vora RA, Gilbert AL. Glioblastoma multiforme mimicking optic neuritis. *Am J Ophthalmol*. 2020;17:100594. DOI: 10.1016/j.ajoc.2020.100594

Neurology® Online CME Program

Earn CME while reading *Neurology*. This program is available to AAN members and to online *Neurology* subscribers. Read the articles marked CME, go to Neurology.org, and click on the CME link. The American Academy of Neurology (AAN) is accredited by the Accreditation Council for Continuing Medical Education (ACCME) to sponsor continuing medical education for physicians. *Neurology* is planned and produced in accordance with the ACCME Essentials. For more information, contact AAN Member Services at 800-879-1960.

Neurology[®]

Teaching NeuroImage: Glioblastoma Multiforme Presenting as Optic Neuropathy

Jose Maria Cabrera-Maqueda, Elianet Fonseca, Maria Sepulveda, et al.
Neurology 2023;100:94-96 Published Online before print October 18, 2022
DOI 10.1212/WNL.0000000000201480

This information is current as of October 18, 2022

Updated Information & Services	including high resolution figures, can be found at: http://n.neurology.org/content/100/2/94.full
References	This article cites 2 articles, 0 of which you can access for free at: http://n.neurology.org/content/100/2/94.full#ref-list-1
Subspecialty Collections	This article, along with others on similar topics, appears in the following collection(s): All Neuro-ophthalmology http://n.neurology.org/cgi/collection/all_neuroophthalmology Optic nerve http://n.neurology.org/cgi/collection/optic_nerve Optic neuritis; see Neuro-ophthalmology/Optic Nerve http://n.neurology.org/cgi/collection/optic_neuritis Primary brain tumor http://n.neurology.org/cgi/collection/primary_brain_tumor
Permissions & Licensing	Information about reproducing this article in parts (figures, tables) or in its entirety can be found online at: http://www.neurology.org/about/about_the_journal#permissions
Reprints	Information about ordering reprints can be found online: http://n.neurology.org/subscribers/advertise

Neurology® is the official journal of the American Academy of Neurology. Published continuously since 1951, it is now a weekly with 48 issues per year. Copyright © 2022 American Academy of Neurology. All rights reserved. Print ISSN: 0028-3878. Online ISSN: 1526-632X.

