

Teaching NeuroImage: Intracranial Solitary Fibrous Tumor With Liver Metastasis

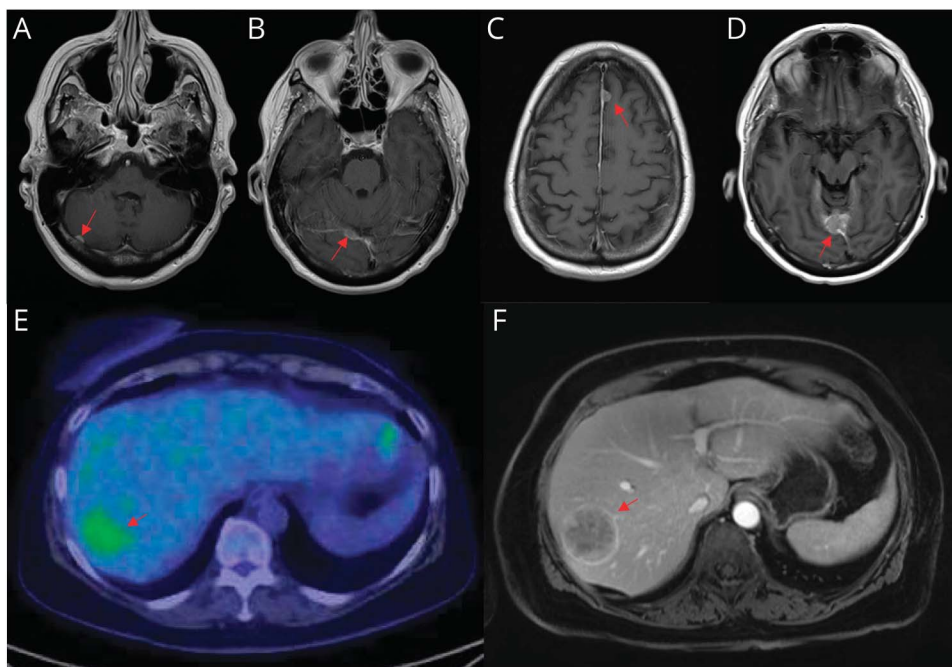
Mason James Webb, MD, PhD, Jian L. Campian, MD, PhD, and Ugur Sener, MD

Neurology® 2023;100:884-885. doi:10.1212/WNL.000000000206822

Correspondence

Dr. Sener
sener.ugur@mayo.edu

Figure MRI of the Brain and PET-CT of the Liver



Postcontrast T1-weighted MRI axial demonstrating lesions involving the right cerebellum (A), right tentorial leaflet (B), and left anterior falx (C). (D) Postcontrast T1-weighted MRI axial demonstrating increased size of right tentorial lesion. (E) PET-CT demonstrating lesion in the superior posterior right hepatic lobe. (F) MRI demonstrating hepatic metastasis.

A 65-year-old woman presented with nausea, headache, and visual changes. MRI of the brain identified dural-based lesions involving the right cerebellum, right tentorium, and left anterior falx believed to be consistent with meningiomas (Figure, A–C). Owing to unclear association between imaging findings and clinical symptoms, surveillance was recommended. Follow-up was inadvertently delayed. Repeat imaging at 7 months revealed enlarging tentorial lesion, treated with gamma knife radiosurgery (GKRS) (Figure, D). Further growth prompted resection of the cerebellar lesion. Tumor cells were positive for STAT6 on immunohistochemistry, establishing solitary fibrous tumor (SFT) as the diagnosis. PET-CT identified fluorodeoxyglucose-avid hepatic lesion, with biopsy confirming STAT6, CD34, and synaptophysin-positive metastatic SFT (Figure, E–F). After additional GKRS, systemic therapy with sunitinib was started. SFTs are mesenchymal neoplasms predominantly affecting young adults that should be included in the differential of durally based lesions.¹ Given propensity for extracranial metastasis, systemic imaging should be obtained on establishing tissue diagnosis.²

MORE ONLINE

Teaching slides

links.lww.com/WNL/C595

From the Department of Hematology and Oncology (M.J.W.); Department of Oncology (J.L.C.), Division of Medical Oncology; Department of Neurology (U.S.), Mayo Clinic, Rochester, MN. Go to Neurology.org/N for full disclosures. Funding information and disclosures deemed relevant by the authors, if any, are provided at the end of the article.

Author Contributions

M.J. Webb: drafting/revision of the manuscript for content, including medical writing for content, analysis or interpretation of data. J.L. Campian: major role in the acquisition of data. U. Sener: drafting/revision of the manuscript for content, including medical writing for content; major role in the acquisition of data; study concept or design; analysis or interpretation of data.

Study Funding

The authors report no targeted funding.

Disclosure

The authors report no relevant disclosures. Go to [Neurology.org/N](https://www.neurology.org/N) for full disclosures.

Publication History

Received by *Neurology* August 8, 2022. Accepted in final form December 2, 2022. Submitted and externally peer reviewed. The handling editor was Resident and Fellow Section Editor Whitley Aamodt, MD, MPH.

References

1. Louis DN, Perry A, Wesseling P, et al. The 2021 WHO Classification of Tumors of the Central Nervous System: a summary. *Neuro Oncol*. 2021;23(8):1231-1251. doi: 10.1093/neuonc/noab106.
2. Ratneswaren T, Hogg FRA, Gallagher MJ, Ashkan K. Surveillance for metastatic hemangiopericytoma-solitary fibrous tumors-systematic literature review on incidence, predictors and diagnosis of extra-cranial disease. *J Neurooncol*. 2018;138(3):447-467. doi: 10.1007/s11060-018-2836-2.



Practice Current: An interactive exchange on controversial topics

Share your own best practices.

Read commentary with expert opinion.

Explore results on an interactive world map.

[NPub.org/NCP/practicecurrent](https://www.ncbi.nlm.nih.gov/pmc/articles/PMC6888888/)

Neurology® *Clinical Practice*

The *Neurology*® Null Hypothesis Online Collection...

Contributing to a transparent research reporting culture!



The *Neurology* journals have partnered with the Center for Biomedical Research Transparency (CBMRT) to promote and facilitate transparent reporting of biomedical research by ensuring that all biomedical results—including negative and inconclusive results—are accessible to researchers and clinicians in the interests of full transparency and research efficiency.

Neurology's Null Hypothesis Collection is a dedicated online section for well conducted negative, inconclusive, or replication studies. View the collection at: [NPub.org/NullHypothesis](https://www.ncbi.nlm.nih.gov/pmc/articles/PMC6888888/)

Neurology®

Teaching NeuroImage: Intracranial Solitary Fibrous Tumor With Liver Metastasis

Mason James Webb, Jian L. Campian and Ugur Sener

Neurology 2023;100:884-885 Published Online before print December 23, 2022

DOI 10.1212/WNL.0000000000206822

This information is current as of December 23, 2022

Updated Information & Services	including high resolution figures, can be found at: http://n.neurology.org/content/100/18/884.full
References	This article cites 2 articles, 0 of which you can access for free at: http://n.neurology.org/content/100/18/884.full#ref-list-1
Subspecialty Collections	This article, along with others on similar topics, appears in the following collection(s): All Headache http://n.neurology.org/cgi/collection/all_headache All Oncology http://n.neurology.org/cgi/collection/all_oncology Metastatic tumor http://n.neurology.org/cgi/collection/metastatic_tumor MRI http://n.neurology.org/cgi/collection/mri PET http://n.neurology.org/cgi/collection/pet
Permissions & Licensing	Information about reproducing this article in parts (figures, tables) or in its entirety can be found online at: http://www.neurology.org/about/about_the_journal#permissions
Reprints	Information about ordering reprints can be found online: http://n.neurology.org/subscribers/advertise

Neurology® is the official journal of the American Academy of Neurology. Published continuously since 1951, it is now a weekly with 48 issues per year. Copyright © 2022 American Academy of Neurology. All rights reserved. Print ISSN: 0028-3878. Online ISSN: 1526-632X.

