

# Pearls & Oy-sters: Trigeminal Cystic Schwannoma Presenting With Foster Kennedy Syndrome, Sixth Nerve Palsy, and Focal Seizures

Yasamin Mahjoub, MD, Miranda Wan, MD, and Suresh Subramaniam, MD

*Neurology*® 2023;100:587-590. doi:10.1212/WNL.00000000000021700

**Correspondence**

Dr. Mahjoub  
ymahjoub@ucalgary.ca

## Abstract

Foster Kennedy syndrome refers to a finding of optic atrophy in one eye from direct compression of the optic nerve by a mass lesion and contralateral papilledema in the nonatrophic optic nerve caused by an increased intracranial pressure. When the fundoscopy finding is not due to a direct compressive mass, the term pseudo-Foster Kennedy syndrome is used; this can be caused by any process or processes that result in optic atrophy in one eye and optic disc edema in the other. Identifying Foster Kennedy syndrome in a patient calls for expedient neuroimaging looking for an intracranial mass lesion. In this article, we present the case of a patient presenting with vision loss and Foster Kennedy syndrome who was found to have a large trigeminal cystic schwannoma. While several other accompanying symptoms were not evident from the patient complaint, a careful history and physical examination revealed additional localizing clues: unilateral sensory changes in the face and pterygoid and masseter atrophy, unilateral cranial nerve VI palsy, and episodes of intense déjà vu sensation, which were presumed to represent temporal lobe–onset focal aware seizures. Trigeminal schwannomas are a rare entity, and they are even more rarely cystic. This case highlights an unusual scenario where a slow expansion of the tumor ultimately resulted in vision loss and presentation of the patient to medical attention.

## Pearls

- Optic atrophy in one eye and papilledema in the other is a tell-tale sign of Foster Kennedy syndrome and may be the presenting feature of an indolent slow-growing tumor.
- The finding of a Foster Kennedy syndrome should prompt expedited neuroimaging.
- A junctional scotoma is a vision loss pattern consisting of ipsilateral central and contralateral superotemporal field loss, suggestive of a lesion at the junction of the optic nerve and optic chiasm.
- Involvement of cranial nerves III, IV, VI, and the ophthalmic and maxillary branches of cranial nerve V may be indicative of a cavernous sinus localization.

## Oy-sters

- Pseudo-Foster Kennedy syndrome refers to optic atrophy in one eye and disc edema in the other caused by an etiology other than a compressive mass lesion, most commonly bilateral sequential nonarteritic ischemic optic neuropathy. Once a mass lesion has been ruled out, investigations should be conducted to evaluate alternative causes.
- Consider accompanying neurologic symptoms and signs outside of the neuro-ophthalmologic examination.

A 28-year-old previously healthy man was seen at the neuro-ophthalmology clinic with a 5-month history of painless vision loss in the right eye. He reported gradual onset of a dark central scotoma that expanded over this period to include his entire field of vision. On further review of the history, he described a 4-year history of intermittent binocular horizontal diplopia

From the Department of Clinical Neurosciences (Y.M., M.W., S.S.), University of Calgary; and Department of Surgery (S.S.), University of Calgary, Canada.

Go to [Neurology.org/N](https://www.neurology.org/N) for full disclosures. Funding information and disclosures deemed relevant by the authors, if any, are provided at the end of the article.

that was worse in right gaze. He had also noticed episodes of intense déjà vu sensation, followed by altered taste and smell and a rising epigastric sensation. These episodes would last 30 seconds, and awareness would be maintained throughout. He also noted long-standing numbness in his right upper face, which he had attributed to prior dental work. On neurologic examination, his visual acuity was light perception in the right eye and 20/30 in the left eye. Humphrey automated perimetry demonstrated a pattern of dense central field loss in the right eye and a superior temporal field defect in the left eye (Figure 1). Color vision could not be assessed in the right eye and was normal in the left eye. There was a right relative afferent pupillary defect. Fundoscopy revealed optic disc pallor in the right eye and optic disc edema in the left eye (Figure 1). Optical coherence tomography showed thinning of the right retinal nerve fiber layer (RNFL) with an average thickness of 68  $\mu\text{m}$  with edema on the left with an average RNFL thickness of 141  $\mu\text{m}$ . Efferent visual system examination showed esotropia in primary position, which worsened on right gaze. There was a restriction in right eye abduction, consistent with a right cranial nerve VI palsy. Otherwise, saccades and smooth pursuit were normal, there was no ptosis, and the pupils were round, equal, and reactive to light. The remainder of the cranial nerve examination showed decreased sensation to light touch in the right face, the distribution of all 3 trigeminal nerve branches, and weakness and atrophy of the right pterygoid and masseter muscles.

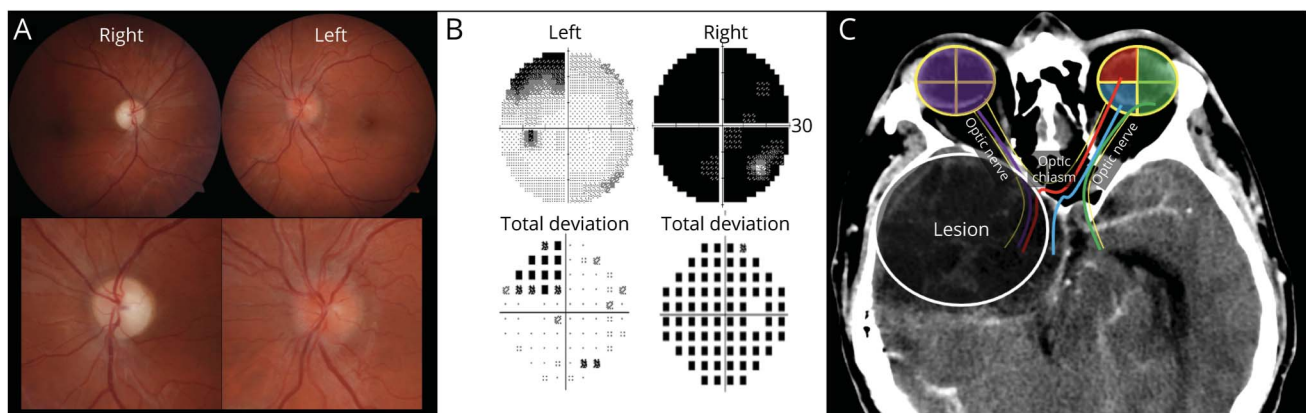
An urgent enhanced CT head was arranged revealing a large extra-axial right frontal mass with significant mass effect and midline shift along with entrapment of the left lateral ventricle and effacement of the basal cisterns (Figure 2). There was adjacent bone remodeling, suggestive of a long-standing

lesion. Further characterization of the lesion with enhanced MRI brain showed a large multicystic rim-enhancing extra-axial mass occupying much of the right middle cranial fossa, with extension to the right orbital apex and superior orbital fissure, foramen ovale, cavernous sinus, Meckel cave, and right cerebellopontine angle cistern with accompanying compression of the pons and middle cerebellar peduncle. The patient was admitted to the neurosurgical service. An EEG was performed, which showed moderate generalized background slowing, worse over the right hemisphere without any interictal epileptiform discharges, seizures, or any déjà vu events captured. However, the patient was started on phenytoin on clinical grounds. The lesion was resected in 2 stages. Histologically, it was predominantly composed of Antoni A spindle cells in interlacing fascicles with a few regions of Antoni B architecture and foci of hemosiderin deposition and degeneration. This was consistent with a WHO grade I schwannoma arising from the trigeminal nerve. Postoperatively, his right eye vision remained unchanged, while his left eye visual acuity improved slightly to 20/25. He continued to have limitation of right eye abduction and occasional paresthesia involving the right hemiface. The episodes of déjà vu resolved.

## Discussion

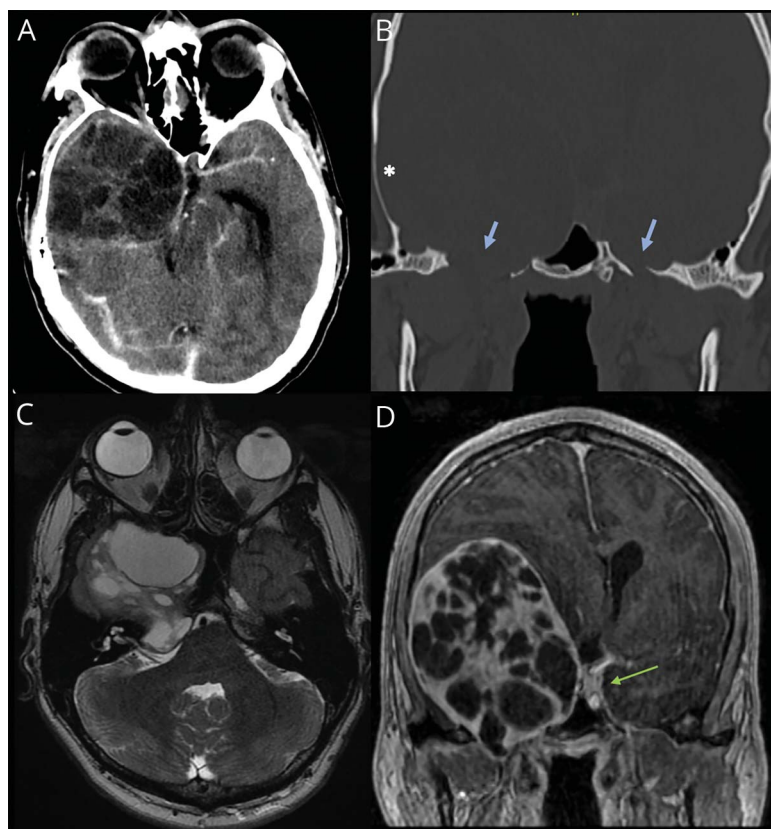
This case describes a patient presenting initially with subacute vision loss who was found to have a massive trigeminal cystic schwannoma. The clinical examination provided several neuroanatomical localization clues that guided focused workup in the form of urgent neuroimaging and expedited neurosurgical consultation. The clinical picture of vision loss and optic disc pallor with papilledema on the contralateral side is consistent with Foster Kennedy syndrome, wherein a mass lesion directly compresses the ipsilateral optic nerve resulting in optic atrophy, while increased intracranial

**Figure 1** Fundus Photographs, Perimetry, and Diagram of Junctional Scotoma



(A) Fundus photographs showing optic disc pallor on the right and disc edema on the left; (B) Visual fields using Humphrey automated perimetry showing dense depression on the right and a superotemporal defect on the left; (C) Junctional scotoma schematic superimposed on axial CT head image. The lesion causes optic nerve compression of the ipsilateral (right) eye (purple line) and dense visual field depression. In addition, there is compression of the inferonasal retinal fibers from the contralateral (left) eye (red line) resulting in a superotemporal defect. This pattern of vision loss is known as a junctional scotoma and is suggestive of a lesion at the junction of the optic nerve and chiasm.

**Figure 2** CT and MRI Showing a Large Cystic Tumor



CT head with contrast (A) showing a large heterogeneous right middle cranial fossa lesion with mass effect; bone window (B) showing thinning and remodeling on the right adjacent skull (asterisk) with the foramen ovale on both sides marked (blue arrows), demonstrating expansion on the right through which the mass extends. Axial T2 MR (C) shows a heterogeneous dumbbell-shaped multilobulated mass. Coronal T1 postcontrast MR (D) image shows a cystic ring-enhancing mass; the green arrow marks the cavernous sinus on the unaffected left side demonstrating extension of the mass into cavernous sinus on the right side.

pressure from the mass results in papilledema in the contralateral nonatrophied side.<sup>1</sup> This eponymous syndrome was described by the prominent American neurologist Foster Kennedy (of note, he is well known to have held views in favor of eugenics, advocating for elimination or sterilization of impaired individuals.<sup>2</sup> This historical perspective perhaps raises a case for renaming of the syndrome.). Foster Kennedy syndrome is classically caused by olfactory groove, falx, sphenoidal wing, or subfrontal meningiomas.<sup>1</sup> However, any compressive lesion can theoretically cause this presentation, and other reported etiologies include frontal abscesses, craniopharyngiomas, pituitary adenomas, plasmacytomas, neuroblastomas, nasopharyngeal angiofibromas, and aneurysms.<sup>1</sup>

The pattern of visual field loss is in keeping with a junctional scotoma with a lesion at the junction of the optic nerve and chiasm compressing the ipsilateral optic nerve causing a central scotoma and affecting crossing fibers from the inferonasal retina of the contralateral eye resulting in a superotemporal scotoma in that eye (Figure 1). By contrast, a junctional scotoma of Traquair consists of a monocular nasal or temporal hemianopia and is caused by a lesion at the junction of the optic nerve and chiasm, but only affecting nasal or temporal fibers. The most common cause for both visual field patterns is a pituitary adenoma; alternative causes

include other compressive tumors (such as craniopharyngiomas, astrocytomas, or meningiomas).<sup>3</sup>

The presence of ipsilateral cranial nerve VI palsy with involvement of the ophthalmic and maxillary branches of the trigeminal nerve is suggestive of a cavernous sinus localization. Cranial nerve VI and ophthalmic branch involvement (without the maxillary branch) could also invoke superior orbital fissure or orbital apex localization. However, there was also involvement of the mandibular branch, evidenced by lower face sensory changes and motor weakness and atrophy of the pterygoid and masseter muscles, most likely suggestive of proximal trigeminal involvement. Finally, his recurrent episodes of intense déjà vu were felt to represent focal aware temporal lobe seizures, implying a lesion extending into the temporal region. Taken together, the constellation of findings is suggestive of a large compressive lesion affecting multiple cranial nerves, the optic chiasm, and the temporal lobe.

When the combination of optic atrophy and disc edema in the contralateral eye is caused by an etiology other than a compressive mass lesion, the term “pseudo-Foster Kennedy syndrome” is used. This can be seen in the setting of bilateral sequential nonarteritic anterior ischemic optic neuropathy (NAION)<sup>4,6</sup> or optic neuritis,<sup>4</sup> but any event causing optic

atrophy followed by an acute contralateral episode with disc edema can present similarly. Other reported causes include idiopathic intracranial hypertension,<sup>7</sup> syphilis,<sup>4</sup> traumatic optic neuropathy,<sup>4</sup> unilateral optic nerve hypoplasia with Chiari malformation,<sup>8</sup> p-ANCA positive pachymeningitis,<sup>9</sup> NAION with subsequent nonbasal glioma,<sup>10</sup> gyrus rectus displacement by a distant tumor,<sup>11</sup> and a meningioma infiltrating the superior sagittal sinus.<sup>12</sup> There is one case report in the literature of what is termed “pseudo-pseudo-Foster Kennedy syndrome” where optic atrophy was caused by direct compression from a meningioma, while the contralateral nerve was swollen from concurrent NAION.<sup>13</sup>

The vestibulocochlear nerve is the most common location for intracranial schwannomas, and trigeminal schwannomas are rare, accounting for less than 1% of intracranial tumors.<sup>14</sup> These masses tend to be solid neoplasms, but cystic degeneration can rarely occur in approximately 7% of trigeminal schwannomas.<sup>15</sup> This may occur due to intratumoral bleeding, central ischemic, necrosis, or degenerative changes.<sup>14</sup> Management typically involves surgical resection, although stereotactic radiosurgery can be used for smaller lesions.<sup>14</sup>

In this case, we have described a patient presenting with vision loss and a constellation of findings that provided neuroanatomical localizing clues: Foster Kennedy syndrome, cranial nerve VI palsy, motor and sensory trigeminal involvement, and suspected temporal lobe onset focal aware seizures. The neuro-ophthalmological examination finding of Foster Kennedy syndrome is important to recognize and should prompt neuroimaging. To our knowledge, this is the first reported case of Foster Kennedy syndrome caused by a trigeminal schwannoma.

### Study Funding

The authors report no targeted funding.

### Disclosure

The authors report no relevant disclosures. Go to Neurology.org/N for full disclosures.

### Publication History

Received by *Neurology* July 4, 2022. Accepted in final form November 1, 2022. Submitted and externally peer reviewed. The handling editor was Resident and Fellow Section Editor Whitley Aamodt, MD, MPH.

## Appendix Authors

Name	Location	Contribution
<b>Yasamin Mahjoub, MD</b>	Department of Clinical Neurosciences, University of Calgary, Canada	Drafting/revision of the article for content, including medical writing for content; major role in the acquisition of data; and analysis or interpretation of data
<b>Miranda Wan, MD</b>	Department of Clinical Neurosciences, University of Calgary, Canada	Drafting/revision of the article for content, including medical writing for content; major role in the acquisition of data; and analysis or interpretation of data
<b>Suresh Subramaniam, MD</b>	Department of Clinical Neurosciences, University of Calgary, Canada; Department of Surgery, University of Calgary, Canada	Drafting/revision of the article for content, including medical writing for content; major role in the acquisition of data; study concept or design; and analysis or interpretation of data

## References

- Lotfipour S, Chiles K, Kahn JA, Bey T, Rudkin S. An unusual presentation of sub-frontal meningioma: a case report and literature review for Foster Kennedy syndrome. *Intern Emerg Med*. 2011;6(3):267-269. doi: 10.1007/S11739-010-0437-Y
- Offen ML. Dealing with “defectives” foster Kennedy and William Lennox on eugenics. *Neurology*. 2003;61(5):668-673. doi: 10.1212/WNL.61.5.668
- Schiefer U, Isbert M, Mikolaschek E, et al. Distribution of scotoma pattern related to chiasmal lesions with special reference to anterior junction syndrome. *Graefes Arch Clin Exp Ophthalmol*. 2004;42(6):468-477. doi: 10.1007/S00417-004-0863-5
- Schatz NJ, Smith JL. Non-tumor causes of the Foster Kennedy syndrome. *J Neurosurg*. 1967;27(1):37-44. doi: 10.3171/JNS.1967.27.1.0037
- Patil A, Takkar A, Goyal M, Singh R, Lal V. Sequential NAION presenting as pseudo Foster Kennedy syndrome. *J Neurol Sci*. 2017;376:49-51. doi: 10.1016/j.jns.2017.02.002
- Lepore FE, Yarian DL. A mimic of the “exact diagnostic sign” of Foster Kennedy. *Ann Ophthalmol*. 1985;17(7):411-412.
- Micieli JA, Al-Obthani M, Sundaram ANE. Pseudo-Foster Kennedy syndrome due to idiopathic intracranial hypertension. *Can J Ophthalmol*. 2014;49(4):e99-e102. doi: 10.1016/j.jco.2014.05.002
- Bansal S, Dabbs T, Long V. Pseudo-Foster Kennedy Syndrome due to unilateral optic nerve hypoplasia: a case report. *J Med Case Rep*. 2008;2:86. doi: 10.1186/1752-1947-2-86
- Tamai H, Tamai K, Yuasa H. Pachymeningitis with pseudo-Foster Kennedy syndrome. *Am J Ophthalmol*. 2000;130(4):535-537. doi: 10.1016/S0002-9394(00)00566-3
- Limaye SR, Adler J. Pseudo-Foster Kennedy syndrome in a patient with anterior ischemic optic neuropathy and a nonbasal glioma. *J Clin Neuroophthalmol*. 1990;10(3):188-192.
- Desai N, Yong RL, Doshi A, Rucker JC. Pseudo-Foster-Kennedy syndrome with optic nerve compression by the gyrus rectus. *Neurology*. 2015;85(4):385-385. doi: 10.1212/WNL.0000000000001791
- Semeraro F, Forbice E, Duse S, Costagliola C. Pseudo-Foster Kennedy syndrome in a young woman with meningioma infiltrating the superior sagittal sinus. *Clin Neurol Neurosurg*. 2012;114(3):272-274. doi: 10.1016/j.clineuro.2011.10.018
- Gelwan MJ, Seidman M, Kupersmith MJ. Pseudo-pseudo-Foster Kennedy syndrome. *J Clin Neuroophthalmol*. 1988;8(1):49-52.
- Ortega-Merchan MP, Reyes F, Mejia JA, Rivera DM, Galvis JC, Marquez JC. Cystic trigeminal schwannomas. *Radiol Case Rep*. 2019;14(12):1513. doi: 10.1016/j.radcr.2019.09.031
- Wanibuchi M, Fukushima T, Zomordi AR, Nonaka Y, Friedman AH. Trigeminal schwannomas: skull base approaches and operative results in 105 patients. *Neurosurgery*. 2012;70(1 Suppl Operative):132-143. doi: 10.1227/NEU.0B013E31822EFB21



# Neurology<sup>®</sup>

## **Pearls & Oy-sters: Trigeminal Cystic Schwannoma Presenting With Foster Kennedy Syndrome, Sixth Nerve Palsy, and Focal Seizures**

Yasamin Mahjoub, Miranda Wan and Suresh Subramaniam

*Neurology* 2023;100;587-590 Published Online before print December 19, 2022

DOI 10.1212/WNL.0000000000201700

**This information is current as of December 19, 2022**

<b>Updated Information &amp; Services</b>	including high resolution figures, can be found at: <a href="http://n.neurology.org/content/100/12/587.full">http://n.neurology.org/content/100/12/587.full</a>
<b>References</b>	This article cites 15 articles, 2 of which you can access for free at: <a href="http://n.neurology.org/content/100/12/587.full#ref-list-1">http://n.neurology.org/content/100/12/587.full#ref-list-1</a>
<b>Subspecialty Collections</b>	This article, along with others on similar topics, appears in the following collection(s): <b>All Neuro-ophthalmology</b> <a href="http://n.neurology.org/cgi/collection/all_neuroophthalmology">http://n.neurology.org/cgi/collection/all_neuroophthalmology</a> <b>Clinical neurology examination</b> <a href="http://n.neurology.org/cgi/collection/clinical_neurology_examination">http://n.neurology.org/cgi/collection/clinical_neurology_examination</a> <b>Clinical neurology history</b> <a href="http://n.neurology.org/cgi/collection/clinical_neurology_history">http://n.neurology.org/cgi/collection/clinical_neurology_history</a> <b>Optic nerve</b> <a href="http://n.neurology.org/cgi/collection/optic_nerve">http://n.neurology.org/cgi/collection/optic_nerve</a>
<b>Permissions &amp; Licensing</b>	Information about reproducing this article in parts (figures, tables) or in its entirety can be found online at: <a href="http://www.neurology.org/about/about_the_journal#permissions">http://www.neurology.org/about/about_the_journal#permissions</a>
<b>Reprints</b>	Information about ordering reprints can be found online: <a href="http://n.neurology.org/subscribers/advertise">http://n.neurology.org/subscribers/advertise</a>

*Neurology*® is the official journal of the American Academy of Neurology. Published continuously since 1951, it is now a weekly with 48 issues per year. Copyright © 2022 American Academy of Neurology. All rights reserved. Print ISSN: 0028-3878. Online ISSN: 1526-632X.

