

Pearls & Oy-sters: Vibration-Induced Downbeat Nystagmus: A New Cerebellar Sign Observed in Paraneoplastic Syndrome

Hyo-Jung Kim, PhD, Hyun-Jae Kim, MD, Jong-Hee Lee, MSc, and Ji-Soo Kim, MD, PhD

Neurology® 2023;100:43-46. doi:10.1212/WNL.0000000000201466

Correspondence

Dr. Kim
jisookim@snu.ac.kr

Abstract

Vibratory stimulation of the sternocleidomastoid muscles or the skull may enhance vestibular asymmetry and evoke nystagmus. We report prominent downbeating vibration-induced nystagmus (VIN) in a patient with paraneoplastic cerebellar degeneration due to cervical cancer with positive serum anti-Ri antibody. A 47-year-old woman developed spontaneous upbeat nystagmus present with and without visual fixation. Nystagmus decreased during lateral and upward gaze. Downbeat nystagmus emerged during convergence and after horizontal head shaking for approximately 15 seconds and during vibratory stimulation of the mastoids and forehead. Additional findings included positional downbeat nystagmus, impaired smooth pursuit, hypermetric horizontal saccades, and truncal ataxia. During video-head impulse tests, the gains of the vestibulo-ocular reflex (VOR) were normal for both horizontal semicircular canals but increased for both anterior canals and decreased for both posterior canals. Horizontal head impulses produced cross-coupled downward corrective saccades. Given the asymmetric vertical VOR, downbeat VIN observed in our patient may be ascribed to enhanced upward bias of the VOR due to vestibulocerebellar dysfunction during the vibratory stimuli. Vibration-induced downbeat nystagmus should be added to the list of central vestibular signs and is likely due to cerebellar dysfunction.

MORE ONLINE

 **Video**

Pearls

- Vibratory stimulus on the skull may induce nystagmus or augment spontaneous nystagmus by stimulating the vestibular end organs.
- Vibration-induced downbeat nystagmus should be in the differential diagnosis for central vestibular signs and is likely due to cerebellar dysfunction.

Oy-sters

- In unilateral peripheral vestibulopathy, skull vibration mostly induces contralesional nystagmus.
- Vibration-induced downbeat nystagmus may occur in cerebellar dysfunction due to vestibular asymmetry in the vertical plane.

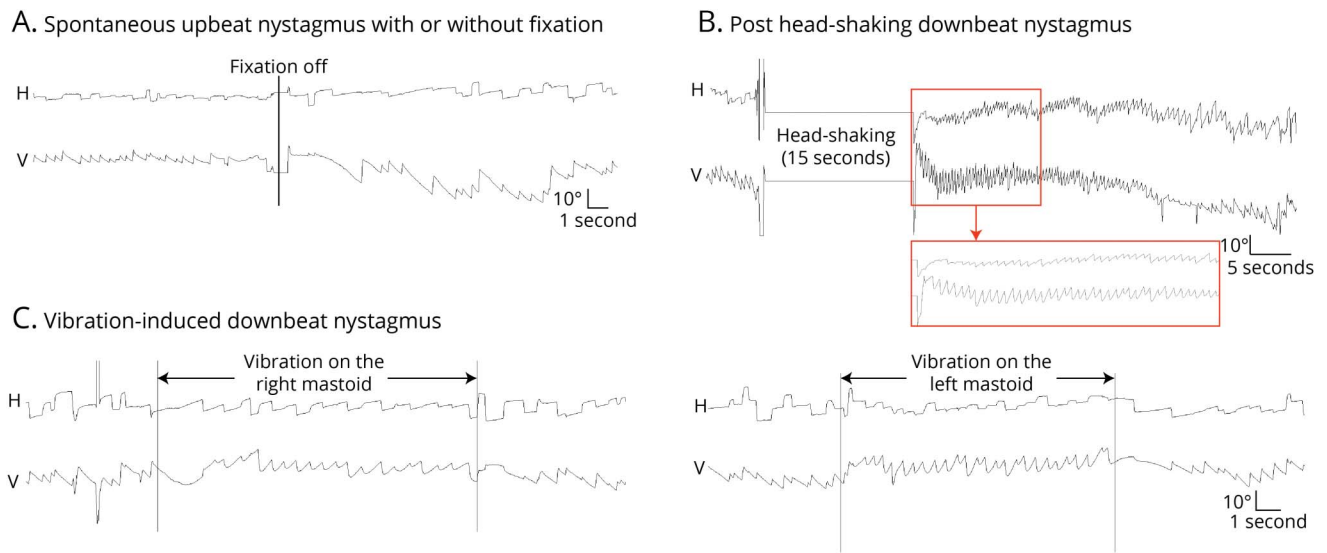
Case Report

A 47-year-old woman with uterine cervix cancer with peritoneal metastasis and positive serum anti-Ri antibody had suffered from dizziness and imbalance for several months. On examination, she was alert and well-oriented. Extraocular evaluation showed spontaneous upbeat nystagmus with a decreasing slow phase velocity either with or without visual fixation (Video 1, Figure 1A). The upbeat nystagmus decreased during the lateral and upward gazes and increased

From the Research Administration Team (Hyo-Jung Kim), Seoul National University Bundang Hospital, Seongnam, Korea; Department of Neurology (Hyun-Jae Kim), Chungbuk National University Hospital, Cheongju, Korea; Dizziness Center (J.-H.L., J.-S.K.), Clinical Neuroscience Center, Seoul National University Bundang Hospital, Seongnam, Korea; and Department of Neurology (J.-S.K.), Seoul National University College of Medicine, Korea.

Go to [Neurology.org/N](https://www.neurology.org/N) for full disclosures. Funding information and disclosures deemed relevant by the authors, if any, are provided at the end of the article.

Figure 1 Recording of Nystagmus Using Video-Oculography



Video-oculography (SLVNG, SLMED, Seoul Korea) shows spontaneous upbeat nystagmus with a decreasing slow phase velocity either with or without visual fixation (A), which changes into downbeat after horizontal head-shaking for about 15 seconds (B) and during vibratory stimuli (100 Hz) on either mastoid (C). H: horizontal, V: vertical.

during downward gaze. Upbeat nystagmus changed into downbeat nystagmus during convergence (Video 2), after horizontal head-shaking for about 15 seconds (Video 3, Figure 1B), and during vibratory stimulation (100 Hz) of the forehead, mastoid, and sternocleidomastoid (SCM, Video 4, Figure 1C). Downbeat vibration-induced nystagmus (VIN) was not suppressed by visual fixation. Paroxysmal downbeat nystagmus was also induced by lying down, straight head hanging, and Dix-Hallpike maneuver on either side while apogeotropic nystagmus was evoked by head turning to either side while supine. Additional findings included impaired smooth pursuit bilaterally and upward, hypermetric horizontal saccades, and truncal ataxia. On video head impulse tests (HITs), the gains of the vestibulo-ocular reflex (VOR) were normal for the horizontal semicircular canals on both sides but increased for both anterior canals and decreased for both posterior canals (Figure 2). Horizontal head impulses also produced cross-coupled responses: upward deflection of the eyes and downward corrective saccades (Video 5). There was no evidence of ocular tilt reaction or abnormal tilt of the subjective visual vertical. Brain MRI was normal. The dizziness and ataxia did not respond to corticosteroid pulse, intravenous immunoglobulin, and other medications including baclofen and gabapentin.

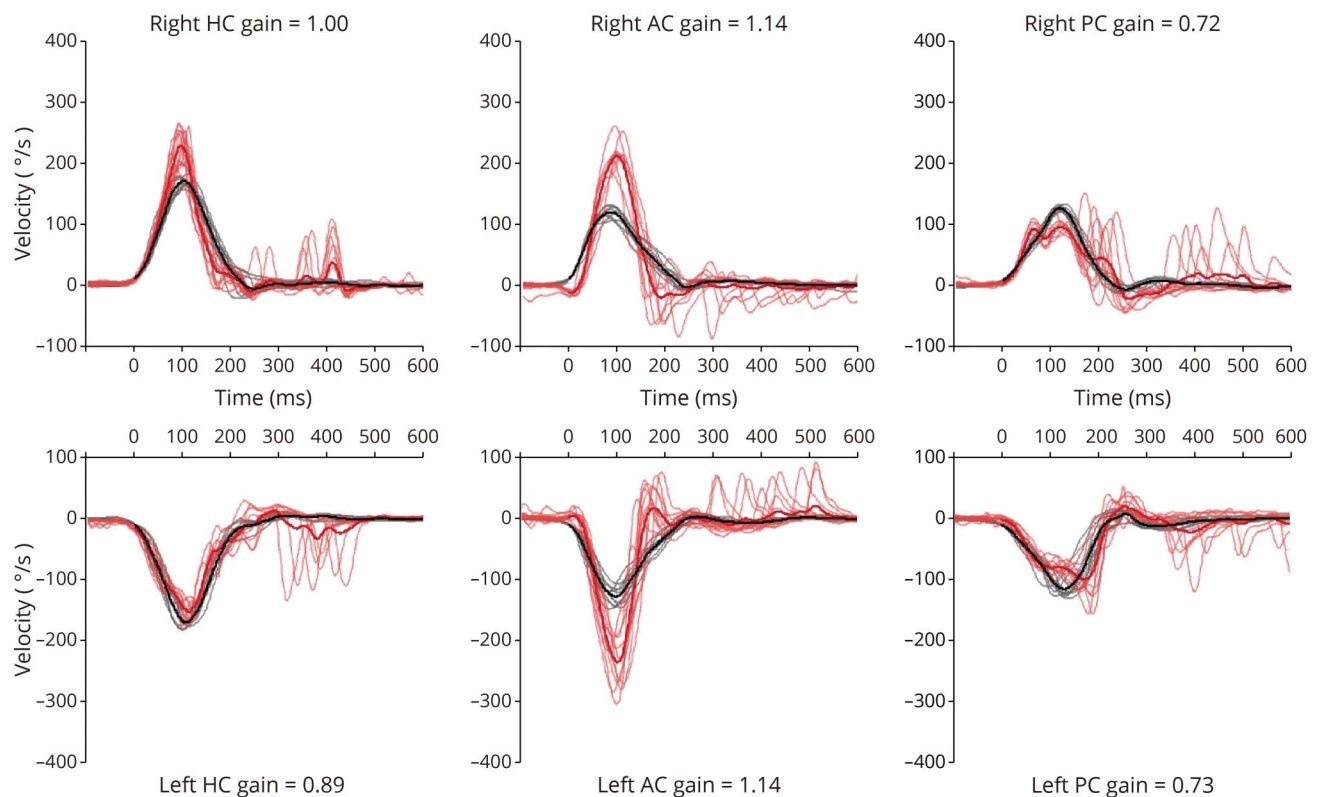
Discussion

Our patient with paraneoplastic cerebellar degeneration (PCD) and serum anti-Ri antibody in association with uterine cervix cancer showed a reversal of spontaneous upbeat into

downbeat nystagmus during vibratory stimulation of the mastoids, forehead, and SCM.

Vibratory stimulation of the SCM or skull may enhance the vestibular asymmetry and evoke nystagmus.¹ This VIN mostly beats toward the healthy or less affected ear in unilateral or asymmetric peripheral vestibulopathy.^{1,2} In guinea pigs, skull vibration evoked phase-locked responses in 82.8% of the irregular otolithic afferents, 14.1% of the regular otolithic afferents, and 4.7% of the canal neurons.³ Bone-conducted skull vibration at 500 Hz is known to stimulate the otolithic receptor cells selectively, while the vibration at 100 Hz can activate both the otolith and semicircular canal afferents.^{4,5} Therefore, skull vibration especially at 100 Hz can effectively trigger nystagmus by activating the irregular vestibular receptors.^{4,5} Vibration applied to the skull or SCM is an effective way of stimulating the vestibular receptors and leads to phase-locked activation of the irregular vestibular afferents from both ears.⁴ In unilateral or asymmetric vestibular deficit, vibration of the skull or SCM generally induces contralesional horizontal or horizontal-torsional nystagmus or augments spontaneous contralesional nystagmus.^{4,6} VIN is positive in 93–100% of patients with severe to total unilateral vestibular loss and in 58–60% of patients with a partial deficit.^{4,6} By contrast, horizontal VIN has rarely been observed in central lesions, only in 13% of patients with vestibular migraine and 12.5% of patients with central vertigo of various etiologies.⁶ Predominant downbeat VIN is extremely rare. It has been described in a patient with Wernicke encephalopathy.⁷ Our patient showed reversal of spontaneous upbeat into

Figure 2 Video-Head Impulse Tests



During video-HITs, the gains of the vestibulo-ocular reflex were normal for the horizontal semicircular canals (HC) on both sides ($0.85 \leq$ normal range for HC ≤ 1.03) but increased for both anterior canals (AC, $0.94 \leq$ normal range for AC ≤ 1.06) and decreased for both posterior canals (PC, $0.89 \leq$ normal range for PC ≤ 1.05). Red lines: eye velocity, black lines: head velocity.

downbeat nystagmus. Previously, reversal of spontaneous horizontal nystagmus was reported during vibratory stimuli only in lateral medullary infarction.⁸

What is the mechanism of vibration-induced downbeat nystagmus in our patient? The hypermetric saccade, central positional nystagmus (downbeat and apogeotropic nystagmus), perverted head-shaking nystagmus, increased VOR gain for the anterior semicircular canals during HITs, and perverted response during horizontal HITs are abnormal eye movements coexisted in our patient. These eye movements are characteristic of those observed in cerebellar dysfunction, including PCD.^{9,10}

Several mechanisms have been advanced for vertical nystagmus and include asymmetry in the vertical VOR, imbalance of inputs from the otoliths, dysfunction of the neural integrator involved in vertical gaze holding, and impaired upward smooth pursuit.^{7,11} Our patient showed spontaneous upbeat nystagmus with a decreasing slow phase velocity, which suggests that there may have been impaired neural integrator function as the mechanism of upbeat nystagmus.^{12,13} By contrast, the vibration-induced downbeat nystagmus had a linear slow phase, which indicates a mechanism different from that for spontaneous upbeat nystagmus. Given the increased gain of the VOR for the anterior canals and decreased gain of

the VOR for the posterior canals during the vertical HITs, the vibration-induced downbeat nystagmus can be reasonably explained by enhanced upward bias of the VOR due to vestibulocerebellar dysfunction during the vibratory stimuli.^{4,14} Vibration-induced downbeat nystagmus should be added to the list of central vestibular signs, probably due to cerebellar dysfunction.

Study Funding

This study was supported by the National Research Foundation of Korea (NRF) grant funded by the Ministry of Science and ICT (No. NRF-2021R1F1A1063826).

Disclosure

J.-S. Kim serves as an Associate Editor of *Frontiers in Neurology* and on the editorial boards of the *Journal of Clinical Neurology*, *Frontiers in Neuro-ophthalmology*, *Journal of Neuro-ophthalmology*, and *Journal of Vestibular Research*, *Journal of Neurology and Medicine*. The other authors have nothing relevant to disclose. Go to [Neurology.org/N](https://www.neurology.org/N) for full disclosures.

Publication History

Received by *Neurology* June 2, 2022. Accepted in final form September 9, 2022. Submitted and externally peer reviewed. The handling editor was Roy Strowd III, MD, Med, MS.

Appendix Authors

Name	Location	Contribution
Hyo-Jung Kim, PhD	Seoul National University Bundang Hospital, Seongnam, Korea	Acquired and analyzed the data, and drafted the manuscript
Hyun-Jae Kim, MD	Chungbuk National University Hospital, Cheongju, Korea	Interpreted the data and made a critical revision of the manuscript
Jong-Hee Lee, MSc	Seoul National University Bundang Hospital, Seongnam, Korea	Interpreted the data and made a critical revision of the manuscript
Ji-Soo Kim, MD, PhD	Seoul National University Bundang Hospital, Seongnam, Korea	Conducted the design and conceptualization of the study, interpretation of the data, and revision of the manuscript

References

1. Kobayashi Y, Yagi T, Kamio T. Cervico-vestibular interaction in eye movements. *Auris Nasus Larynx* 1986;13(suppl 2):S87-S95.
2. Karlberg M, Aw ST, Black RA, Todd MJ, MacDougall HG, Halmagyi GM. Vibration-induced ocular torsion and nystagmus after unilateral vestibular deafferentation. *Brain* 2003;126(Pt 4):956-964.
3. Curthoys IS, Kim J, McPhedran SK, Camp AJ. Bone conducted vibration selectively activates irregular primary otolithic vestibular neurons in the Guinea pig. *Exp Brain Res*. 2006;175(2):256-267.
4. Curthoys IS. The neural basis of skull vibration induced nystagmus (SVIN). *Audiol Res*. 2021;11(4):557-566.
5. Długaczyc J, Burgess AM, Curthoys IS. Activation of Guinea pig irregular semicircular canal afferents by 100 Hz vibration: clinical implications for vibration-induced nystagmus and vestibular-evoked myogenic potentials. *Otol Neurotol* 2020;41(7):e961-e970.
6. Waissbluth S, Sepulveda V. The skull vibration-induced nystagmus test (svint) for vestibular disorders: a systematic review. *Otol Neurotol* 2021;42(5):646-658.
7. Leigh RJ, Zee DS. *The Neurology of Eye Movements*. Oxford University Press; 2015.
8. Choi KD, Oh SY, Park SH, Kim JH, Koo JW, Kim JS. Head-shaking nystagmus in lateral medullary infarction: patterns and possible mechanisms. *Neurology* 2007; 68(17):1337-1344.
9. Wray SH, Dalmau J, Chen A, King S, Leigh RJ. Paraneoplastic disorders of eye movements. *Ann N Y Acad Sci*. 2011;1233:279-284.
10. Baloh RW. Paraneoplastic cerebellar disorders. *Otolaryngol Head Neck Surg*. 1995; 112(1):125-127.
11. Kim JS, Kim TL, Kim KC, et al. S-Adenosylmethionine decarboxylase partially regulates cell growth of HL-60 cells by controlling the intracellular ROS level: early senescence and sensitization to gamma-radiation. *Arch Biochem Biophys* 2006;456(1):58-70.
12. Janssen JC, Larner AJ, Morris H, Bronstein AM, Farmer SF. Upbeat nystagmus: clinicoanatomical correlation. *J Neurol Neurosurg Psychiatry* 1998;65(3):380-381.
13. Zee DS, Friendlich AR, Robinson DA. The mechanism of downbeat nystagmus. *Arch Neurol*. 1974;30(3):227-237.
14. Walker MF, Zee DS. Asymmetry of the pitch vestibulo-ocular reflex in patients with cerebellar disease. *Ann N Y Acad Sci*. 2005;1039:349-358.

Share Your Artistic Expressions in Neurology ‘Visions’

AAN members are urged to submit medically or scientifically related artistic images, such as photographs, photomicrographs, and paintings, to the “Visions” section of *Neurology*®. These images are creative in nature, rather than the medically instructive images published in the NeuroImages section. The image or series of up to six images may be black and white or color and must fit into one published journal page. Accompanying description should be 100 words or less; the title should be a maximum of 140 characters including spaces and punctuation.

Please access the Author Center at [NPub.org/authors](https://www.npub.org/authors) for full submission information.

Call for Voices: Lived Experiences

The Editor of the *Neurology* specialty section Inclusion, Diversity, Equity, Anti-racism, & Social Justice (IDEAS) encourages you to submit short first-person accounts (1,000 words or less) of experiences lived within the realm of IDEAS with the goal of informing and enlightening our community on these critical issues. Some topics to consider include, but are not limited to:

- Descriptions of personal experiences that shaped your views of IDEAS.
- Reflections on the intersection between personal identity and career.
- Discussions at the intersection of IDEAS and neurology patient care, research, education, advocacy, or policy.

Submit your contributions to journal@neurology.org and include “Voices Submission” in the subject line.

Neurology®

Pearls & Oy-sters: Vibration-Induced Downbeat Nystagmus: A New Cerebellar Sign Observed in Paraneoplastic Syndrome

Hyo-Jung Kim, Hyun-Jae Kim, Jong-Hee Lee, et al.

Neurology 2023;100:43-46 Published Online before print October 3, 2022

DOI 10.1212/WNL.0000000000201466

This information is current as of October 3, 2022

Updated Information & Services	including high resolution figures, can be found at: http://n.neurology.org/content/100/1/43.full
References	This article cites 13 articles, 2 of which you can access for free at: http://n.neurology.org/content/100/1/43.full#ref-list-1
Subspecialty Collections	This article, along with others on similar topics, appears in the following collection(s): All Neurotology http://n.neurology.org/cgi/collection/all_neurotology Vertigo http://n.neurology.org/cgi/collection/vertigo
Permissions & Licensing	Information about reproducing this article in parts (figures, tables) or in its entirety can be found online at: http://www.neurology.org/about/about_the_journal#permissions
Reprints	Information about ordering reprints can be found online: http://n.neurology.org/subscribers/advertise

Neurology® is the official journal of the American Academy of Neurology. Published continuously since 1951, it is now a weekly with 48 issues per year. Copyright © 2022 American Academy of Neurology. All rights reserved. Print ISSN: 0028-3878. Online ISSN: 1526-632X.

