

Neurology Publish Ahead of Print
DOI: 10.1212/WNL.0000000000207463

Teaching NeuroImage: Olfactory Stem Cell Injection Inducing Actively Secreting Respiratory Epithelium in a Cervical Syrx

Author(s):

Juliana Rotter, MD¹; Rahul Kumar, MD, PhD¹; Cody L. Nesvick, MD¹; William E. Krauss, MD¹; Caterina
Giannini, MD, PhD²; William O Tobin³

Corresponding Author:

William O Tobin, tobin.oliver@mayo.edu

Affiliation Information for All Authors: 1. Department of Neurologic Surgery, Mayo Clinic, Rochester, MN; 2. Department of Pathology, Mayo Clinic, Rochester, MN; 3. Department of Neurology, Mayo Clinic, Rochester, MN.

Equal Author Contribution:

Contributions:

Juliana Rotter: Drafting/revision of the manuscript for content, including medical writing for content;
Major role in the acquisition of data; Additional contributions: Obtaining patient consent

Rahul Kumar: Drafting/revision of the manuscript for content, including medical writing for content;
Major role in the acquisition of data

Cody L. Nesvick: Drafting/revision of the manuscript for content, including medical writing for content;
Major role in the acquisition of data

William E. Krauss: Drafting/revision of the manuscript for content, including medical writing for content; Study concept or design; Analysis or interpretation of data

Caterina Giannini: Drafting/revision of the manuscript for content, including medical writing for content; Analysis or interpretation of data

William Oliver Tobin: Drafting/revision of the manuscript for content, including medical writing for content; Study concept or design; Analysis or interpretation of data

Figure Count:

2

Table Count:

0

Search Terms:

[135] All Infections, [255] Spinal cord trauma; see Trauma/spinal cord trauma (S), [256] Spinal cord infection, [266] Spinal cord trauma

Acknowledgment:

Study Funding:

The authors report no targeted funding.

Disclosure:

The authors report no relevant disclosures.

Preprint DOI:

Received Date:

2022-08-05

Accepted Date:

2023-04-13

Handling Editor Statement:

Submitted and externally peer reviewed. The handling editor was Resident and Fellow Section Editor Whitley Aamodt, MD, MPH.

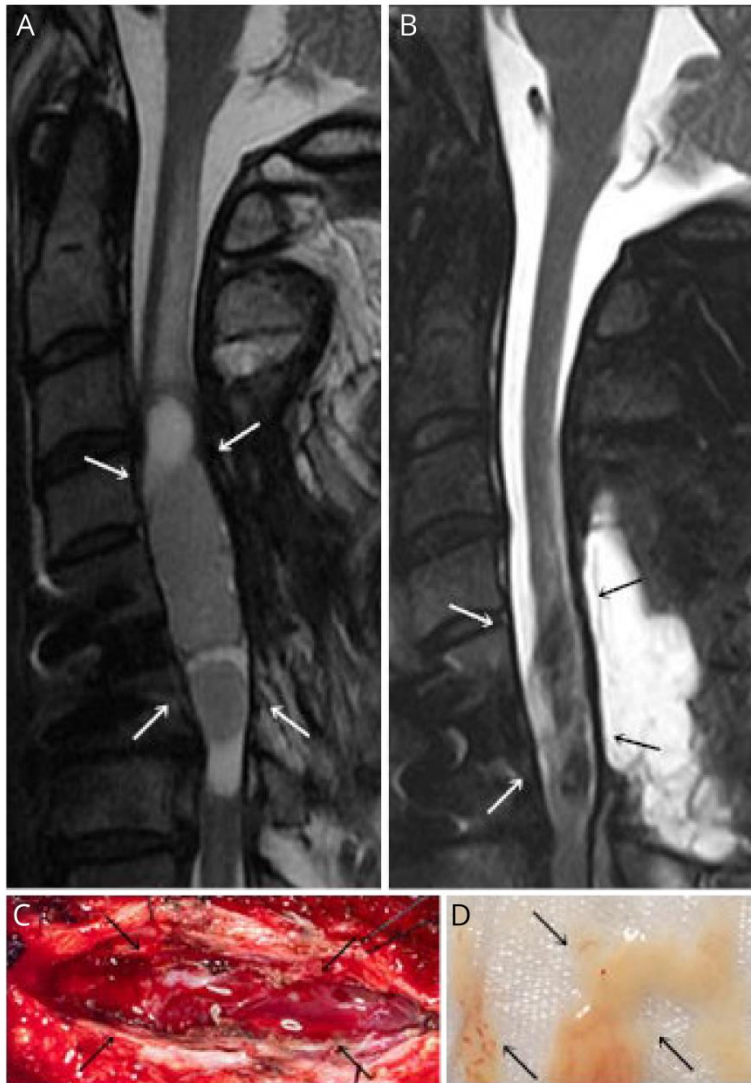
A 46-year-old man suffered a complete C6 spinal cord injury with minimal recovery. Two years later, he underwent olfactory stem cell injection into the cervical post-traumatic syrinx but developed progressive weakness. A C5 syringo-subarachnoid shunt was placed, but his strength declined further, so he underwent syrinx evacuation. Upon dural opening, white gelatinous material exuded under pressure (Figure 1). Pockets of similar material were evacuated. Pathology identified respiratory epithelium and seromucinous glands within fibrous stroma (Figure 2). Within four months, he re-gained deltoid and bicep function.

Olfactory stem cells have been proposed as an experimental treatment for functional improvement following traumatic spinal cord injury; intrathecal administration improved function in one patient.¹ Although mesenchymal stromal cell injection in syrinx has shown promise in reducing syrinx size and improving function, careful monitoring is needed for potential side effects.²

WNL-2023-000296_slides -- <http://links.lww.com/WNL/C952>

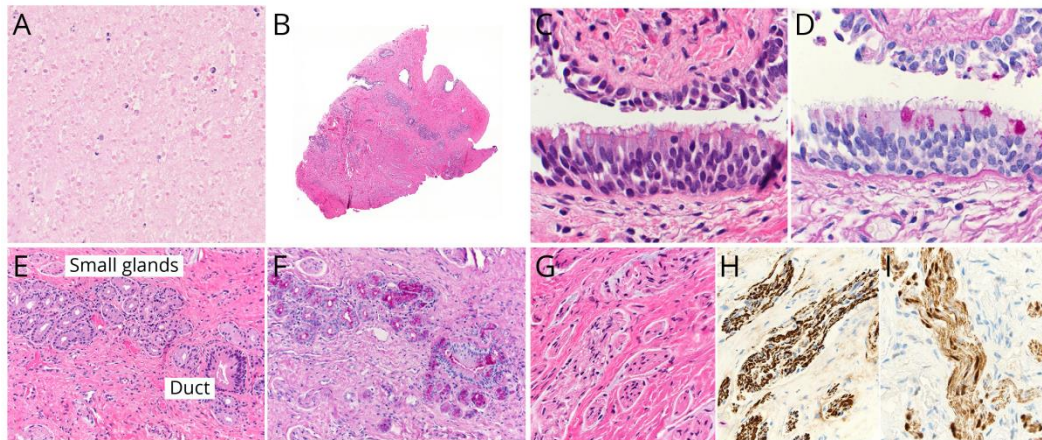
1. Zamani H, Soufizomorrod M, Oraee-Yazdani S, Naviafar D, et al. Safety and feasibility of autologous olfactory ensheathing cell and bone marrow mesenchymal stem cell co-transplantation in chronic human spinal cord injury: A clinical trial. *Spinal Cord* 2022;60:63-70.
2. Vaquero J, Hassan R, Fernández C, et al. Cell therapy as a new approach to the treatment of posttraumatic syringomyelia. *World Neurosurgery* 2017;107:1047-e5.

Figure 1. MRI and Intraoperative Photographs



(A) Preoperative and (B) postoperative sagittal MRI with arrows highlighting complex syrinx. Intraoperative photograph of (C) syrinx cavity and (D) mucinous syrinx material.

Figure 2. Pathology of the Lesion



(A) Amorphous nasal secretion x200; (B) cyst wall highlighting ciliated respiratory mucosa in upper left box, small seromucinous gland in upper right box, small nerve twigs in lower right box; (C) H&E x400, (D) PAS of ciliated respiratory mucosa with goblet cells x400; (E) H&E x200, (F) PAS showing small seromucinous gland, duct x200; (G) S100 showing small nerve twigs in dense fibrous tissue with axons, Schwann cells x400; (H) neurofilament x400; (I) S100 showing Schwann cells x400.

ACCEPTED

Neurology®

Teaching NeuroImage: Olfactory Stem Cell Injection Inducing Actively Secreting Respiratory Epithelium in a Cervical Syrinx

Juliana Rotter, Rahul Kumar, Cody L. Nesvick, et al.

Neurology published online July 3, 2023

DOI 10.1212/WNL.0000000000207463

This information is current as of July 3, 2023

Updated Information & Services	including high resolution figures, can be found at: http://n.neurology.org/content/early/2023/07/03/WNL.0000000000207463.citation.full
Subspecialty Collections	This article, along with others on similar topics, appears in the following collection(s): All Infections http://n.neurology.org/cgi/collection/all_infections Spinal cord infection http://n.neurology.org/cgi/collection/spinal_cord_infection Spinal cord trauma http://n.neurology.org/cgi/collection/spinal_cord_trauma Spinal cord trauma; see Trauma/spinal cord trauma http://n.neurology.org/cgi/collection/spinal_cord_trauma-see_trauma-spinal_cord_trauma
Permissions & Licensing	Information about reproducing this article in parts (figures, tables) or in its entirety can be found online at: http://www.neurology.org/about/about_the_journal#permissions
Reprints	Information about ordering reprints can be found online: http://n.neurology.org/subscribers/advertise

Neurology® is the official journal of the American Academy of Neurology. Published continuously since 1951, it is now a weekly with 48 issues per year. Copyright © 2023 American Academy of Neurology. Unauthorized reproduction of this article is prohibited. All rights reserved. Print ISSN: 0028-3878. Online ISSN: 1526-632X.

