

# Teaching NeuroImage: A Rare Pediatric Case of Diffuse Leptomeningeal Glioneuronal Tumor

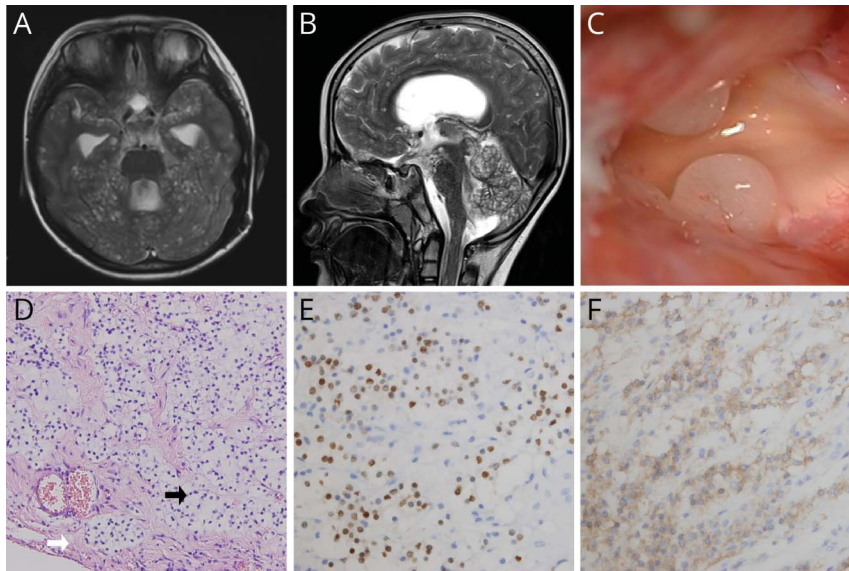
Mading Zhou, MD, Peng Sun, MD, and Gao Zeng, MD

*Neurology*® 2022;99:399-400. doi:10.1212/WNL.0000000000200934

## Correspondence

Dr. Zeng  
zengrogoss@163.com

## Figure MRI, Intraoperative Image, and Histopathology of DLGNT



T2-weighted image showed cystic lesions diffusely scattered throughout the brain surface (A, B) and were confirmed by the intraoperative image (C). Hematoxylin and eosin staining (D,  $\times 100$ ) showed leptomeninges (white arrow) infiltrated by oligodendroglia-like tumor cells (black arrow) and were immunopositive for Olig2 (E,  $\times 400$ ) and synaptophysin (F,  $\times 400$ ). DLGNT = diffuse leptomeningeal glioneuronal tumor.

A 6-year-old boy, with an unremarkable birth history and developmental history notable only for intellectual disability, developed expressive aphasia and intermittent vomiting in 3 weeks. Brain MRI showed communicating hydrocephalus and characteristic diffuse subpial cystic lesions throughout the surface (Figure). His symptom of vomiting was relieved after he was given a ventricular-peritoneal shunt (valve pressure set as 140 mm H<sub>2</sub>O) and meningeal-cortical biopsy. The final diagnosis was diffuse leptomeningeal glioneuronal tumor, a new entity in the 2016 WHO classification of CNS tumors.<sup>1</sup> He was referred to a local oncology center because chemotherapy had been proposed as first-line treatment.<sup>2</sup>

## Study Funding

No targeted funding reported.

## Disclosure

The authors report no relevant disclosures. Go to [Neurology.org/N](https://www.neurology.org/N) for full disclosures.

## MORE ONLINE

### Teaching slides

[links.lww.com/WNL/C141](https://links.lww.com/WNL/C141)

From the Department of Neurosurgery, Xuanwu Hospital, Capital Medical University, Beijing, China.

Go to [Neurology.org/N](https://www.neurology.org/N) for full disclosures. Funding information and disclosures deemed relevant by the authors, if any, are provided at the end of the article.

## Publication History

Received by *Neurology* November 22, 2021. Accepted in final form May 19, 2022. Submitted and externally peer reviewed. The handling editor was Roy Strowd III, MD, MEd, MS.

## Appendix Authors

Name	Location	Contribution
<b>Mading Zhou, MD</b>	Department of Neurosurgery, Xuanwu Hospital, Capital Medical University, Beijing, China	Drafting/revision of the manuscript for content, including medical writing for content
<b>Peng Sun, MD</b>	Department of Neurosurgery, Xuanwu Hospital, Capital Medical University, Beijing, China	Major role in the acquisition of data

## Appendix (continued)

Name	Location	Contribution
<b>Gao Zeng, MD</b>	Department of Neurosurgery, Xuanwu Hospital, Capital Medical University, Beijing, China	Study concept or design and analysis or interpretation of data

## References

1. Louis DN, Perry A, Reifenberger G, et al. The 2016 World Health Organization classification of tumors of the central nervous system: a summary. *Acta Neuropathol.* 2016;131(6):803-820.
2. Aguilera D, Castellino RC, Janss A, et al. Clinical responses of patients with diffuse leptomeningeal glioneuronal tumors to chemotherapy. *Childs Nerv Syst.* 2018;34(2):329-334.

## Call for Voices: Lived Experiences

The Editor of the *Neurology* specialty section Inclusion, Diversity, Equity, Anti-racism, & Social Justice (IDEAS) encourages you to submit short first-person accounts (1,000 words or less) of experiences lived within the realm of IDEAS with the goal of informing and enlightening our community on these critical issues. Some topics to consider include, but are not limited to:

- Descriptions of personal experiences that shaped your views of IDEAS.
- Reflections on the intersection between personal identity and career.
- Discussions at the intersection of IDEAS and neurology patient care, research, education, advocacy, or policy.

Submit your contributions to [journal@neurology.org](mailto:journal@neurology.org) and include "Voices Submission" in the subject line.

## Visit the *Neurology*<sup>®</sup> Resident & Fellow Website

Click on Residents & Fellows tab at [Neurology.org](http://Neurology.org).

Now offering:

- *Neurology* Resident & Fellow Editorial team information
- "Search by subcategory" option
- E-Pearl of the Week
- Direct links to Career Planning and AAN Resident & Fellow Pages
- Recently published Resident & Fellow articles
- Commentaries by Editors and Resident & Fellow team members

 Find *Neurology* Residents & Fellows Section on Facebook: [facebook.com/AANResidentsAndFellows](https://facebook.com/AANResidentsAndFellows)

 Follow *Neurology* on Twitter: [@GreenJournal](https://twitter.com/GreenJournal) #NeurologyRF

 Find *Neurology* Residents & Fellows Section on Instagram: [@aanbrain](https://www.instagram.com/aanbrain) #NeurologyRF

# Neurology®

## Teaching NeuroImage: A Rare Pediatric Case of Diffuse Leptomeningeal Glioneuronal Tumor

Mading Zhou, Peng Sun and Gao Zeng

*Neurology* 2022;99:399-400 Published Online before print June 17, 2022

DOI 10.1212/WNL.0000000000200934

**This information is current as of June 17, 2022**

<b>Updated Information &amp; Services</b>	including high resolution figures, can be found at: <a href="http://n.neurology.org/content/99/9/399.full">http://n.neurology.org/content/99/9/399.full</a>
<b>References</b>	This article cites 2 articles, 0 of which you can access for free at: <a href="http://n.neurology.org/content/99/9/399.full#ref-list-1">http://n.neurology.org/content/99/9/399.full#ref-list-1</a>
<b>Subspecialty Collections</b>	This article, along with others on similar topics, appears in the following collection(s): <b>All Oncology</b> <a href="http://n.neurology.org/cgi/collection/all_oncology">http://n.neurology.org/cgi/collection/all_oncology</a> <b>All Pediatric</b> <a href="http://n.neurology.org/cgi/collection/all_pediatric">http://n.neurology.org/cgi/collection/all_pediatric</a> <b>MRI</b> <a href="http://n.neurology.org/cgi/collection/mri">http://n.neurology.org/cgi/collection/mri</a> <b>Primary brain tumor</b> <a href="http://n.neurology.org/cgi/collection/primary_brain_tumor">http://n.neurology.org/cgi/collection/primary_brain_tumor</a>
<b>Permissions &amp; Licensing</b>	Information about reproducing this article in parts (figures, tables) or in its entirety can be found online at: <a href="http://www.neurology.org/about/about_the_journal#permissions">http://www.neurology.org/about/about_the_journal#permissions</a>
<b>Reprints</b>	Information about ordering reprints can be found online: <a href="http://n.neurology.org/subscribers/advertise">http://n.neurology.org/subscribers/advertise</a>

*Neurology*® is the official journal of the American Academy of Neurology. Published continuously since 1951, it is now a weekly with 48 issues per year. Copyright © 2022 American Academy of Neurology. All rights reserved. Print ISSN: 0028-3878. Online ISSN: 1526-632X.

