

Clinical Reasoning: A 68-Year-Old Man With Palmar Rash, Leg Pain, and Inability to Walk

Joseph YoungHun Yoon, MD, MSc, MAEd, Jacqueline Madeleine Solomon, MD, Yijia Li, MD, and Sashank Prasad, MD

Neurology[®] 2022;99:347-353. doi:10.1212/WNL.0000000000200933

Correspondence

Dr. Yoon
jyoon@mgh.harvard.edu

Abstract

We report a 68-year-old man with palmar rash, leg pain, and inability to walk, whose neurologic examination localized to multiple roots, leading to the diagnosis of polyradiculopathy. Polyradiculopathy has both structural and nonstructural etiologies. Structural etiologies include spinal stenosis, tethered cord syndrome, tumors, and leptomeningeal metastasis. Nonstructural etiologies include inflammatory, infectious, metabolic, and other neoplastic processes. His palmar rash in conjunction with neurologic signs/symptoms raised the suspicion for an infectious etiology, and eventually, serology and lumbar puncture confirmed the final diagnosis. In this report, we will further discuss how we determined the localization of polyradiculopathy, its specific etiologies, management decisions, and a transient complication before he achieved a significant improvement at 6 months.

From the Department of Neurology (J.Y.H.Y., J.M.S.), Massachusetts General Hospital, and Department of Neurology (J.Y.H.Y., J.M.S., S.P.), Brigham and Women's Hospital, Harvard Medical School, Boston, MA; Division of Neurology (J.M.S.), Department of Medicine, Hamilton Health Sciences, McMaster University, Hamilton, Ontario, Canada; and Division of Infectious Disease (Y.L.), Department of Medicine, Brigham and Women's Hospital, Harvard Medical School, Boston, MA. Dr. Yoon is currently at the Department of Neurosurgery, The Mount Sinai Hospital, New York, NY.

Go to [Neurology.org/N](https://www.neurology.org/N) for full disclosures. Funding information and disclosures deemed relevant by the authors, if any, are provided at the end of the article.

Section 1

A 68-year-old man with medical history significant for coronary artery disease, type 2 diabetes mellitus, hypertension, and hyperlipidemia presented with bilateral leg pain and weakness. At baseline, he was very active, walking 3–4 miles a day. Three weeks before the presentation, he developed diffuse lower extremity muscle and joint pain, which “felt like a massage.” Within 3 days, his pain had progressed to significant burning and achy quality in both legs, interfering with sleep. Two weeks after onset, he presented to a local emergency room for this pain. Hip x-ray and ultrasound were unremarkable, and he was discharged on prednisone 20 mg daily. Despite this, his pain persisted, and new weakness developed in both legs. He started using a cane within 3 weeks, fell while walking on the street, and could not stand up afterward, which prompted his hospitalization. There was no change in his bowel or bladder function. His examination revealed normal mental status and cranial nerves. A more detailed motor examination showed normal strengths in bulbar muscles, deltoids, biceps, triceps, and gastrocnemius,

but varying degree of weakness of the following muscle groups (right/left; Medical Research Council grades): abductor pollicis brevis (4/4), first dorsal interosseous (4/4), abductor digiti minimi (4/4), finger extensors (4/4), hip flexors (3+/3), hip abductors (3+/3), knee flexors (4/3+), knee extensors (4/4), tibialis anterior (4/3), tibialis posterior (4/4), and peroneus longus and brevis (4+/4). His proprioceptive and vibratory sensation was absent in his toes and ankles bilaterally, but there was neither saddle anesthesia nor sensory level. Tendon reflexes were 2+ in his arms but absent at the knees and the ankles with mute plantar reflexes bilaterally. His stance and gait were wide based with small, cautious steps, requiring 2-person assistance. His postvoid bladder scan was within normal limits.

Questions for Consideration:

1. What is the localization for his presentation?
2. What other history or physical examination findings would you look for?
3. What is the differential diagnosis?

GO TO SECTION 2

Section 2

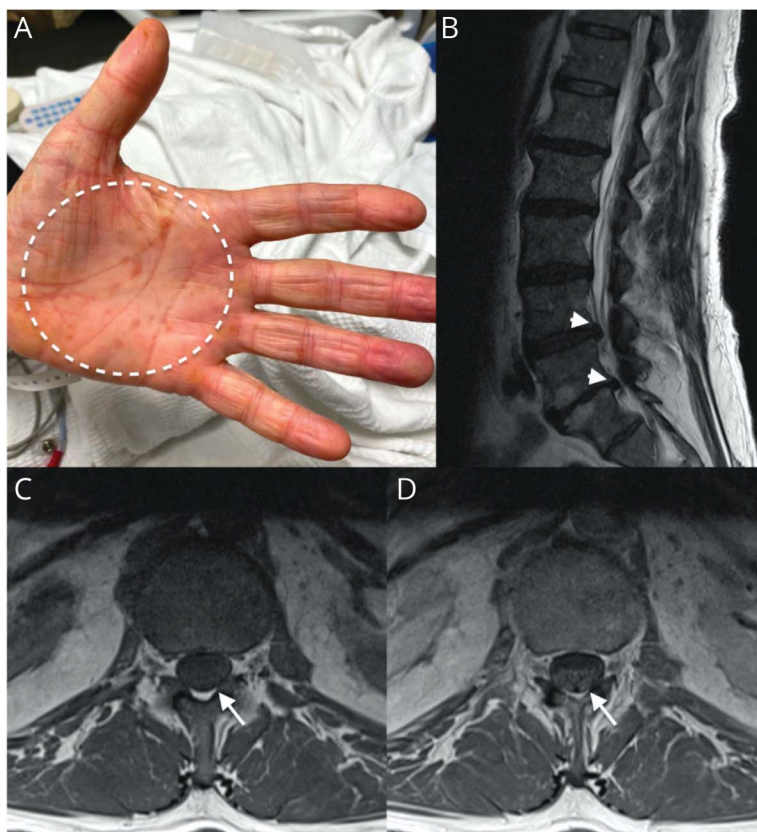
The progressive pain, weakness and sensory loss involving multiple myotomes, and diminished reflexes with lack of myelopathic signs in this patient are most consistent with polyradiculopathy, involving C8-T1 and diffuse lumbosacral levels. There are many etiologies of polyradiculopathy that can be divided into structural and nonstructural categories. Structural etiologies would include acquired spinal stenosis from causes such as ankylosing spondylitis, degenerative disk disease, primary tumors, leptomeningeal metastases, and tethered cord syndrome causing compression on the nerve roots. However, the absence of local pain and patchy involvement of upper and lower extremities make these less likely, given the pattern of weakness involving C8-T1 and diffuse lumbosacral levels. Nonstructural etiologies include infectious diseases, inflammatory disorders, metabolic processes, and neurolymphomatosis. Infectious etiologies were strongly considered at this time, including syphilis, Lyme disease, tuberculosis, varicella-zoster virus, HIV, and cytomegalovirus. Inflammatory conditions include neurosarcoidosis and acute and chronic inflammatory demyelinating polyneuropathy. Although his course was too slow for acute inflammatory demyelinating polyneuropathy that peaks within 3 weeks, his weakness in all extremities developed more rapidly than typical chronic inflammatory demyelinating polyneuropathy that progresses

over more than 8 weeks although its early stage may still be consistent. Given his stable diabetes, upper extremity involvement, and symmetric pain and weakness, diabetic amyotrophy remains less likely. The absence of constitutional symptoms or changes in bowel/bladder habits make neurolymphomatosis less likely.

Intriguingly, pain is usually not a prominent feature of most polyradiculopathies but when present may be suggestive of compressive, infectious, infiltrative, or inflammatory processes.¹ Therefore, risk factors for an immunocompromised status, including sexual history, possible infectious exposures, malignancy status, and medications, should be carefully investigated to modify the differential diagnosis accordingly. A thorough general examination, including skin inspection and lymph node palpation, can provide additional clues and should not be overlooked. Finally, other neuromuscular differential diagnoses should also be considered, including myopathies, neuromuscular junction disorders, and motor neuron diseases.

Additional history revealed that the patient had multiple male partners with no barrier protection and extensive tick exposure. He did not remember having chancre, erythema migrans, or other rashes. Yet, careful dermatologic examination revealed small, nontender, circular, erythematous macular rashes on his palms and soles (Figure 1A).

Figure 1 Patient's Palmar Rash and MRI of Lumbosacral Spine



The patient's palms had nontender, circular, erythematous blotches (A, dotted circle). Magnetic resonance imaging (MRI) of the lumbosacral spine from the local hospital revealed incidental degenerative changes, especially with disk protrusions, worst being the L5-S1 right posterior disk protrusion (B, white arrowheads). More importantly, there was smooth contrast enhancement of the cauda equina nerve roots (C-D, white arrows; C is axial T1 pre-contrast, while D is axial T1 post-contrast).

MRI of lumbosacral spine from the local hospital revealed smooth contrast enhancement of cauda equina nerve roots, without cord signal changes (Figure 1, B–D).

Questions for Consideration:

1. What additional testing is needed?
2. What would you look out for when starting treatment?

GO TO SECTION 3

Section 3

His initial Lyme and syphilis antibody screening tests were positive, but the rest of his initial laboratory results were unremarkable, with a stable hemoglobin A1c (7.4%). His expanded chemistry panel, thyroid-stimulating hormone, creatine kinase/aldolase, and serum protein electrophoresis were normal. Antinuclear antibodies, HIV screen and viral load, gonorrhea-chlamydia nucleic acid test, severe acute respiratory syndrome coronavirus 2 PCR, and blood cultures were all negative. Given the high suspicion for secondary syphilis with polyradiculitis, lumbar puncture was performed. CSF examination showed an opening pressure of 12 cmH₂O, mixed pleocytosis (80 nucleated cells/mm³ with 7 red blood cells/mm³, neutrophils 36%, lymphocytes 30%, and monocytes 18%), elevated protein (127.2 mg/dL), and glucose 139 mg/dL (serum glucose 168 mg/dL).

Based on this CSF profile, empiric intravenous ceftriaxone was started. About 6 hours after the antibiotic initiation, he was found stuporous, hypotensive to 60/40s, without fever. He developed a diffuse rash involving his abdomen. He received intravenous hydrocortisone 100 mg with rapid improvement of

the rash and hypotension. Jarisch-Herxheimer reaction (JHR) was suspected given the high likelihood of a spirochete infection.

JHR is often underrecognized because it occurs within 2–8 hours after initiating antibiotics, and many of its symptoms (e.g., fever, body aches, rashes, and vital sign changes) are often present before antibiotics initiation.² It is often self-resolving and managed symptomatically. Corticosteroids are sometimes given, although evidence for its efficacy is inconclusive.^{3–5}

Later, the *Treponema pallidum* particle agglutination and rapid plasma reagin (RPR, 1:32) returned positive. CSF venereal disease research laboratory (VDRL) test was also positive at 1:1. His serum Lyme Western blot (WB) showed 1/10 immunoglobulin (Ig) G bands, but the CSF Lyme IgG WB revealed 5/10 IgG bands.

Questions for Consideration:

1. How do you interpret his syphilis and Lyme tests?
2. Would this change your management?

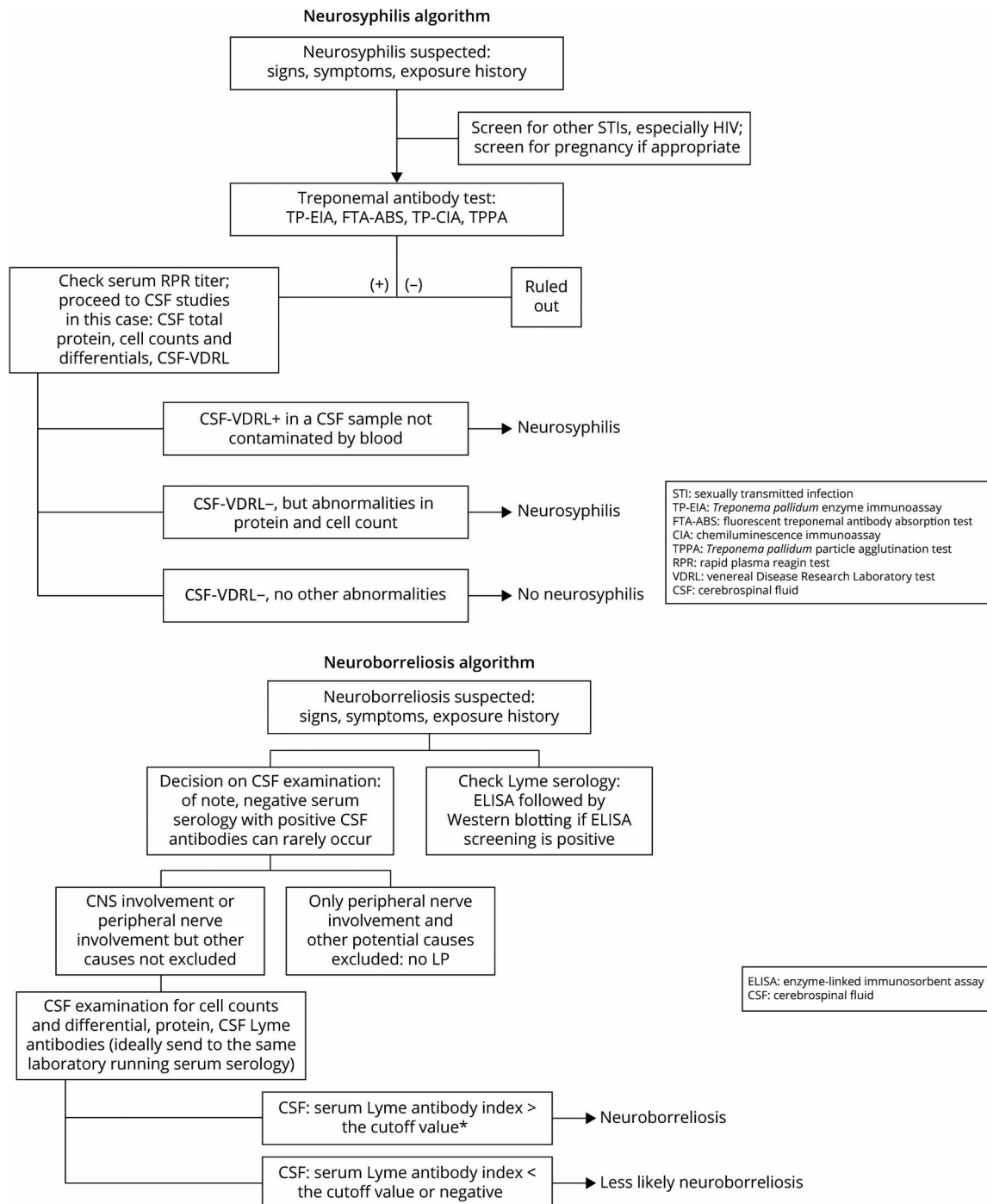
GO TO SECTION 4

Section 4

In this case, syphilis was diagnosed based on history, rash, and positive treponemal/nontreponemal tests. Furthermore, neurosyphilis was diagnosed based on neurologic findings, pleocytosis (minimal blood contamination), elevated protein level, and positive VDRL.⁶ CSF VDRL has a high specificity barring blood contamination⁶ and a positive predictive value of 100% with a positive serum nontreponemal test.⁷

The diagnosis of Lyme disease, however, is not straightforward, and we suggest following a diagnostic algorithm (Figure 2). His initial serum Lyme WB had only 1 positive IgG band (41 kD), with negative IgM. This does not support a definitive diagnosis of Lyme disease, although we cannot rule out early disseminated infection.⁸ His CSF Lyme WB surprisingly revealed 5 positive bands (93, 58, 41, 39, and 23 kDa). A negative serum serology with a positive CSF Ab can rarely occur.⁹ Although antibodies against *Treponema*

Figure 2 Diagnostic Algorithms for Neurosyphilis and Neuroborreliosis.



For neurosyphilis, we suggested reverse algorithm to establish syphilis diagnosis.

pallidum can cross-react with certain *Borrelia burgdorferi* antibodies, it would be highly unlikely to cross-react with 5 *B. burgdorferi*-derived antigens simultaneously.¹⁰ The Infectious Diseases Society of America (IDSA) guideline recommends checking the CSF:serum antibody index to demonstrate that CSF antibody comes directly from intrathecal production rather than from serum.¹¹ Because of logistic reasons, CSF and serum samples in this case were sent to 2 different reference laboratories, and thus, we could not calculate the index. However, 5 positive CSF IgG bands vs 1 serum IgG band still strongly supports high-level intrathecal *B. burgdorferi*-specific IgG synthesis.

The first-line regimen for neurosyphilis is intravenous aqueous crystalline penicillin G per the Centers for Disease Control and Prevention (CDC) recommendation,¹² and this choice is based on clinical experience without evidence generated by randomized clinical trials. Two studies have demonstrated that intravenous ceftriaxone had similar efficacy with penicillin,^{13,14} and thus, the CDC guideline suggests ceftriaxone as an alternative therapy. Intravenous ceftriaxone and oral doxycycline are the mainstay of neuroborreliosis treatment per recent IDSA with intravenous penicillin as an alternative.¹¹ We elected to use intravenous penicillin targeting neurosyphilis and oral doxycycline targeting neuroborreliosis, acknowledging penicillin's potential efficacy against neuroborreliosis.

He completed a concurrent 14-day course of intravenous penicillin and a 28-day course of oral doxycycline, with neurologic improvement. It has been a common practice to repeat serial CSF examinations every 6 months after completion of treatment to determine treatment response because patients may need to be retreated if CSF pleocytosis has not decreased by 6 months or if CSF abnormalities have not normalized by 2 years.⁶ However, there is growing evidence that a ≥ 4 -fold decrease in RPR after treatment strongly predicts CSF normalization.¹⁵ Six months later, his follow-up CSF demonstrated decreased protein (72 mg/dL), resolution of pleocytosis, and negative VDRL, despite serum RPR titer of 1:32. At 1 year, he had a new exposure, and his serum RPR titer returned elevated to 1:256, with pleocytosis and protein elevation in CSF, suggesting syphilis reinfection. He received another course of penicillin with improvements in both RPR and CSF profile.

Study Funding

No targeted funding reported.

Disclosure

The authors report no relevant disclosures. Go to Neurology.org/N for full disclosures.

Publication History

Received by *Neurology* January 9, 2022. Accepted in final form May 19, 2022. Submitted and externally peer reviewed. The handling editor was Whitley Aamodt, MD, MPH.

Appendix Authors

| Name | Location | Contribution |
|--|---|---|
| Joseph YoungHun Yoon, MD, MSc, MAEd | Department of Neurology, Massachusetts General Hospital, and Department of Neurology, Brigham and Women's Hospital, Harvard Medical School, Boston, MA; Department of Neurosurgery, The Mount Sinai Hospital, New York, NY | Drafting/revision of the manuscript for content, including medical writing for content; study concept or design; analysis or interpretation of data |
| Jacqueline Madeleine Solomon, MD | Department of Neurology, Massachusetts General Hospital, and Department of Neurology, Brigham and Women's Hospital, Harvard Medical School, Boston, MA; Division of Neurology, Department of Medicine, Hamilton Health Sciences, McMaster University, Hamilton, Ontario, Canada | Study concept or design; analysis or interpretation of data |
| Yijia Li, MD | Division of Infectious Disease, Department of Medicine, Brigham and Women's Hospital, Harvard Medical School, Boston, MA | Study concept or design; analysis or interpretation of data |
| Sashank Prasad, MD | Department of Neurology, Brigham and Women's Hospital, Harvard Medical School, Boston, MA | Study concept or design; analysis or interpretation of data |

References

- Rubin DL. Acute and chronic polyradiculopathies. *Continuum (Minneapolis)*. 2011; 17(4):831-854. doi:10.1212/01.CON.0000403798.87740.cc.
- Belum GR, Belum VR, Chaitanya Arudra SK, Reddy BS. The Jarisch-Herxheimer reaction: revisited. *Travel Med Infect Dis*. 2013;11(4):231-237. doi:10.1016/j.tmaid.2013.04.001.
- Griffin GE. Cytokines involved in human septic shock—the model of the Jarisch-Herxheimer reaction. *J Antimicrob Chemother*. 1998;41(suppl A):25-29. doi:10.1093/jac/41.suppl_1.25.
- Remick DG, Negussie Y, Fekade D, Griffin G. Pentoxifylline fails to prevent the Jarisch-Herxheimer reaction or associated cytokine release. *J Infect Dis*. 1996;174(3):627-630. doi:10.1093/infdis/174.3.627.
- Corrigan JJ, Kiernat JF. Effect of polymyxin B sulfate on endotoxin activity in a gram-negative septicemia model. *Pediatr Res*. 1979;13(1):48-51. doi:10.1203/00006450-197901000-00011.
- Ropper AH. Neurosyphilis. *N Engl J Med*. 2019;381(14):1358-1363. doi:10.1056/NEJMr1906228.
- Zheng S, Lin RJ, Chan YH, Ngan CCL. Biological false-positive venereal disease research laboratory test in cerebrospinal fluid in the diagnosis of neurosyphilis—a case-control study. *J Eur Acad Dermatol Venereol*. 2018;32(3):474-481. doi:10.1111/jdv.14681.
- Dressler F, Whalen JA, Reinhardt BN, Steere AC. Western blotting in the serodiagnosis of Lyme disease. *J Infect Dis*. 1993;167(2):392-400. doi:10.1093/infdis/167.2.392.
- Ogrinc K, Lusa L, Lotrič-Furlan S, et al. Course and outcome of early European Lyme neuroborreliosis (Bannwarth syndrome): clinical and laboratory findings. *Clin Infect Dis*. 2016;63(3):346-353.
- Raoult D, Hechemy KE, Baranton G. Cross-reaction with *Borrelia burgdorferi* antigen of sera from patients with human immunodeficiency virus infection, syphilis, and leptospirosis. *J Clin Microbiol*. 1989;27(10):2152-2155. doi:10.1128/jcm.27.10.2152-2155.1989.
- Lantos PM, Rumbaugh J, Bockenstedt LK, et al. Clinical practice guidelines by the Infectious Diseases Society of America (IDSA), American Academy of Neurology (AAN), and American College of Rheumatology (ACR): 2020 guidelines for the prevention, diagnosis, and treatment of Lyme disease. *Arthritis Care Res (Hoboken)*. 2021;73(1):1-9. doi:10.1002/acr.24495.
- Neurosyphilis, Ocular Syphilis, and Otitis Syphilis*. Centers for Disease Control and Prevention; 2021. Accessed April 27, 2022. [cdc.gov/std/treatment-guidelines/neurosyphilis.htm](https://www.cdc.gov/std/treatment-guidelines/neurosyphilis.htm).
- Marra CM, Boutin P, McArthur JC, et al. A pilot study evaluating ceftriaxone and penicillin G as treatment agents for neurosyphilis in human immunodeficiency virus-infected individuals. *Clin Infect Dis*. 2000;30(3):540-544. doi:10.1086/313725.
- Bettuzzi T, Jourdes A, Robineau O, et al. Ceftriaxone compared with benzylpenicillin in the treatment of neurosyphilis in France: a retrospective multicentre study. *Lancet Infect Dis*. 2021;21(10):1441-1447. doi:10.1016/S1473-3099(20)30857-4.
- Marra CM, Maxwell CL, Tantaló LC, Sahi SK, Lukehart SA. Normalization of serum rapid plasma reagin titer predicts normalization of cerebrospinal fluid and clinical abnormalities after treatment of neurosyphilis. *Clin Infect Dis*. 2008;47(7):893-899.

Neurology®

Clinical Reasoning: A 68-Year-Old Man With Palmar Rash, Leg Pain, and Inability to Walk

Joseph YoungHun Yoon, Jacqueline Madeleine Solomon, Yijia Li, et al.
Neurology 2022;99:347-353 Published Online before print June 15, 2022
DOI 10.1212/WNL.0000000000200933

This information is current as of June 15, 2022

| | |
|---|--|
| Updated Information & Services | including high resolution figures, can be found at: http://n.neurology.org/content/99/8/347.full |
| References | This article cites 14 articles, 1 of which you can access for free at: http://n.neurology.org/content/99/8/347.full#ref-list-1 |
| Subspecialty Collections | This article, along with others on similar topics, appears in the following collection(s): Peripheral neuropathy http://n.neurology.org/cgi/collection/peripheral_neuropathy Spinal cord infection http://n.neurology.org/cgi/collection/spinal_cord_infection |
| Permissions & Licensing | Information about reproducing this article in parts (figures, tables) or in its entirety can be found online at: http://www.neurology.org/about/about_the_journal#permissions |
| Reprints | Information about ordering reprints can be found online: http://n.neurology.org/subscribers/advertise |

Neurology® is the official journal of the American Academy of Neurology. Published continuously since 1951, it is now a weekly with 48 issues per year. Copyright © 2022 American Academy of Neurology. All rights reserved. Print ISSN: 0028-3878. Online ISSN: 1526-632X.

