

Clinical Reasoning: A 48-Year-Old Woman With 6 Months of Vivid Visual Hallucinations

Jennifer Kizza, BA, Richard J. Lu, MBA, Jonah Zufacht, MD, and Marc Bouffard, MD

Neurology® 2022;99:166-171. doi:10.1212/WNL.0000000000200806

Correspondence

Dr. Zufacht
Jonah.Zufacht@
pennmedicine.UPenn.edu

Abstract

Visual hallucinations are frequently encountered in clinical practice. It is critical for neurologists, particularly those in training, to develop a systematic approach for evaluating patients presenting with such unique and often perplexing symptoms. In this study, we present the case of a 48-year-old woman who developed vivid visual hallucinations after receiving nivolumab for melanoma. We discuss the broad differential diagnosis for visual hallucinations and how history and examination can guide one's evaluation.

Section 1

A 48-year-old woman with melanoma, anxiety, and depression presented to the neurology clinic with a chief complaint of vision loss and hallucinations.

The patient reported 6 months of gradually progressive, symmetric, central vision loss in each eye (OU) accompanied by visual hallucinations. There was no associated headache. The described hallucinations were silent, immobile, and nonthreatening, and entailed several semiologies including cartoon-like teddy bears and spiders, text on blank paper, faces with elaborate hair, wavy lines, and splotches of color. The hallucinations occurred intermittently throughout the day without clear provoking factors.

The ophthalmologic history was notable only for refractive error. The medical history included anxiety, depression, and stage IIIb melanoma locally metastatic to lymph nodes diagnosed 9 months earlier, for which she underwent a local excision and 9 cycles of nivolumab. Current medications included fluoxetine and atomoxetine. Nivolumab had been held approximately 2 months before neurology evaluation because of adrenal insufficiency. Family history was notable for melanoma in both parents. Social history was relevant for no recreational drug use or alcohol consumption.

An examination of afferent visual function revealed best-corrected distance visual acuities of 20/50 in the right eye (OD) and 20/25 in the left eye (OS), dyschromatopsia OD, and concentric constriction of the visual field OU (affecting the central field OD) on automated perimetry (Figure, A and B). The fundoscopic examination revealed bilateral optic disc edema, obscuring most vessels on the disc OD and at the disc margin OS (Figure, C and D). The general neurologic examination was unremarkable.

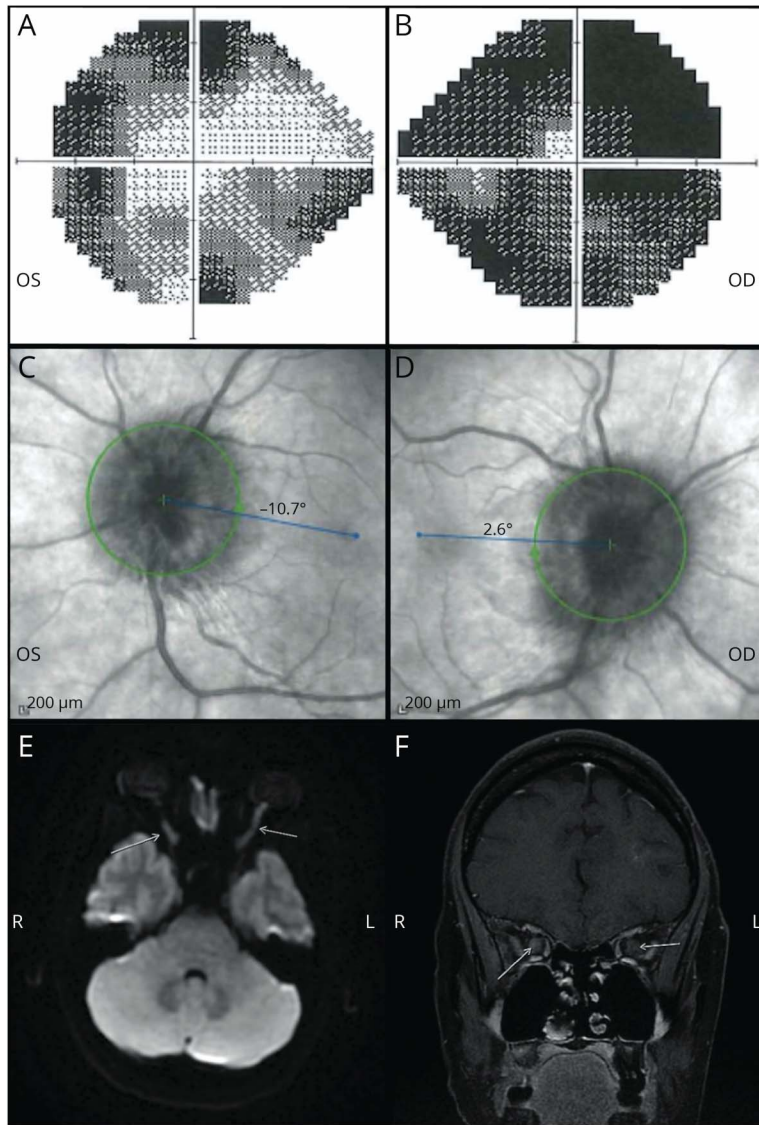
Questions for Consideration:

1. What is the differential diagnosis for visual hallucinations?
2. What are the key features relevant in the characterization of visual hallucinations?

From the Harvard Medical School (J.K., R.J.L.); Hospital of University of Pennsylvania (J.Z.); and Beth Israel Deaconess Medical Center (M.B.).

Go to [Neurology.org/N](https://www.neurology.org/N) for full disclosures. Funding information and disclosures deemed relevant by the authors, if any, are provided at the end of the article.

Figure Automated Perimetry, Fundoscopy, and MRI Findings



Automated perimetry demonstrates primarily concentric vision loss in the left (A) less than right (B) eye with bilateral disc edema (C, D). Axial diffusion-weighted (E) and postcontrast coronal (F) MRI demonstrates mild enlargement of the bilateral, right greater than left, optic nerves with slowed diffusion (arrows, E) and bilateral central enhancement (arrows, F). These findings are consistent with bilateral optic neuritis.

GO TO SECTION 2

Section 2

The broad differential diagnosis for visual hallucinations is summarized in the Table.

In this patient, Charles Bonnet syndrome (CBS) was believed to be the most likely diagnosis, given the silent, non-threatening, mostly formed visual hallucinations in the

presence of afferent vision loss and preserved insight. An evaluation included normal complete blood count, electrolytes, creatinine, liver function tests, serum, and urine toxicology screenings.

Questions for Consideration:

1. What additional diagnostic testing can help clarify the underlying etiology?

Table Differential Diagnosis for Visual Hallucinations

Differential diagnosis	Hallucination types	Associated features	Tailored workup
Charles Bonnet syndrome	Formed or unformed. Typical semiologies include detailed images of people, faces, animals, flowers, trees, plants, and miniature images of people and objects (Lilliputian hallucinations). ³ Typically static and silent. Typically nonthreatening. ⁴	Preserved insight into hallucinations, central or peripheral afferent vision loss (e.g., optic neuritis, macular degeneration) ^{1,2}	Ophthalmologic evaluation, lumbar puncture, MRI orbits, MRI brain
Occipital lobe seizure	Unformed, mobile, silent, usually including small, brightly colored spots or shapes that flash. With visual association cortex involvement, may have more complex hallucinations.	May occur as focal seizure with impairment of consciousness or evolution to bilateral convulsions. Tumors, vascular malformations, and developmental abnormalities are most commonly identified	EEG, MRI seizure protocol
Migraine with visual aura	Unformed, silent, typically fortification spectra, scintillating scotoma, C shapes, or heat waves. Slow evolution in character, size, or position within the visual field, generally lasting 20–60 minutes.	Unilateral headache, may be preceded by prodromal symptoms including yawning, depression, euphoria, irritability, food cravings, neck stiffness, and constipation	Detailed neurologic history and examination
Dementia with lewy bodies	Silent, formed or unformed, may be mobile and potentially threatening	Neurodegenerative disease with cognitive fluctuations, REM sleep behavior disorder, parkinsonism	EEG, MRI brain, dopamine transporter imaging, polysomnography
Advanced idiopathic Parkinson's disease	Silent, formed or unformed, may be mobile and threatening	Neurodegenerative disease with tremor, bradykinesia, rigidity, postural instability	EEG, MRI brain, dopamine transporter imaging
Delirium	Formed or unformed, threatening or nonthreatening, silent or not. May have auditory component.	Acute-onset fluctuating mental status	Serum electrolytes, creatinine, glucose, calcium, complete blood count, liver function tests, and urinalysis
Hallucinogenic substances	Formed or unformed, threatening or nonthreatening. Typically acute-onset after drug exposure.	Heightened perception of sensory input, a distorted sense of time, euphoria, and a sense of well-being. May also present with hallucinogen-persisting perception disorder, a chronic disorder in which patients experience recurrent visual hallucinations or perceptual distortions long after initial drug exposure.	Fingerstick glucose, electrocardiogram, serum and urine toxicology screening (although hallucinogens are typically not assayed)
Psychiatric illnesses	Most typically auditory (schizophrenia, depression with psychotic features may include visual)	Delusions, psychiatric instability	A detailed history
Hypnopompic and hypnagogic hallucinations	Dream-like, complex	Narcolepsy, experienced during transitions between sleep and wakefulness	Polysomnogram, CSF measurement of orexin-A (hypocretin-1)
Peduncular hallucinosis	Vivid, formed, mobile, threatening, silent	Majority of associated structural lesions found in the diencephalon and mesencephalon	MRI
Alcoholic hallucinosis	Vivid, possibly threatening. May be accompanied by tactile (formication) or auditory	Follows decrease in or cessation of alcohol intake in patients with chronic alcohol overuse	Blood alcohol level (12–24 hours before hallucination onset)

GO TO SECTION 3

Section 3

MRI orbit with gadolinium revealed restricted diffusion along the bilateral optic nerves and abnormal contrast enhancement extending from the globe to the optic chiasm (Figure, E and F, respectively). MRI examinations of the brain and cervical spine with contrast were normal. EEG revealed no focal abnormalities, epileptiform changes, or seizures.

Lumbar puncture revealed an opening pressure of 15 cm H₂O and a lymphocytic pleocytosis (53 white blood cells, 94%–98% lymphocytes, 2%–5% monocytes, 0%–1%

polymorphonuclear leukocytes), with 213 red blood cells, 60 mg/dL protein, and 54 mg/dL glucose. No oligoclonal bands were noted, and immunoglobulin G index was within normal limits (0.6 mg/dL). Serum myelin oligodendrocyte glycoprotein (MOG) and aquaporin-4 antibodies were negative, and flow cytometry was unremarkable. Serial lumbar punctures revealed no evidence of malignant cells on cytopathology.

Questions for Consideration:

1. What is the differential diagnosis for optic neuritis?
2. What aspects of this patient's history and physical examination are pertinent in evaluating optic neuritis?

GO TO SECTION 4

Section 4

Typical optic neuritis is clinically characterized by a unilateral optic neuropathy associated with ipsilateral eye pain, which is provoked or worsened by eye movement. The term optic neuritis generally implies an inflammatory, non-infectious mechanism. Optic neuritis may be a manifestation of multiple sclerosis (MS), neuromyelitis optica spectrum disorder (NMOSD), MOG antibody-associated disease, or sarcoidosis. Infectious, neoplastic, vasculitic, toxic, and para-inflammatory (e.g., from immune checkpoint inhibitor [ICI] therapy) etiologies should also be considered. Many cases remain idiopathic with a presumed autoimmune mechanism but no ascertainable disorder to account for its presence. Features including nadir visual acuity, bilaterality, presence of optic disc edema, length of optic nerve enhancement, and clinical course provide clues to the underlying cause of optic neuritis.⁵⁻⁸

This patient's presentation was felt to be atypical due to the bilateral optic nerve involvement, lack of pain, and long-segment optic nerve enhancement on MRI. While bilateral disc edema may also raise concern for elevated intracranial pressure, the color vision loss out of proportion to the degree of edema and lack of headache further supported an optic neuropathy.

Treatment of this patient's melanoma included ICI therapy. She received 9 cycles of nivolumab before presentation. The associated vision loss developed after several cycles. Immune checkpoint inhibitors enhance T-lymphocyte activity by binding antigens, which facilitate T-lymphocyte inhibition. Nivolumab inhibits programmed cell death protein 1, increasing T-cell reactivity against tumor cells. Optic neuritis as an adverse event associated with ICI use may involve direct T-cell-mediated optic neuritis or unmasking of a previously quiescent neuroinflammatory disease with the potential to cause optic neuritis.^{9,10}

This patient's evaluation included negative anti-MOG and anti-AQP4 antibodies, a CSF examination without evidence of oligoclonal bands, and an MRI of the brain and cervical spine without characteristic lesions of MS or NMOSD. There were no malignant cells on serial lumbar punctures to support the diagnosis of leptomeningeal melanomatosis. Features supportive of nivolumab-associated optic neuritis include the slow tempo of progression, painlessness, bilaterality, and longitudinally extensive enhancement of the optic nerves—all of which developed after receiving nivolumab.¹¹

Discussion

Common causes of visual hallucinations include CBS, migraine with aura, occipital lobe seizures, peduncular hallucinosis, neurodegenerative disease, hallucinogen use, alcoholic

hallucinosis, delirium, and psychiatric disease. The formed, stereotyped, silent nature of the hallucinations in the setting of vision loss, preserved insight, and an otherwise-negative evaluation is consistent with CBS. Notably, while this syndrome is typically described in patients with loss of central vision (e.g., from macular degeneration), this case demonstrates that CBS hallucinations can occur in any form of visual loss, whether it is central or peripheral.

The cause of afferent visual dysfunction in this patient was checkpoint inhibitor-associated optic neuritis. Discontinuation of nivolumab and initiation of corticosteroids with plasma exchange led to improvement in this patient's vision and cessation of her visual hallucinations over the next few months. During this time, the visual field abnormalities returned to normal in the left eye and improved substantially in the right eye.

The patient provided informed consent.

Study Funding

M. Bouffard: consultancies: (1) National Vaccine Injury Compensation Program \$18,000; other activities: I will receive approximately \$5,000 from Stoke Therapeutics for serving as the site principal investigator for a prospective natural history study evaluating patients with OPA1 optic neuropathy. This funding is intended to offer salary support for the study patients I will see in lieu of nonstudy patients from whom I would derive clinical income. Research Support, Academic Entities: Beth Israel Deaconess Medical Center, Department of Neurology \$60,000 to fund research in idiopathic intracranial hypertension (none of which is salary support); Legal Proceedings: I have provided expert testimony in a malpractice case for which I was compensated \$3,000.

Disclosure

The authors report no disclosures relevant to the manuscript. Go to Neurology.org/N for full disclosures.

Publication History

Received by *Neurology* October 18, 2021. Accepted in final form April 14, 2022. Submitted and externally peer reviewed. The handling editor was Whitley Aamodt, MD, MPH.

Appendix Authors

Name	Location	Contribution
Jennifer Kizza, BA	Harvard Medical School	Drafting/revision of the article for content, including medical writing for content; major role in the acquisition of data; study concept or design; analysis or interpretation of data; and other
Richard J. Lu, MBA	Harvard Medical School	Drafting/revision of the article for content, including medical writing for content; major role in the acquisition of data; study concept or design; analysis or interpretation of data; and other

Appendix (continued)

Name	Location	Contribution
Jonah Zuflacht, MD	Hospital of University of Pennsylvania	Drafting/revision of the article for content, including medical writing for content; study concept or design; and analysis or interpretation of data
Marc Bouffard, MD	Beth Israel Deaconess Medical Center	Drafting/revision of the article for content, including medical writing for content; study concept or design; and analysis or interpretation of data

References

1. Hamedani AG, Pelak VS. The Charles Bonnet syndrome: a systematic review of diagnostic criteria. *Curr Treat Options Neurol*. 2019;21(9):41.
2. Al-Zubidi N, Lee AG. Charles Bonnet syndrome: overview. In: Schmidt-Erfurth U, Kohlen T, eds. *Encyclopedia of Ophthalmology*. : Springer Berlin Heidelberg; 2016:1-3.
3. Pang L. Hallucinations experienced by visually impaired: Charles Bonnet syndrome. *Optom Vis Sci*. 2016;93(12):1466-1478.
4. Cox TM, ffytche DH. Negative outcome Charles Bonnet syndrome. *Br J Ophthalmol*. 2014;98(9):1236-1239.
5. Chen JJ, Flanagan EP, Bhatti MT, et al. Steroid-sparing maintenance immunotherapy for MOG-IgG associated disorder. *Neurology*. 2020;95(2):e111-e20.
6. Kidd DP, Burton BJ, Graham EM, Plant GT. Optic neuropathy associated with systemic sarcoidosis. *Neurol Neuroimmunol Neuroinflamm*. 2016;3(5):e270.
7. Bennett JL. Optic neuritis. *Continuum (Minneapolis, MN)*. 2019;25(5):1236-1264.
8. Beck RW, Cleary PA, Anderson MM, et al. A randomized, controlled trial of corticosteroids in the treatment of acute optic neuritis. The Optic Neuritis Study Group. *N Engl J Med*. 1992;326(9):581-588.
9. Yu CW, Yau M, Mezey N, Joarder I, Micieli JA. Neuro-ophthalmic complications of immune checkpoint inhibitors: a systematic review. *Eye Brain*. 2020;12:139-167.
10. Oliveira MCB, de Brito MH, Simabukuro MM. Central nervous system demyelination associated with immune checkpoint inhibitors: review of the literature. *Front Neurol*. 2020;11:538695.
11. Francis JH, Jaben K, Santomasso BD, et al. Immune checkpoint inhibitor-associated optic neuritis. *Ophthalmology*. 2020;127(11):1585-1589.

The AAN Has Your Back!

Every day, the AAN is fighting for you. From actively lobbying members of Congress for common sense legislation, to meeting with regulators to demonstrate the value of neurology and reduce regulatory hassles, the Academy is forcefully countering any threats to your profession and patient access to care. Learn more at [AAN.com/policy-and-guidelines](https://aan.com/policy-and-guidelines), read the bimonthly Capitol Hill Report and monthly *AANnews*® member magazine, and respond to Advocacy Action Alert emails when we invite you to share your voice with Congress.

Get into the conversation at #AANAdvocacy.

Visit the *Neurology*® Resident & Fellow Website

Click on Residents & Fellows tab at Neurology.org.

Now offering:

- *Neurology* Resident & Fellow Editorial team information
- “Search by subcategory” option
- E-Pearl of the Week
- Direct links to Career Planning and AAN Resident & Fellow Pages
- Recently published Resident & Fellow articles
- Commentaries by Editors and Resident & Fellow team members

 Find *Neurology* Residents & Fellows Section on Facebook: facebook.com/AANResidentsAndFellows

 Follow *Neurology* on Twitter: [#GreenJournal](https://twitter.com/GreenJournal) [#NeurologyRF](https://twitter.com/NeurologyRF)

 Find *Neurology* Residents & Fellows Section on Instagram: [#aanbrain](https://www.instagram.com/aanbrain) [#NeurologyRF](https://www.instagram.com/NeurologyRF)

Neurology[®]

Clinical Reasoning: A 48-Year-Old Woman With 6 Months of Vivid Visual Hallucinations

Jennifer Kizza, Richard J. Lu, Jonah Zuflacht, et al.

Neurology 2022;99;166-171 Published Online before print May 16, 2022

DOI 10.1212/WNL.0000000000200806

This information is current as of May 16, 2022

Updated Information & Services	including high resolution figures, can be found at: http://n.neurology.org/content/99/4/166.full
References	This article cites 10 articles, 3 of which you can access for free at: http://n.neurology.org/content/99/4/166.full#ref-list-1
Subspecialty Collections	This article, along with others on similar topics, appears in the following collection(s): Clinical neurology history http://n.neurology.org/cgi/collection/clinical_neurology_history Hallucinations http://n.neurology.org/cgi/collection/hallucinations Optic neuritis; see Neuro-ophthalmology/Optic Nerve http://n.neurology.org/cgi/collection/optic_neuritis Visual loss http://n.neurology.org/cgi/collection/visual_loss
Permissions & Licensing	Information about reproducing this article in parts (figures, tables) or in its entirety can be found online at: http://www.neurology.org/about/about_the_journal#permissions
Reprints	Information about ordering reprints can be found online: http://n.neurology.org/subscribers/advertise

Neurology® is the official journal of the American Academy of Neurology. Published continuously since 1951, it is now a weekly with 48 issues per year. Copyright © 2022 American Academy of Neurology. All rights reserved. Print ISSN: 0028-3878. Online ISSN: 1526-632X.

