

Pearls & Oy-sters: Managing Cholesterol in a Patient With Statin Intolerance Due to Anti-HMG-CoA Reductase–Associated Myopathy

Eduardo Villa, Bachelor of Medicine, Rodrigo Naves, PhD, Katuska Bezares, MD, Karen Cobeña, MD, Ana Claudia Villarroel, MD, and Carlos Guevara, PhD

Neurology® 2022;99:909-913. doi:10.1212/WNL.0000000000201315

Correspondence

Dr. Guevara,
neurocrs@hotmail.com

Abstract

Statins are the first line of treatment for hypercholesterolemia and of prevention of atherosclerotic cardiovascular disease (ASCVD). It is estimated that 1 in 4 Americans over the age of 40 years use statins. In rare cases, patients may develop an autoimmune myopathy associated with antibodies against 3-hydroxy-3-methylglutaryl coenzyme A reductase (HMGCR). Anti-HMGCR–associated myopathy requires immediate discontinuation of statins plus initiation of immunosuppressive therapy. Suspension of statin treatment worsens low-density lipoprotein-cholesterol (LDL-C) control, leading to an increased risk of ASCVD and necessitating commencement of another treatment for dyslipidemia. Unfortunately, the management of dyslipidemia in these patients is still unclear. In this study, we describe the case of a 65-year-old woman with dyslipidemia treated with atorvastatin, who consulted for long-standing muscle pain associated with symmetrical proximal weakness. Laboratory tests showed elevated levels of creatine kinase and anti-HMGCR antibodies. She was diagnosed with an anti-HMGCR–associated myopathy and was successfully treated with corticosteroids and azathioprine as immunosuppressive therapy, followed by ezetimibe for LDL-C reduction. We present key findings for early recognition and treatment of anti-HMGCR–associated myopathy and give recommendations on how to manage hypercholesterolemia in a patient with statin intolerance due to this disease.

Pearls

- Anti-HMG-CoA reductase–associated myopathy requires immediate discontinuation of statins, plus immunosuppressive therapy. Discontinuation of statins worsens LDL-C control, leading to an increased risk of atherosclerotic cardiovascular disease, which makes further treatment for dyslipidemia necessary.
- Ezetimibe is a safe, effective, and affordable choice to control LDL-C. Different LDL-C–lowering agents, such as PCSK9 inhibitor, may be used to achieve personalized LDL-C goals.

Oy-sters

- Statin-associated muscle symptoms must be distinguished from anti-HMG-CoA reductase–associated myopathy. Useful keys to consider, other than the presence of anti-HMG-CoA reductase antibodies, are a progressive, symmetrical, proximal weakness and a very high CK.
- A rechallenge with the same or another type of statin has proven to be unsuccessful and should be avoided.
- Although muscle fiber necrosis has been classically described in anti-HMGCR–associated myopathy, it may not be present in a biopsy.

From the Program of Immunology (R.N.), Institute of Biomedical Sciences, Faculty of Medicine (E.V.), Universidad de Chile. Santiago; Department of Pathology (K.B., K.C.), Hospital San Juan de Dios, Universidad de Chile. Santiago; and Department of Neurology and Neurosurgery (A.C.V., C.G.), Faculty of Medicine, Hospital Clínico Universidad de Chile. Santiago.

Go to [Neurology.org/N](https://www.neurology.org/N) for full disclosures. Funding information and disclosures deemed relevant by the authors, if any, are provided at the end of the article.

Glossary

ASCVD = atherosclerotic cardiovascular disease; LDL-C = low-density lipoprotein-cholesterol.

Case Report

A 65-year-old woman with dyslipidemia, which had been treated with atorvastatin 10 mg per day for 48 months, presented with a 10-month history of progressive myalgia in the upper and lower limbs, predominantly proximal, graded 8/10 on the visual analogue scale, and associated with a progressive limitation in the ability to raise her arms above the shoulder level and difficulty getting out of bed. She was thereafter unable to stand up and able to walk only 10 meters. She was a homemaker without other diseases, interventions, or relevant family history of disease.

Physical examination showed a myopathic gait with symmetrical proximal muscle weakness, compromising the strength of the neck (cervical flexion M3 and cervical extension M4) and the 4 extremities (shoulder abduction M3, elbow flexion and extension M4, wrist flexion M4, knee flexion and extension M3, and hip flexion M2), with marked atrophy of both deltoids and quadriceps. Deep tendon reflexes were normal, and there were no sensory deficits.

Suspecting an ongoing myopathy, atorvastatin was stopped. Laboratory tests revealed a total creatine kinase (CK) of 5,839 U/L (normal level [NL]: 30–135), autoantibodies against 3-hydroxy-3-methylglutaryl coenzyme A reductase (HMGCR) > 200 (NL < 20), negative connective tissue disease antibodies, and a negative panel of antibodies for inflammatory myopathies. After

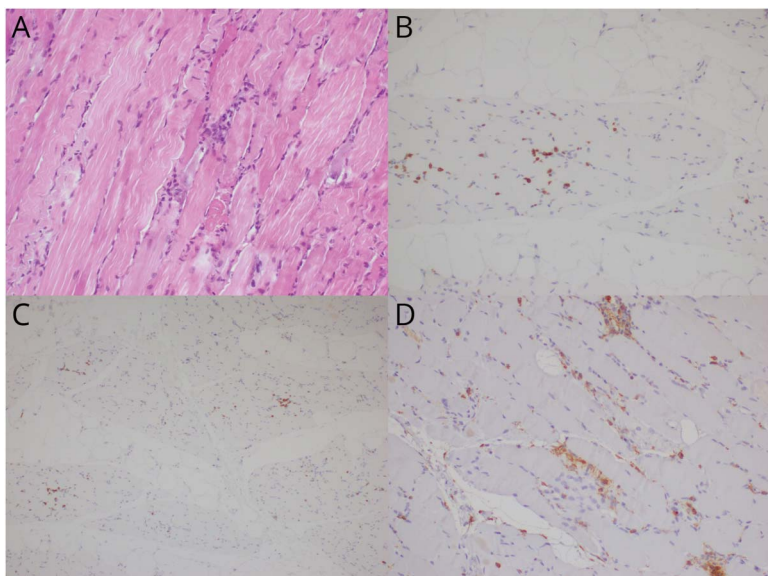
an extended study that included gynecologic, breast, and thyroid ultrasounds and chest CT, malignancy was ruled out (Table 1). Electromyography (EMG) showed signs of proximal active inflammatory myopathy.

Methylprednisolone 500 mg IV daily was given for 3 days, followed by oral prednisone 80 mg daily and azathioprine up to 3 mg/kg of body weight. After a month, the CK level fell to 1,245 U/L. The patient did not experience significant improvement during the first 3 months of treatment; therefore, a left quadriceps biopsy was performed and showed muscle fibers of different sizes without necrosis. Immunohistochemical staining showed that the predominant inflammatory cells were macrophages (cluster of differentiation [CD]163-positive), with B lymphocytes (CD20-positive) and T lymphocytes (CD3-positive) present (Figure 1).

Four months after the treatment onset, sustained clinical improvement was observed, associated with a reduction in CK levels to 303 U/L. Prednisone was tapered-off while maintaining the dose of azathioprine at 150 mg/d. At month 4, the patient was able to walk 500 meters and muscle strength had improved.

Although previously normal, after 7 weeks of atorvastatin discontinuation, total cholesterol and low-density lipoprotein cholesterol (LDL-C) were 289 mg/dL (NL: <200) and 164 mg/dL (NL: <140), and after 20 weeks increased to 329 mg/dL and 196 mg/dL, respectively. Ezetimibe 10 mg per day was used

Figure 1 Quadriceps Biopsy



20× view of histologic sections stained with hematoxylin and eosin (A) showed muscle fibers of different sizes without necrosis, accompanied by moderate chronic lymphohistiocytic inflammation and tissue between muscle fibers. (B–D) Immunohistochemical staining (B) 20× view of B lymphocytes (cluster of differentiation [CD]20-positive) and (C) 10× view of T lymphocytes (CD3-positive). (D) 20× view of macrophages. Macrophages are the predominant inflammatory cells (CD163-positive).

Table 1 Laboratory Tests Results and Normal Values

Laboratory analysis	Before treatment	After discontinuation of statins and starting MTP	Normal value
Anti-CCP, RF	Negative		
ANA	Negative		
Anti-Ro, anti-La, anti-RNP, anti-Jo1, anti-Scl70, anti-Sm	Negative		
Anti-HMG-CoA reductase (U)	>200		<20
Creatine kinase (U/L)	5 839		30–135
Hemoglobin (g/dL)	14,1		12–16
Leucocytes (/μL)	7 000		4,500–11,000
Platelets (/μL)	300,000		150,000–400,000
C-reactive protein (mg/dL)	0.07		<1
LDH (U/L)	681		135–214
GOT (U/L)	131		10–32
GPT (U/L)	273		<34
Total cholesterol (mg/dL)		289	<200
HDL-C (mg/dL)		90	40–60
LDL-C (mg/dL)		164	<140
TG (mg/dL)		172	<150
Myositis panel (U/mL)			<5: negative 5–10: dubious >11: positive
PM-Scl100	6		
Mi-2α	2		
Mi-2β	5		
TIF-1-gamma	2		
MDA5	4		
HPX2	1		
SAE1	3		
Ku	2		
PM-Scl75	1		
Jo-1	1		
SRP	3		
PL-7	3		
PL-12	2		
EJ	2		
OJ	4		

Table 1 Laboratory Tests Results and Normal Values*(continued)*

Laboratory analysis	Before treatment	After discontinuation of statins and starting MTP	Normal value
Ro-52	1		

Abbreviations: ANA = anti-nuclear antibodies; anti-CCP = anti-cyclic citrullinated peptide; MTP = methylprednisolone; RF = rheumatoid factor.

as monotherapy to treat the hypercholesterolemia with a sustained reduction of 40% in LDL-C levels after 4 months of follow-up.

Discussion

Statins act by inhibiting HMG-CoA reductase, which leads to increased expression of the hepatic LDL-C receptor and increased clearance of LDL-C from circulation. The mechanism underlying the development of anti-HMGCR myopathy remains unknown, although statins up-regulate the expression of HMG-CoA reductase suggesting a mechanistic link between statins and the development of autoimmunity.¹ They are the first-line agents for the treatment of hypercholesterolemia and prevention of atherosclerotic cardiovascular disease (ASCVD).² It is estimated that 1 in 4 Americans aged older than 40 years use statins.³ Their most common adverse effects occur in skeletal muscle, usually called statin-associated muscle symptoms (SAMS), and include myalgia (muscle aches without elevated levels of CK), myopathy (muscle symptoms with CK >10 times the upper limit of normal [ULN]), myositis (muscle inflammation), and rhabdomyolysis.

Statins are also associated with anti-HMG-CoA reductase-associated myopathy. This is a rare disease with an estimated incidence of 2–3 cases for every 100,000 patients treated with statins,⁴ which generally occurs in adults in their 50s and 60s who have been taking statins for 1–2 years, but can also occur in patients with no history of statin use. In one case series, the median disease duration was 13 months at the time of biopsy.⁵ Patients usually have very high CK levels: > 10 times the ULN, usually around 45 times the ULN.^{3,4} The clinical presentation consists of myalgia and a bilateral, proximal, symmetric weakness that helps to differentiate it from other forms of SAMS in which weakness is less common. Indicative laboratory test results include the presence of anti-HMGCR antibodies, which have a sensitivity of 94.4% and a specificity of 99.3% for anti-HMG-CoA reductase-associated myopathy.⁶ EMG is usually interpreted as an irritable myopathy, and magnetic resonance imaging may show muscle edema. Muscle biopsy may reveal muscle fibers of different sizes, necrosis, regeneration, myophagocytosis, and infiltration of macrophages and lymphocytes.⁴ Up to 25% of cases may present with neither muscle fiber necrosis nor perimysial pathology.⁷ Macrophages that are CD163-positive are the predominant

infiltrating cell type and would play a role in muscle regeneration rather than mediate muscle injury. Sparse lymphocytic infiltration suggests that T and B cells play a lesser role in the pathogenesis of anti-HMG-CoA reductase-associated myopathy.⁴

In addition to the discontinuation of statins, immunosuppressive treatment is indicated, usually corticosteroids at a dose equivalent to 1 mg/kg/d of prednisone. Methotrexate and azathioprine are often given as immunosuppressant agents.^{3,4} The use of IV immunoglobulin has also been described as a replacement for immunosuppressants or even as monotherapy,⁸ and rituximab has been used as a rescue treatment for patients with refractory anti-HMG-CoA reductase-associated myopathy,⁹ but effective treatment strategies have not yet been established in clinical trials. After muscle strength recovery, medications should be tapered, although a relapse may prompt long-term immunosuppressive therapy.

There are several caveats in the treatment of these patients. Corticosteroid treatment may adversely affect serum lipid levels.¹⁰ This should be considered if a patient treated with corticosteroids and LDL-lowering therapy continues with a high LDL-C level because this may prompt replacement or reduction of the dose of corticosteroids and/or intensification of the LDL-lowering therapy. Second, rechallenge with the same or another type of statin should be avoided because this may lead to a disease flare, with accelerated decline in weakness and worsening hyperCKemia,³ possibly by the upregulation of HMGCR levels. Third, although anti-HMGCR antibody levels are reported to correlate with disease activity, they rarely normalize even in patients who seem to have recovered. Thus, anti-HMGCR antibody titer may not be useful for therapeutic monitoring.

In anti-HMG-CoA reductase-associated myopathy, the aim of pharmacologic lipid modification is to reduce LDL-C as a means of primary or secondary prevention of ASCVD. Ezetimibe reduces LDL-C by selectively blocking the Niemann-Pick C1-like 1 protein and reducing intestinal cholesterol absorption. In addition, ezetimibe inhibits macrophage migration, decreasing vascular cell adhesion molecule 1 expression, and reducing the level of reactive oxygen species, which may reduce inflammation.¹¹ Although it has been shown to reduce LDL-C by 15%–20%, there is limited evidence on its role as monotherapy in the prevention of ASCVD.¹² Ezetimibe has a safety profile similar to placebo, and no significant drug interactions have been observed.¹²

A case series described the use of proprotein convertase subtilisin/kexin type 9 (PCSK9) inhibitors, which proved to be a safe cholesterol-lowering therapy for patients with anti-HMG-CoA reductase-associated myopathy.¹³ PCSK9 inhibitors have been proven to reduce LDL-C more effectively than ezetimibe.¹⁴ Although PCSK9 inhibitors are very effective and safe drugs that can reduce LDL-C and

cardiovascular events, considering their cost, they may be cost-effective only in patients at very high-risk of ASCVD and their use may not be possible in countries with limited healthcare resources.²

A large retrospective cohort study¹⁵ found that patients with myocardial infarction (MI) who were prescribed statin but were found to be statin-intolerant after MI hospitalization and were therefore then treated with another LDL-lowering therapy had a 36% higher rate of recurrence of MI and a 43% higher rate of coronary heart disease events than those who were statin-adherent. Strategies for dealing with statin intolerance in secondary prevention are still needed.

The exponential use of statins makes it crucial for clinicians to remain aware of their possible and even dangerous side effects. Early recognition and treatment are key factors in decreasing the morbidity of anti-HMG-CoA reductase-associated myopathy, a rare disease that requires definitive statin withdrawal, plus immunosuppressive therapy, while maintaining the prevention of ASCVD.

Study Funding

No targeted funding reported.

Disclosures

The authors report no disclosures relevant to the manuscript. Go to [Neurology.org/N](https://www.neurology.org/N) for full disclosures.

Publication History

Received by *Neurology* May 2, 2022. Accepted in final form August 12, 2022. Handling Editor Statement: Submitted and externally peer reviewed. The handling editor was Roy Strowd III, MD, Med, MS.

Appendix Authors

Name	Location	Contributions
Eduardo Villa	Faculty of Medicine, Universidad de Chile, Santiago, Chile	Drafting/revision of the manuscript for content, including medical writing for content; major role in the acquisition of data; study concept or design; analysis or interpretation of data
Rodrigo Naves, PhD	Program of Immunology, Institute of Biomedical Sciences, Santiago, Chile	Drafting/revision of the manuscript for content, including medical writing for content
Katiuska Bezares, MD	Department of Pathology, Hospital San Juan de Dios, Universidad de Chile, Santiago, Chile	Analysis or interpretation of data
Karen Cobaña, MD	Department of Pathology, Hospital San Juan de Dios, Universidad de Chile, Santiago, Chile	Analysis or interpretation of data

Appendix (continued)

Name	Location	Contributions
Ana Claudia Villarroel, MD	Department of Neurology and Neurosurgery, Faculty of Medicine, Hospital Clínico Universidad de Chile, Santiago, Chile	Drafting/revision of the manuscript for content, including medical writing for content; analysis or interpretation of data
Carlos Guevara, PhD	Department of Neurology and Neurosurgery, Faculty of Medicine, Hospital Clínico Universidad de Chile, Santiago, Chile	Drafting/revision of the manuscript for content, including medical writing for content; major role in the acquisition of data; study concept or design; analysis or interpretation of data

References

- Mammen AL, Chung T, Christopher-Stine L, et al. Autoantibodies against 3-hydroxy-3-methylglutaryl-coenzyme A reductase in patients with statin-associated autoimmune myopathy. *Arthritis Rheum*. 2011;63(3):713-721. doi: 10.1002/art.30156
- Mach F, Baigent C, Catapano AL, et al. ESC/EAS Guidelines for the management of dyslipidaemias: lipid modification to reduce cardiovascular risk. *Eur Heart J*. 2019;40(1):1-11. doi: 10.1093/eurheartj/ehz455
- Nazir S, Lohani S, Tachamo N, Poudel D, Donato A. Statin-associated autoimmune myopathy. *J Clin Rheumatol*. 2017;23(3):149-154. doi: 10.1097/RHU.0000000000000497
- Mammen AL. Statin-associated autoimmune myopathy. *N Engl J Med*. 2016;374(7):664-669. doi: 10.1056/NEJMr1515161
- Allenbach Y, Benveniste O, Stenzel W, Boyer O. Immune-mediated necrotizing myopathy: clinical features and pathogenesis. *Nat Rev Rheumatol*. 2020;16(12). doi: 10.1038/s41584-020-00515-9
- Mammen AL, Pak K, Williams EK, et al. Rarity of anti-3-hydroxy-3-methylglutaryl-coenzyme A reductase antibodies in statin users, including those with self-limited musculoskeletal side effects. *Arthritis Care Res (Hoboken)*. 2012;64(2):269-272. doi: 10.1002/acr.20662
- Alshehri A, Choksi R, Bucelli R, Pestronk A. Myopathy with anti-HMGCR antibodies. *Neurol Neuroimmunol Neuroinflamm*. 2015;2(4):e124. doi: 10.1212/NXI.0000000000000124
- Weeding E, Tiniakou E. Therapeutic management of immune-mediated necrotizing myositis. *Curr Treatm Opt Rheumatol*. 2021;7(2):150-160. doi: 10.1007/s40674-021-00174-1
- Landon-Cardinal O, Allenbach Y, Soulages A, et al. Rituximab in the treatment of refractory anti-HMGCR immune-mediated necrotizing myopathy. *J Rheumatol*. 2019;46(6):623-627. doi: 10.3899/jrheum.171495
- Herink M, Ito MK. Medication induced changes in lipid and lipoproteins. *Endotext*. Published online May 10, 2018. Accessed June 27, 2022. ncbi.nlm.nih.gov/books/NBK326739/.
- Niedzielski M, Broncel M, Gorzelak-Pabiś P, Woźniak E. New possible pharmacological targets for statins and ezetimibe. *Biomed Pharmacother*. 2020;129:110388. doi: 10.1016/j.biopha.2020.110388
- Zhan S, Tang M, Liu F, Xia P, Shu M, Wu X. Ezetimibe for the prevention of cardiovascular disease and all-cause mortality events. *Cochrane Database Syst Rev*. 2018;2018(11). doi: 10.1002/14651858.CD012502.pub2
- Tiniakou E, Rivera E, Mammen AL, Christopher-Stine L. Use of proprotein convertase subtilisin/kexin type 9 inhibitors in statin-associated immune-mediated necrotizing myopathy: a case series. *Arthritis Rheum*. 2019;71(10):1723-1726. doi: 10.1002/art.40919
- Moriarty PM, Thompson PD, Cannon CP, et al. Efficacy and safety of alirocumab vs ezetimibe in statin-intolerant patients, with a statin rechallenge arm: the ODYSSEY ALTERNATIVE randomized trial. *J Clin Lipidol*. 2015;9(6):758-769. doi: 10.1016/j.jacl.2015.08.006
- Serban MC, Colantonio LD, Manthripragada AD, et al. Statin intolerance and risk of coronary heart events and all-cause mortality following myocardial infarction. *J Am Coll Cardiol*. 2017;69(11). doi: 10.1016/j.jacc.2016.12.036



**Inclusion, Diversity, Equity,
Anti-racism, & Social Justice (IDEAS)**

An online section highlighting content related to IDEAS topics

[NPub.org/IDEAS](https://pubmed.ncbi.nlm.nih.gov/IDEAS)

Neurology®

Neurology®

Pearls & Oy-sters: Managing Cholesterol in a Patient With Statin Intolerance Due to Anti-HMG-CoA Reductase–Associated Myopathy

Eduardo Villa, Rodrigo Naves, Katiuska Bezares, et al.

Neurology 2022;99:909-913 Published Online before print September 13, 2022

DOI 10.1212/WNL.0000000000201315

This information is current as of September 13, 2022

Updated Information & Services	including high resolution figures, can be found at: http://n.neurology.org/content/99/20/909.full
References	This article cites 14 articles, 2 of which you can access for free at: http://n.neurology.org/content/99/20/909.full#ref-list-1
Subspecialty Collections	This article, along with others on similar topics, appears in the following collection(s): Autoimmune diseases http://n.neurology.org/cgi/collection/autoimmune_diseases Muscle disease http://n.neurology.org/cgi/collection/muscle_disease
Permissions & Licensing	Information about reproducing this article in parts (figures, tables) or in its entirety can be found online at: http://www.neurology.org/about/about_the_journal#permissions
Reprints	Information about ordering reprints can be found online: http://n.neurology.org/subscribers/advertise

Neurology® is the official journal of the American Academy of Neurology. Published continuously since 1951, it is now a weekly with 48 issues per year. Copyright © 2022 American Academy of Neurology. All rights reserved. Print ISSN: 0028-3878. Online ISSN: 1526-632X.

