

Pearls & Oy-sters: Genetic Epilepsy

An Important Cause of Neonatal Seizures in Infants With Complex Congenital Heart Disease

Vanna Kazazian, MN, Thiviya Selvanathan, MD, Vann Chau, MD, Emily W.Y. Tam, MDCM, MAS, and Steven P. Miller, MDCM, MAS

Neurology® 2022;99:811-814. doi:10.1212/WNL.0000000000201229

Correspondence

Dr. Miller
steven.miller@cw.bc.ca

Abstract

Genetic epilepsies, such as *KCNQ2* gene variants, although uncommon, are potential causes of neonatal seizures in infants with complex congenital heart disease (CHD). *KCNQ2*-related seizures commonly present as tonic posturing with autonomic changes and a distinctive amplitude-integrated EEG (aEEG) pattern with increase in amplitude, immediately followed by background suppression. Seizures are typically refractory to commonly used antiepileptics in this age group and respond best to sodium channel blockers such as carbamazepine and fosphenytoin. We report the cases of 2 neonates with complex CHD who presented with seizures secondary to *KCNQ2* gene variation and discuss how early recognition of clinical and EEG features led to early treatment and improved seizure burden. When investigating the etiology of neonatal seizures in the perioperative complex cardiac infant, genetic etiologies such as *KCNQ2* variants should be considered, particularly in the absence of clinical examination and neuroimaging features consistent with brain injury. These 2 cases highlight the importance of a precision medicine approach using clinical examination and seizure semiology, bedside aEEG monitoring, genetic testing, and targeted treatments to improve patient care and outcomes.

Pearls

- Neonatal seizures due to genetic etiologies, such as *KCNQ2*-related epilepsy, have a typical semiology of tonic posturing and autonomic changes, unlike acute symptomatic seizures secondary to brain injury, which typically have clonic movements.
- Neonatal seizures in genetic epilepsies, such as *KCNQ2*, *SCN2A*, and *KCNQ3*-related epilepsies, have distinct electrographic features on bedside amplitude-integrated EEG (aEEG) monitoring.
- Targeted antiseizure therapy should be considered in genetic neonatal epilepsies, such as sodium channel blockers (e.g., carbamazepine) in *KCNQ2*-related epilepsy.

Oy-sters

- Genetic epilepsies, including *KCNQ2*-related epilepsy, are readily diagnosed by gene sequencing and should not be overlooked as a potential cause of seizures in infants with complex CHD, particularly in the absence of clinical examination and neuroimaging evidence of brain injury.
- In combination, the neurologic examination, seizure semiology, and aEEG provide important clues for suspecting genetic etiologies and facilitating early initiation of targeted treatment with antiseizure medications, even before genetic testing results are available.

From the Divisions of Cardiology (V.K.) and Neurology (T.S., V.C., E.W.Y.T., S.P.M.), Department of Pediatrics, The Hospital for Sick Children and University of Toronto, Ontario; and Division of Neurology (S.P.M.), Department of Pediatrics, BC Children's Hospital and Research Institute, University of British Columbia, Vancouver, Canada.

Go to [Neurology.org/N](https://www.neurology.org/N) for full disclosures. Funding information and disclosures deemed relevant by the authors, if any, are provided at the end of the article.

Case Report

Case 1

A 4-day-old male infant born at 39 + 2 weeks gestation with antenatally diagnosed unbalanced atrioventricular septal defect (AVSD) presented with 4 acute paroxysmal episodes of tonic posturing of the arms bilaterally associated with apnea and desaturations. Each episode lasted 30 seconds and occurred over 12 hours. Neurologic examination revealed mild encephalopathy with decreased responsiveness to handling and inability to orally feed. The brain MRI was normal. Continuous EEG (cEEG) over 24 hours captured a single electroclinical seizure, and the interictal background was excessively discontinuous for gestational age. He continued to have frequent refractory clinical seizures despite treatment with loading doses of phenobarbital, levetiracetam, and fosphenytoin, and initiation and optimization of maintenance therapy with phenobarbital, levetiracetam, and pyridoxine. Seizures continued on an almost weekly basis until he was 3 months of age, at which time trio whole-exome sequencing using PGxome assay by Prevention Genetics revealed a heterozygous de novo pathogenic variant in *KCNQ2* c.794C>T, p.Ala265Val. He was switched to carbamazepine and subsequently had good seizure control. At 2 years of age, he was weaned off carbamazepine after a 2-year period of seizure freedom and normal EEG. Since then, he has remained seizure-free and apart from a mild expressive language delay, his development has been age appropriate.

Case 2

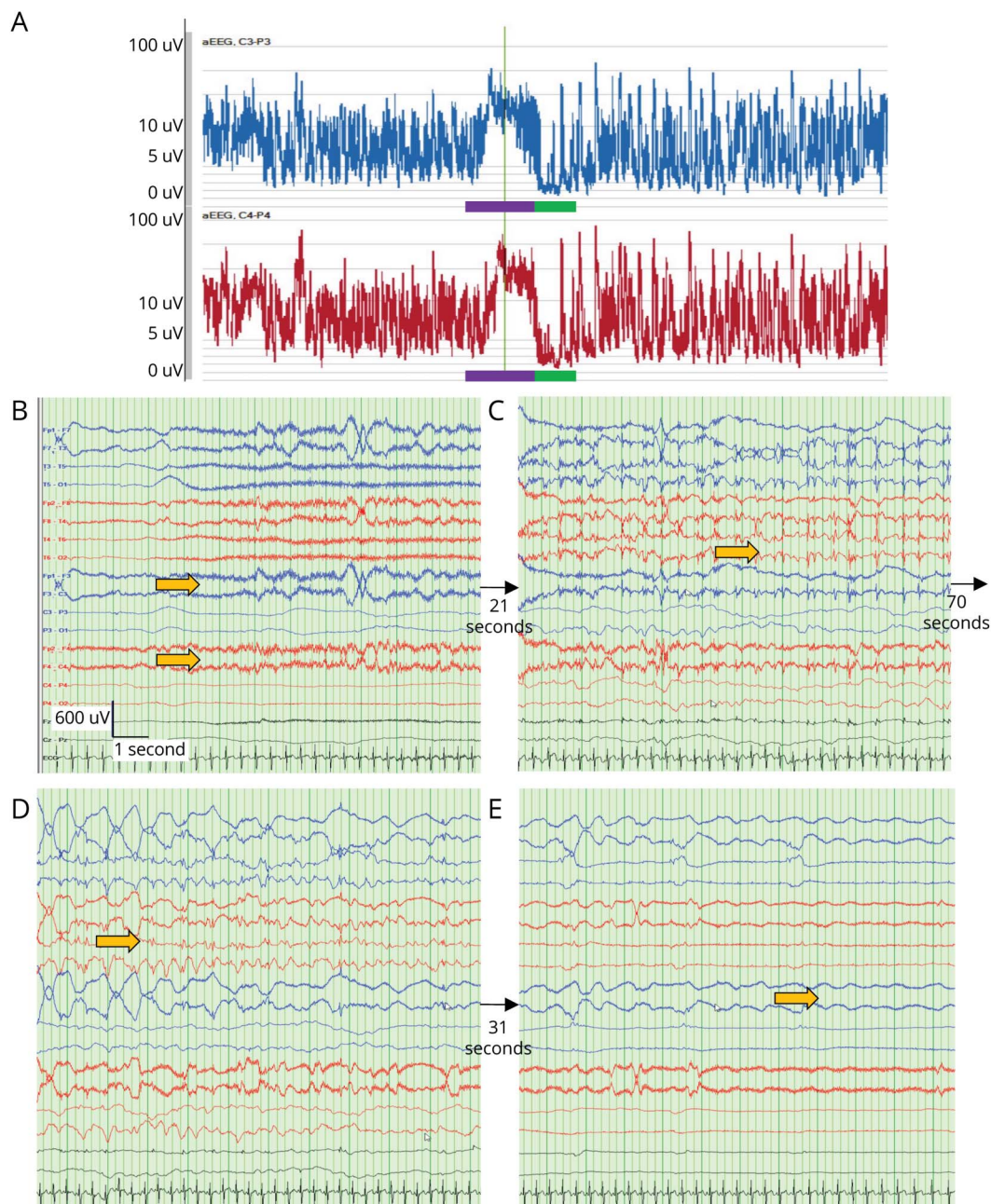
A 6-week-old female infant born at 33 + 2 weeks gestation (postmenstrual age of 39 + 4 weeks) with antenatally diagnosed double outlet right ventricle with pulmonary atresia, balanced AVSD, left-sided unobstructed total anomalous pulmonary venous connection, and right atrial isomerism presented with 5 paroxysmal episodes of tonic posturing, followed by apnea, bradycardia, and desaturations, 3 days after patent ductus arteriosus stenting. Each episode lasted approximately 30 seconds and occurred over an 8-hour period. Neurologic examination was normal for gestational age. The brain MRI was normal. Bedside aEEG recorded over 12 hours captured 4 seizures with a distinctive pattern concerning for *KCNQ2*-related epilepsy consisting of high-amplitude fast rhythmic activity on the raw EEG trace, followed by a period of background suppression. This was confirmed with cEEG capturing 2 additional seizures with prolonged background discontinuity for gestational age over a period of 12 hours (Figure). As a result of rapid identification of the distinctive seizure pattern on aEEG, this infant was immediately started on carbamazepine and had resolution of her seizures. She underwent next-generation trio whole-genome sequencing by The Rady Children's Institute for Genomic Medicine, which revealed a likely pathogenic heterozygous de novo variant in *KCNQ2* c.920T>C p.Leu307Pro. Her development up until 2 months of age was appropriate for gestational age. Unfortunately, she died at 4 months of age secondary to complications of her complex CHD and limited cardiovascular surgical options.

Discussion

Neonates with complex CHD have a seizure incidence of 11.5%, most commonly presenting as acute symptomatic seizures secondary to brain injury including ischemic stroke, hypoxia ischemia, and intraparenchymal hemorrhage.^{1,2} Neonatal-onset epilepsies are an uncommon etiology of neonatal seizures representing approximately 13% of all neonatal seizures, many of which have a genetic etiology.³ Pathogenic or likely pathogenic variants in the *KCNQ2* gene are responsible for more than one-third of genetic neonatal onset epilepsies.³ When investigating the etiology of neonatal seizures in the perioperative complex cardiac infant, genetic epilepsies such as *KCNQ2* variants should be considered, particularly in the absence of clinical and neuroimaging features consistent with brain injury. Genetic testing using epilepsy gene panels and next-generation sequencing, such as whole-exome and genome sequencing, are among the recommended tools in diagnosing genetic epilepsies.³

KCNQ2-related epilepsy causes neonatal seizures secondary to impaired function of potassium channels.^{4,5} Seizures typically present in the first few days of life and can present as 2 phenotypes: self-limited familial neonatal epilepsy (SLFNE) or developmental and epileptic encephalopathy (DEE).^{4,6} Infants with SLFNE usually have positive long-term neurodevelopmental outcomes, and seizures respond well to treatment with sodium channel blockers.^{4,5} Infants with the DEE phenotype can often present with pharmacoresistant seizures and unfavorable neurodevelopmental outcomes.^{4,5,7} The brain MRI is typically normal or can show diffuse cerebral atrophy, and neonatal neurologic examination features include axial hypotonia and encephalopathy.^{5,7} Seizures secondary to *KCNQ2*-related epilepsy most commonly present as tonic posturing with autonomic changes, typically heart rate and respiration changes, with multifocal epileptiform abnormalities and suppression burst pattern on EEG.^{5,7} Recently, seizure semiology and EEG patterns typical for *KCNQ2* gene variants were reported in *SCN2A* and *KCNQ3*-related epilepsies, showing that these may be features more consistent with genetic epilepsies as a whole, rather than *KCNQ2* variants specifically.⁸ By contrast, acute symptomatic seizures secondary to brain injury more commonly present with clonic movements.⁶ Various studies have shown that seizures secondary to *KCNQ2* gene variants respond best to carbamazepine and fosphenytoin, resulting in complete resolution of seizures in 65%–92.5% of infants.^{4,7}

Both infants described in this report had either pathogenic or likely pathogenic *KCNQ2* gene variants and complex CHD; there is currently no known association between *KCNQ2* variants and non-neurologic defects such as CHD.^{4–7} Both infants in this case report likely represent a clinical presentation of SLFNE based on the available data; (1) neither infant presented with severe encephalopathy as would be expected with DEE; (2) both achieved complete cessation of



(A) Ictal aEEG pattern consists of an initial increase in amplitude, followed by background suppression. Purple bar corresponds to seizure duration 1 minute: 33 seconds with increase in aEEG amplitude. Green bar corresponds to postictal background suppression for a total duration of 1 minute. (B–E) Evolution of cEEG pattern during the seizure starting with (B) fast activity beginning in the frontal head regions evolving into (C, D) generalized spike/polyspike-and-wave discharges, and (E) ending with diffuse background attenuation as shown with yellow arrows. Time base 30 mm/s, sensitivity 30 μ V/mm, anterior-posterior bipolar montage. aEEG = amplitude-integrated EEG; cEEG = continuous EEG.

seizures with initiation of carbamazepine; (3) case 1 achieved normal EEG background on repeat recording; (4) and both had overall favourable developmental outcomes, although long-term data are not available for the infant in case 2. It is particularly challenging to determine the etiology of developmental delays in infants with *KCNQ2* gene variants and complex CHD. Children with complex CHD have increased incidence of mild-to-moderate developmental delays, even in the absence of known brain injury or genetic syndromes.⁹

Hence, it is unclear whether the mild language delays present in the child in case 1 are secondary to his *KCNQ2* gene variant or his complex CHD.

aEEG is a tool used in many neonatal intensive care units and is starting to gain popularity in cardiac intensive care units. Using 2 channels of EEG, bedside providers are able to screen for seizure activity and abnormal background brain activity in critically ill neonates. There is a specific ictal aEEG pattern in

KCNQ2-related epilepsy consisting of increased amplitude immediately followed by suppression.^{8,10} More recently, this ictal aEEG pattern has also been found in *SCN2A* and *KCNQ3*-related epilepsies.⁸ Using aEEG as a bedside tool for identifying abnormal brain activity and knowledge of the distinctive ictal pattern associated with *KCNQ2*-related epilepsy has been helpful in the early identification of seizures secondary to *KCNQ2* gene variants, allowing for early initiation of optimal treatment with sodium channel blockers.^{7,10}

aEEG can be a helpful bedside tool in the early recognition of seizures secondary to neonatal genetic epilepsies in infants with CHD. As outlined in case 2, this patient benefitted from early application of aEEG, which not only helped determine that the paroxysmal episodes were seizures but also helped recognition of the aEEG pattern as consistent with *KCNQ2*-related epilepsy. This resulted in immediate initiation of carbamazepine and cessation of seizures. By contrast, the infant in case 1 was not connected to aEEG and the pattern was not clear on cEEG, resulting in poor control of seizures until genetic diagnosis of *KCNQ2* gene variation was confirmed at 3 months of age and he was switched to carbamazepine therapy.

Neonatal genetic epilepsies are an important cause of seizures in infants with complex CHD, which has not been widely explored in the literature. This case report links 2 areas of research; neonatal genetic epilepsies and neurologic comorbidities in CHD to enhance awareness of genetic epilepsies in patients with complex CHD. Clinical and aEEG features of genetic epilepsies in CHD are important to recognize because targeted seizure therapies, such as sodium channel blockers in infants with *KCNQ2*-related epilepsy, are recommended for optimal seizure management and can be initiated before genetic testing results are available. The comparison of these 2 cases brings attention to the need for precision medicine approaches in the care of the complex cardiac infant with seizures through the use of bedside aEEG monitoring, genetic testing, and targeted treatments to improve patient care and outcomes.

Study Funding

No targeted funding reported.

Disclosure

The authors report no relevant disclosures. Go to Neurology.org/N for full disclosures.

Publication History

Received by *Neurology* March 16, 2022. Accepted in final form July 27, 2022. Submitted and externally peer reviewed. The handling editor was Roy Strowd III, MD, MEd, MS.

Appendix Authors

Name	Location	Contribution
Vanna Kazazian, MN	Division of Cardiology, Department of Pediatrics, The Hospital for Sick Children and University of Toronto, Toronto, Ontario, Canada	Drafting/revision of the article for content, including medical writing for content; major role in the acquisition of data; study concept or design; and analysis or interpretation of data
Thiviya Selvanathan, MD	Division of Neurology, Department of Pediatrics, The Hospital for Sick Children and University of Toronto, Toronto, Ontario, Canada	Drafting/revision of the article for content, including medical writing for content; major role in the acquisition of data; and study concept or design
Vann Chau, MD	Division of Neurology, Department of Pediatrics, The Hospital for Sick Children and University of Toronto, Toronto, Ontario, Canada	Drafting/revision of the article for content, including medical writing for content; analysis or interpretation of data
Emily W.Y. Tam, MDCM, MAS	Division of Neurology, Department of Pediatrics, The Hospital for Sick Children and University of Toronto, Toronto, Ontario, Canada	Drafting/revision of the article for content, including medical writing for content; analysis or interpretation of data
Steven P. Miller, MDCM, MAS	Division of Neurology, Department of Pediatrics, The Hospital for Sick Children and University of Toronto, Toronto, Ontario; Division of Neurology, Department of Pediatrics, BC Children's Hospital and Research Institute, University of British Columbia, Vancouver, Canada	Drafting/revision of the article for content, including medical writing for content; analysis or interpretation of data

References

- Clancy RR, Sharif U, Ichord R, et al. Electrographic neonatal seizures after infant heart surgery. *Epilepsia*. 2005;46(1):84-90.
- Ghosh S, Philip J, Patel N, et al. Risk factors for seizures and epilepsy in children with congenital heart disease. *J Child Neurol*. 2020;35(7):442-447.
- Shellhaas RA, Wusthoff CJ, Tsuchida TN, et al. Profile of neonatal epilepsies: characteristics of a prospective US cohort. *Neurology*. 2017;89(9):893-899.
- Kuersten M, Tacke M, Gerstl I, Hoelz H, Stulpnagel Cv, Borggraefe I. Antiepileptic therapy approaches in *KCNQ2* related epilepsy: a systemic review. *Eur J Med Genet*. 2019;63(1):103628.
- Kim HJ, Yang D, Kim SH, et al. Clinical characteristics of *KCNQ2* encephalopathy. *Brain Dev*. 2021;43(2):244-250.
- Scheffer IE, Berkovic S, Capovilla G, et al. ILAE classification of the epilepsies: position paper of the ILAE commission for classification and terminology. *Epilepsia*. 2017;58(4):512-521.
- Pisano T, Numis AL, Heavin SB, et al. Early and effective treatment of *KCNQ2* encephalopathy. *Epilepsia*. 2015;56(5):685-691.
- Pijpers J, Ping YB, Weeke L, et al. Early recognition of unique amplitude-integrated EEG patterns and clinical semiology of neonatal seizures caused by *SCN2A*, *KCNQ2* and *KCNQ3* mutations [abstract]. In: Proceedings of the 13th International Newborn Brain Conference: Neonatal Neurocritical Care, Seizures, and Continuous EEG monitoring. February 10-12, 2022; virtual conference.
- Marino BS, Lipkin PH, Newburger JW, et al. Neurodevelopmental outcomes in children with congenital heart disease: evaluation and management. *Circulation*. 2012;126(9):1143-1172.
- Vilan A, Ribeiro JM, Striano P, et al. A distinctive ictal amplitude-integrated electroencephalography in newborns with neonatal epilepsy associated with *KCNQ2* mutations. *Neonatology*. 2017;112(4):387-393.

Neurology[®]

Pearls & Oy-sters: Genetic Epilepsy: An Important Cause of Neonatal Seizures in Infants With Complex Congenital Heart Disease

Vanna Kazazian, Thiviya Selvanathan, Vann Chau, et al.

Neurology 2022;99;811-814 Published Online before print August 30, 2022

DOI 10.1212/WNL.0000000000201229

This information is current as of August 30, 2022

Updated Information & Services	including high resolution figures, can be found at: http://n.neurology.org/content/99/18/811.full
References	This article cites 9 articles, 2 of which you can access for free at: http://n.neurology.org/content/99/18/811.full#ref-list-1
Subspecialty Collections	This article, along with others on similar topics, appears in the following collection(s): Cardiac http://n.neurology.org/cgi/collection/cardiac EEG http://n.neurology.org/cgi/collection/eeg_ Ion channel gene defects http://n.neurology.org/cgi/collection/ion_channel_gene_defects Neonatal http://n.neurology.org/cgi/collection/neonatal Neonatal seizures http://n.neurology.org/cgi/collection/neonatal_seizures
Permissions & Licensing	Information about reproducing this article in parts (figures, tables) or in its entirety can be found online at: http://www.neurology.org/about/about_the_journal#permissions
Reprints	Information about ordering reprints can be found online: http://n.neurology.org/subscribers/advertise

Neurology® is the official journal of the American Academy of Neurology. Published continuously since 1951, it is now a weekly with 48 issues per year. Copyright © 2022 American Academy of Neurology. All rights reserved. Print ISSN: 0028-3878. Online ISSN: 1526-632X.

