

José G. Merino, MD, MPhil, Editor-in-Chief, Neurology®

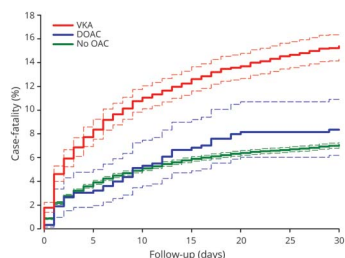


## Notable in *Neurology* this week

This issue features an article that investigates the association of the amount of weight lost after bariatric surgery with intracranial pressure in women with idiopathic intracranial hypertension; another determines the relationship between accelerometer-derived physical activity measurements and brain structure. A special Viewpoint article heralds the coming of a new brain age—an era in which neurologists are positioned to lead brain knowledge integration and application by becoming advocates, healers, and guardians of brain health.

## Articles

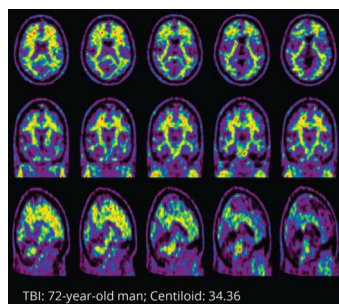
### Impact of Oral Anticoagulation and Adenosine Diphosphate Inhibitor Therapies on Short-term Outcome of Traumatic Brain Injury



Given that the usage of oral anticoagulants (OACs) or adenosine diphosphate inhibitors (ADPi) increases the risk of bleeding, this study investigated the effect of OAC and ADPi therapies on short-term outcomes after traumatic brain injury (TBI). Mortality was found to be slightly increased in patients with TBI using vitamin K antagonists but not in those using direct OACs or ADPi.

Page 460

### $\beta$ -Amyloid and Tau Imaging in Chronic Traumatic Brain Injury: A Cross-sectional Study



Traumatic brain injury (TBI) has long been considered a risk factor for Alzheimer disease. This study assessed  $\beta$ -amyloid and tau burden in long-term survivors of TBI and healthy controls using PET imaging, ultimately finding that single moderate-to-severe TBI was not associated with higher burden of  $\beta$ -amyloid or tau pathologies in the chronic period relative to healthy controls.

Page 461

### Differences in Motor Features of *C9orf72*, *MAPT*, or *GRN* Variant Carriers With Familial Frontotemporal Lobar Degeneration

This study demonstrated gene-related phenotypic differences between individuals with familial frontotemporal lobar degeneration. Vertical gaze palsy was more frequent with *MAPT* variants; apraxia and focal dystonia with *GRN*; and fasciculations, atrophy, and weakness with *C9orf72*. Understanding these complex genotype-phenotype relationships may enhance clinical trial design and inform future treatment decisions.

Page 463

*Continued*

## Short- and Long-term Central Action of Botulinum Neurotoxin Treatment in Laryngeal Dystonia

This study examines the therapeutic effects of botulinum neurotoxin (BoNT) treatment on brain function in patients with laryngeal dystonia (LD). The left precuneus was found to be the site of short-term BoNT central action, while the prefrontal-cerebellar axis was engaged with an intermediate treatment duration of 6–12 years, pointing to indirect action of BoNT treatment on the dystonic sensorimotor network.

Page 465

NB: “Unilateral Upper Cervical Posterior Spinal Cord Infarction Caused by Spontaneous Bilateral Vertebral Artery Dissection,” p. 473. To check out other NeuroImages, point your browser to [Neurology.org/N](https://www.neurology.org/N). At the end of the issue, check out a Resident & Fellow Teaching NeuroImage discussing paravermal lesions in neuronal intranuclear inclusion disease, and another on reversible parkinsonism caused by lumboperitoneal shunt overdrainage. This week also includes a Resident & Fellow Pearls & Oysters article titled “Spinal Cord Candidiasis Linked to CARD9 Deficiency Masquerading as a Longitudinally Extensive Transverse Myelitis.”

### NEW EPISODE

Neurology®  
PODCAST



The *Neurology*® Podcast provides practical, relevant, and timely information for neurologists and all clinicians to practice the best possible neurologic-based medicine for our patients. Each episode features interviews with authors of recent articles from the *Neurology* journals and beyond.

[NPub.org/podcast](https://www.npub.org/podcast)

# Neurology®

## Spotlight on the September 13 Issue

José G. Merino

*Neurology* 2022;99;449-450

DOI 10.1212/WNL.0000000000201053

### This information is current as of September 12, 2022

<b>Updated Information &amp; Services</b>	including high resolution figures, can be found at: <a href="http://n.neurology.org/content/99/11/449.full">http://n.neurology.org/content/99/11/449.full</a>
<b>Subspecialty Collections</b>	This article, along with others on similar topics, appears in the following collection(s): <b>Autonomic diseases</b> <a href="http://n.neurology.org/cgi/collection/autonomic_diseases">http://n.neurology.org/cgi/collection/autonomic_diseases</a>
<b>Permissions &amp; Licensing</b>	Information about reproducing this article in parts (figures, tables) or in its entirety can be found online at: <a href="http://www.neurology.org/about/about_the_journal#permissions">http://www.neurology.org/about/about_the_journal#permissions</a>
<b>Reprints</b>	Information about ordering reprints can be found online: <a href="http://n.neurology.org/subscribers/advertise">http://n.neurology.org/subscribers/advertise</a>

*Neurology*® is the official journal of the American Academy of Neurology. Published continuously since 1951, it is now a weekly with 48 issues per year. Copyright © 2022 American Academy of Neurology. All rights reserved. Print ISSN: 0028-3878. Online ISSN: 1526-632X.

