

Pearls & Oy-sters: Two Cases of Stereotactic EEG-Proven Insular Epilepsy With Nonlocalizing Scalp EEG and Interesting Semiologies

Denise Li, MD, Irina Podkorytova, MD, Marisara Dieppa, MD, and Ghazala Perven, MD

Neurology® 2022;99:437-441. doi:10.1212/WNL.0000000000200993

Correspondence

Dr. Li

denise.jael@gmail.com

Abstract

Insular epilepsy is a great mimicker and can be mistaken for seizures originating from other areas of the brain or as nonepileptic spells. The semiology of insular epilepsy can include, but is not limited to, auditory illusions, paresthesias, gastric rising, laryngeal constriction, and hyperkinetic movements. These arise from both the functions of the insula itself and its extensive connections with other regions of the brain. Noninvasive workup can be negative or nonlocalizing because of the insula's location deep within the lateral sulcus. Stereotactic EEG can therefore be an important tool in cases of insular epilepsy so that patients may be appropriately diagnosed and evaluated for potential surgical treatment. We present 2 cases of epilepsy with nonlocalizing scalp EEG and challenging semiologies, the workup undertaken to identify them as cases of insular epilepsy, and subsequent surgical treatments and outcomes.

Pearls

- Insular seizures are among the great mimickers and can be mistaken for seizures originating from other regions of the brain, which can make diagnosis challenging.
- The importance of correctly diagnosing insular epilepsy lies in the opportunity for surgical treatment because any epilepsy that becomes drug-resistant should undergo surgical evaluation.

Oy-sters

- In rare cases, insular epilepsy can be mistaken for nonepileptic spells.
- Cases of negative or nonlocalizing scalp EEG with a history of stereotyped events should raise concern for epileptic seizures arising from deep cortical foci.

Case Report

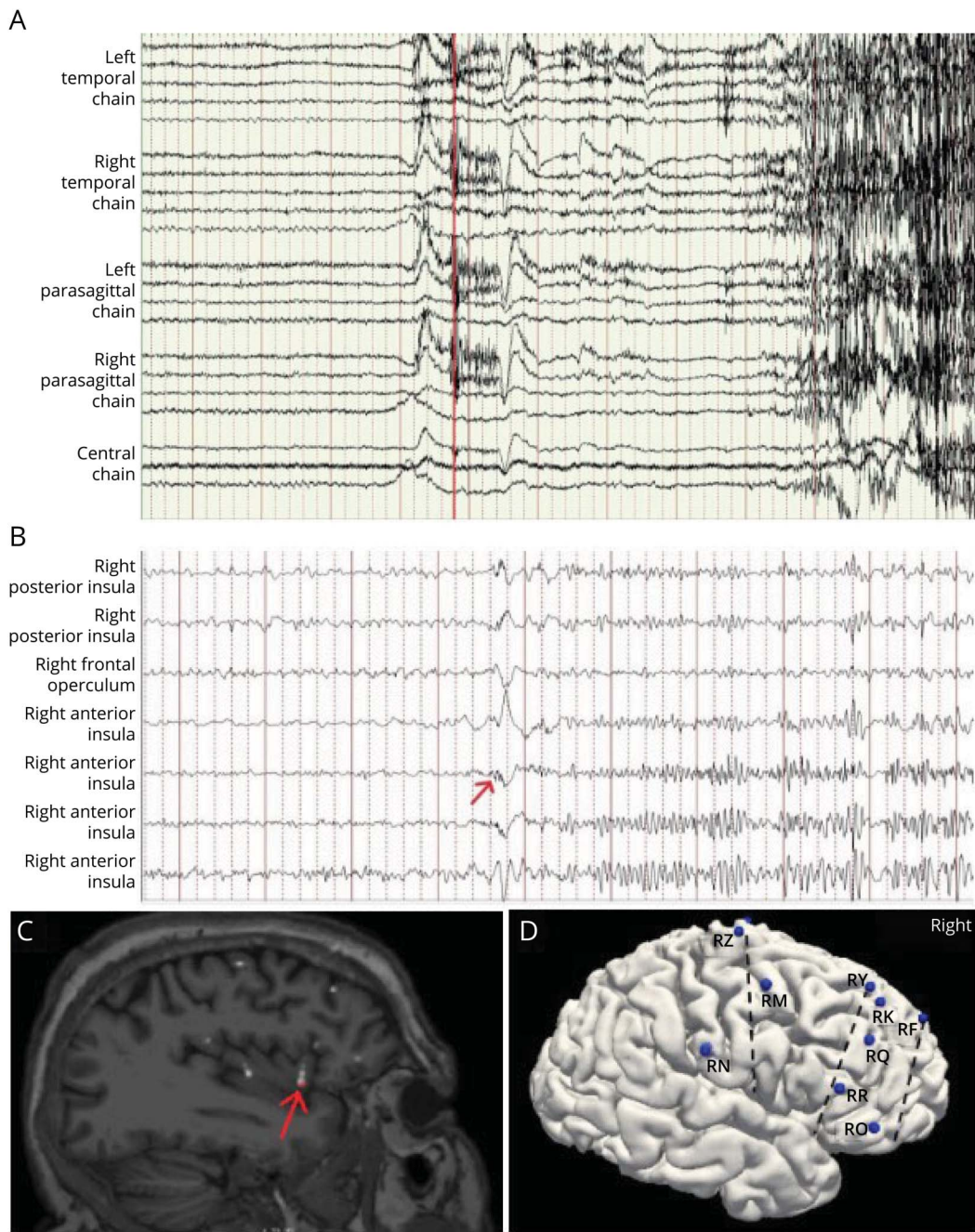
Case 1

A 53-year-old right-handed man developed seizures at the age of 16 years. Semiology was described as bilateral facial tingling and hyperkinetic movements (clapping and slapping his head) that lasted 15–60 seconds with retained awareness and immediate return to baseline. Seizure frequency was 1–3 times daily. He had been diagnosed with nonepileptic spells for years, and when he was later diagnosed with epilepsy, he had failed 10 antiseizure medications (ASMs). His most recent epilepsy monitoring unit (EMU) evaluation showed ictal scalp EEG with subtle generalized electrodecrement at event onset followed by movement artifact (Figure 1A), and interictal EEG was normal. Brain MRI was normal, ictal single-photon emission computed tomography (SPECT) showed subtle right frontotemporal hypoperfusion, and neuropsychological testing showed subtle right frontal lobe dysfunction. Magnetoencephalography

From the Adult Neurology Residency Program (D.L.), University of Texas Southwestern Medical Center; Department of Neurology (I.P., M.D., G.P.), University of Texas Southwestern Medical Center, Dallas.

Go to [Neurology.org/N](https://www.neurology.org/N) for full disclosures. Funding information and disclosures deemed relevant by the authors, if any, are provided at the end of the article.

Figure 1 Scalp EEG and Stereotactic EEG (SEEG) Evaluation in Case 1



(A) Scalp EEG with clinical onset marked by a red line. Sensitivity 7 μ V, low-frequency filter 1.5 Hz, high-frequency filter 70 Hz, 15-second page, bipolar montage. (B) SEEG with ictal onset marked by a red arrow. Sensitivity 20 μ V, low-frequency filter 5.3 Hz, high-frequency filter 300 Hz, 10-second page, bipolar montage. (C) Coregistration of SEEG electrode and MRI brain with a red arrow indicating electrode contact within the right anterior insula where ictal SEEG onset was observed. (D) SEEG implantation map of the right hemisphere (left hemisphere not included, but SEEG coverage was symmetric), with electrodes and their most mesial to most superficial contacts as follows: RZ, posterior insula-middle frontal gyrus; RY, anterior insula-superior frontal gyrus; RR, anterior insula-inferior frontal gyrus; RN, frontal operculum-postcentral gyrus; RM, superior frontal gyrus-middle frontal gyrus; RK, superior frontal gyrus (mesial)-superior frontal gyrus (lateral); RQ, anterior cingulate-middle frontal gyrus; RO, gyrus rectus-inferior frontal gyrus; RF, posterior orbital gyrus-middle frontal gyrus.

(MEG) was nondiagnostic, showing isolated dipoles in the left posterior insula and left temporal neocortex, thought to represent field from interictal activity, artifact, or normal variant. Stereotactic EEG (SEEG) identified seizure onset in the right anterior insula, seen as low-voltage beta-frequency activity within the right anterior insula with almost

simultaneous (within milliseconds) involvement of the right frontal operculum and right posterior insula, followed by subsequent evolution over both insulae, mesial frontal cortices, and anterior cingulate gyri (Figure 1B–D). This was reproducible with cortical stimulation. He underwent right anterior insular resection without complications, and pathology did not show

any abnormalities. He is now over 2 years postresection and remains seizure-free on medications.

Case 2

A 42-year-old right-handed man developed seizures at the age of 4 years. Semiology was described as right eye blinking, a cold feeling in his left arm, sensation of left foot pressure, and bilateral hyperkinetic movements (cheek puffing, crying, and sliding up and down in bed) that lasted 30–60 seconds with retained awareness and immediate return to baseline. Seizure frequency was almost daily, and he had failed 19 ASMs and vagal nerve stimulation. His most recent EMU evaluation showed ictal scalp EEG with diffuse voltage suppression at the onset followed by movement artifact (Figure 2A), and interictal EEG was normal. Brain MRI was normal, ictal SPECT showed hypoperfusion in the right parietotemporal region and right visual cortex, and MEG showed dipole clusters in the posterior frontal and central cortical areas bilaterally but was of uncertain reliability because of dipole morphology, and neuropsychological testing showed nonlateralizing frontal lobe dysfunction. SEEG identified seizure onset from the right anterior insula and frontal operculum, seen as low voltage, sharply countered beta-frequency activity within the right anterior insula with evolution over both insulae, mesial frontal cortices, and anterior cingulate gyri (Figure 2B–D). Events were reproducible with cortical stimulation. He underwent resection of the right anterior insula and frontal operculum without complications, and pathology showed subpial gliosis and ectopic neurons in the subcortical white matter. He is now 4 years postresection, and seizure frequency has improved to once every several months on medications.

Discussion

The diagnostic process for insular epilepsy can be challenging because insular seizures can mimic seizures arising from elsewhere in the brain or even be mistaken for nonepileptic spells.^{1,2} To summarize our cases, both patients had hypermotor seizures, which are usually frontal lobe in origin, but they also had sensory auras. In addition, our patients had nonlocalizing scalp EEGs demonstrating only subtle electrodecrement at ictal onset with stereotyped events, suggesting a deep seizure focus. Therefore, SEEG sampling was targeted to sample the sensory cortex and deep areas of the brain that could generate hypermotor seizures. Although both patients had nonlesional brain MRIs, their presurgical evaluations had some lateralizing features, such as the ictal SPECT and neuropsychological testing for case 1 and the ictal SPECT in case 2. Nevertheless, SEEG sampling was symmetric given the lack of strong lateralizing signs and to account for the possibility of false lateralization from fast spread of ictal activity to the contralateral insula.³ In case 1, 3 electrodes were placed in each insula for a total of 24 contacts (with 11 on the right), and in case 2, one electrode was placed in each insula for a total of 4 contacts (with 3 on the right).

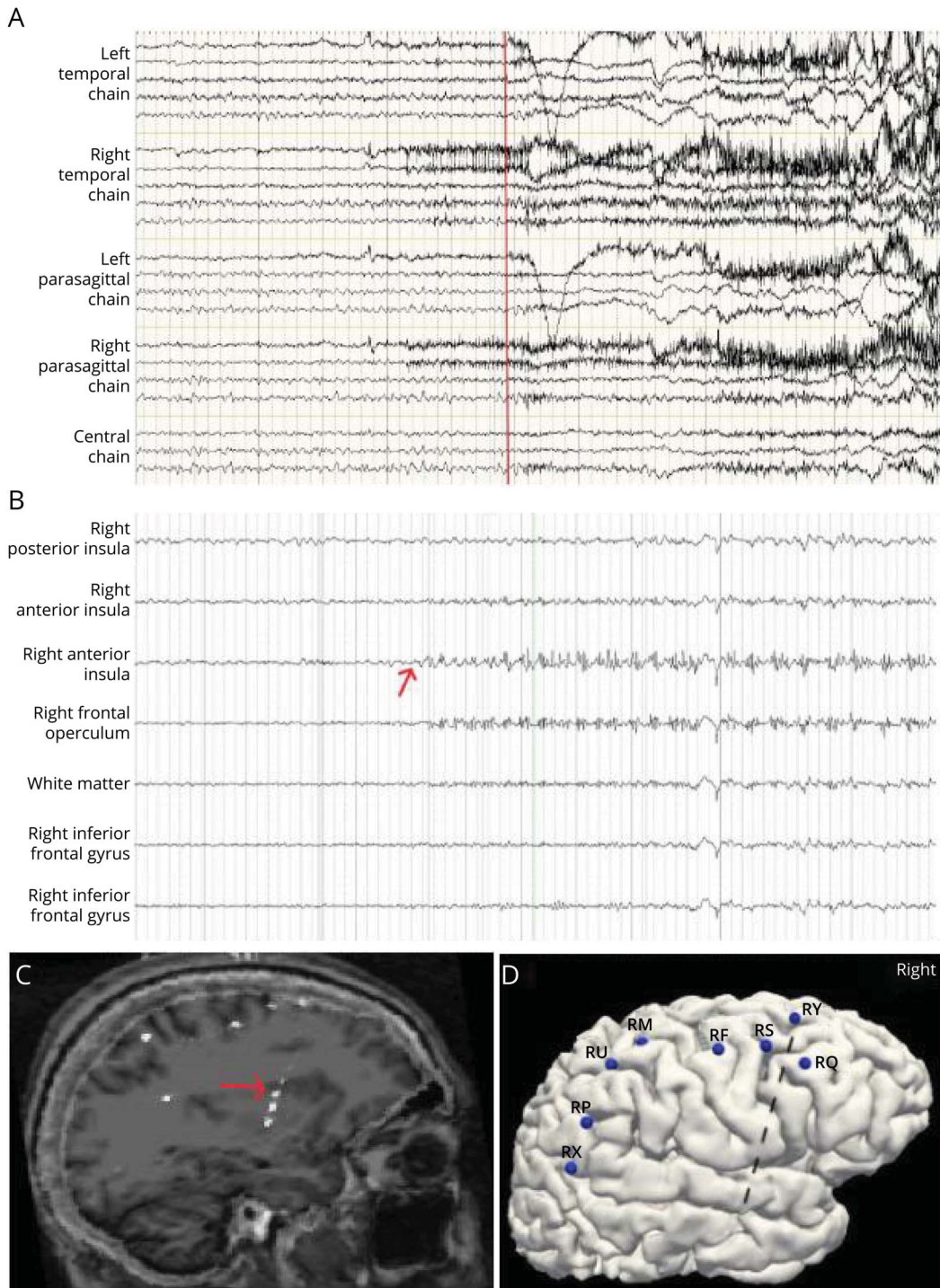
Part of the difficulty in diagnosing insular epilepsy lies in the depth of the insula and the unusual semiologies it can produce. To review, the insula is an area of cortex located within the lateral sulcus and surrounded by the frontal, temporal, and parietal lobes. Human studies with *in vivo* tracers have demonstrated numerous connections between the insula and these surrounding structures, and functional neuroimaging has identified several regions of the insula that are involved in operations ranging from autonomic function to perception of visceral and somatic pain to auditory processing.⁴

From this, it follows that the semiology of insular epilepsy reflects not only the functions of the insula itself but also the connections between the insula and the surrounding brain structures as the seizure evolves and spreads.⁵ This results in considerable overlap between the semiology of insular epilepsy and that of temporal lobe, frontal lobe, or perisylvian epilepsy.^{1,2} The dense connections between the bilateral insulae can even mimic bitemporal lobe epilepsy.³ The semiology of insular epilepsy can include characteristics such as auditory illusions, paresthesias or sensations of warmth, gastric rising, autonomic manifestations (tachycardia and hyperventilation), feelings of fear or anxiety, laryngeal constriction, and hyperkinetic movements.^{6–8} This has been demonstrated both through observation and through cortical stimulation of the insula in SEEG patients.⁶ Nevertheless, insular seizures are diverse and can ultimately seem like seizures originating from many other areas of the brain.¹

Scalp EEG may be negative or nonlocalizing in cases of nonepileptic spells, seizures involving a small cortical area, or seizures involving deep cortical foci, as in our cases. Brain MRI can also be unremarkable in insular epilepsy. In a review of 25 patients who underwent operculoinsular cortectomy for epilepsy, 72% of them had MRIs that were normal or showed nonspecific findings,⁹ although focal insular abnormalities have also been reported.¹⁰ Other noninvasive modalities include MEG, ictal SPECT, interictal PET, and proton magnetic resonance spectroscopy. A study of 14 patients with known insular epilepsy demonstrated the superiority of MEG to ictal SPECT and interictal PET in localizing the seizure focus, whereas a study of proton magnetic resonance spectroscopy on 22 patients with epilepsy did not show a significant difference in spectroscopy findings between patients with insular seizures and those with extrainsular seizures.¹¹ Ultimately, details of the noninvasive workup and seizure semiology should be used to guide SEEG implantation during presurgical evaluation.⁷

The importance of correctly diagnosing insular epilepsy lies in the possibility of surgical treatment. For focal epilepsy, surgery is superior to prolonged medical therapy for seizure control and quality of life,¹² emphasizing the need to correctly identify the epileptogenic focus. On the contrary, postoperative complications and deficits are a risk of any epilepsy surgery that must be balanced with the goal of seizure control. Early experience with open insular resections showed high morbidity (20%–45%) and mortality,^{13,14} but in a more recent series, insular lesionectomy

Figure 2 Scalp EEG and Stereotactic EEG (SEEG) Evaluation in Case 2



(A) Scalp EEG with clinical onset marked by a red line. Sensitivity 7 μ V, low-frequency filter 1.5 Hz, high-frequency filter 70 Hz, 15-second page, bipolar montage. (B) SEEG with ictal onset marked by a red arrow. Sensitivity 30 μ V, low-frequency filter 5.3 Hz, high-frequency filter 300 Hz, 15-second page, bipolar montage. (C) Coregistration of SEEG electrode and MRI brain with a red arrow indicating electrode contact within the right anterior insula where the ictal SEEG onset was observed. (D) SEEG implantation map of the right hemisphere (left hemisphere not included, but SEEG coverage was symmetric), with electrodes and their most mesial to most superficial contacts listed as follows: RY, posterior insula-superior frontal sulcus; RQ, midcingulate cortex-middle frontal gyrus; RS, cingulate sulcus-middle frontal gyrus; RF, supplementary motor area-middle frontal gyrus; RM, cingulate sulcus-central sulcus; RU, postcentral sulcus (mesial)-postcentral sulcus (lateral); RP, precuneus-angular gyrus; RX, posterior cingulate cortex-angular gyrus.

was associated with an 8% rate of permanent morbidity and no mortalities.¹³ Transient postoperative deficits include changes in taste and smell, difficulties with speech or swallowing, hemiparesis,

and alterations in sensory perception.^{9,15} Permanent motor deficits are associated with resection of the caudal dorsal insula. Alternative treatments, such as responsive neurostimulation or

stereotactic laser ablation, are recommended for treatment of seizures arising from this area.¹ It is fortunate that our patients did not have complications from their surgeries.

SEEG was crucial in localizing the epileptogenic zone in our patients because it can be difficult to diagnose insular epilepsy with noninvasive testing.⁷ In both patients, SEEG ictal evolution was only seen over the insula, mesial frontal cortex, and anterior cingulate gyrus. As a result, ictal activity was not clearly seen on scalp EEG, which instead showed generalized electrodecrement at event onset that was further obscured by movement artifact in both patients. These cases illustrate the importance of surgical evaluation in patients with refractory focal epilepsy. Resective surgery took place more than 30 years after epilepsy onset for both patients, including after many years of a diagnosis of non-epileptic spells in case 1. Surgery has subsequently improved quality of life, leading to seizure freedom in the first patient and significantly improved seizure burden in the second. These cases highlight the importance of recognizing the unusual semiology of insular epilepsy and the workup needed to identify it.

Study Funding

No targeted funding reported.

Disclosure

The authors report no relevant disclosures. Go to Neurology.org/N for full disclosures.

Publication History

Received by *Neurology* October 1, 2021. Accepted in final form June 3, 2022. Submitted and externally peer reviewed. The handling editor was Roy Strowd III, MD, Med, MS.

Appendix Authors

Name	Location	Contribution
Denise Li, MD	Adult Neurology Residency Program, University of Texas Southwestern Medical Center	Drafting/revision of the manuscript for content, including medical writing for content
Irina Podkorytova, MD	Department of Neurology, University of Texas Southwestern Medical Center	Drafting/revision of the manuscript for content, including medical writing for content; major role in the acquisition of data; study concept or design; analysis or interpretation of data

Appendix (continued)

Name	Location	Contribution
Marisara Dieppa, MD	Department of Neurology, University of Texas Southwestern Medical Center	Drafting/revision of the manuscript for content, including medical writing for content; major role in the acquisition of data; study concept or design; analysis or interpretation of data
Ghazala Perven, MD	Department of Neurology, University of Texas Southwestern Medical Center	Major role in the acquisition of data; study concept or design; analysis or interpretation of data

References

- Jobst BC, Gonzalez-Martinez J, Isnard J, et al. The insula and its epilepsies. *Epilepsy Currents*. 2019;19(1):11-21. doi: 10.1177/1535759718822847
- Ryvlin P, Minotti L, Demarquay G, et al. Nocturnal hypermotor seizures, suggesting frontal lobe epilepsy, can originate in the insula. *Epilepsia*. 2006;47(4):755-765. doi: 10.1111/j.1528-1167.2006.00510.x
- Unnwongse K, Jehi L, Bulacio J, Gonzalez-Martinez J, Najm I. Contralateral insular involvement producing false lateralizing signs in bitemporal epilepsy: a stereo-electrocephalography case report. *Seizure*. 2012;12(10):816-819. doi: 10.1016/j.seizure.2012.08.013
- Uddin LQ, Nomi JS, Hebert-Seropian B, Ghaziri J, Boucher O. Structure and function of the human insula. *J Clin Neurophysiol*. 2017;34(4):300-306. doi: 10.1097/WNP.0000000000000377
- Singh R, Principe A, Tadel Eng F, et al. Mapping the insula with stereo-electroencephalography: the emergence of semiology in insula lobe seizures. *Ann Neurol*. 2020;88:477-488. doi: 10.1002/ana.25817
- Isnard J, Guénot M, Sindou M, Mauguière F. Clinical manifestations of insular lobe seizures: a stereo-electroencephalographic study. *Epilepsia*. 2004;45(9):1079-1090. doi: 10.1111/j.0013-9580.2004.68903.x
- Alomar S, Mullin JP, Smithason S, Gonzalez-Martinez J. Indications, technique, and safety profile of insular stereo-electroencephalography electrode implantation in medically intractable epilepsy. *J Neurosurg*. 2018;128(4):1147-1157. doi: 10.3171/2017.1.JNS161070
- Montavont A, Mauguière F, Mazzola L, et al. On the origin of painful somatosensory seizures. *Neurology*. 2015;84(6):594-601. doi: 10.1212/WNL.0000000000001235
- Bouthillier A, Nguyen DK. Epilepsy surgeries requiring an operculoinsular cortectomy: operative technique and results. *Neurosurgery*. 2017;81(4):602-612. doi: 10.1093/neuros/nyx080
- Proserpio P, Cossu M, Francione S, et al. Insular-opercular seizures manifesting with sleep-related paroxysmal motor behaviors: a stereo-EEG study. *Epilepsia*. 2011;52(10):1781-1791. doi: 10.1111/j.1528-1167.2011.03254.x
- Obaid S, Zerouali Y, Nguyen DK. Insular epilepsy: semiology and noninvasive investigations. *J Clin Neurophysiol*. 2017;34(4):315-323. doi: 10.1097/WNP.0000000000000396
- Wiebe S, Blume WT, Girvin JP, Eliasziw M. A randomized, controlled trial of surgery for temporal-lobe epilepsy. *N Engl J Med*. 2001;345(5):311-318. doi: 10.1056/NEJM200108023450501
- Von Lehe M, Wellmer J, Urbach H, et al. Insular lesionectomy for refractory epilepsy: management and outcome. *Brain*. 2009;132(4):1048-1056. doi: 10.1093/brain/awp047
- Silfvenius H, Gloor P, Rasmussen T. Evaluation of insular ablation in surgical treatment of temporal lobe epilepsy. *Epilepsia*. 1964;5:307-320. doi: 10.1111/j.1528-1157.1964.tb03338.x
- Von Lehe M, Parpaley Y. Insular cortex surgery for the treatment of refractory epilepsy. *J Clin Neurophysiol*. 2017;34(4):333-339. doi: 10.1097/WNP.0000000000000393

Free CME self-assessment with AAN membership. Visit AAN.com/NeuroSAE today.

Neurology[®]

Pearls & Oy-sters: Two Cases of Stereotactic EEG-Proven Insular Epilepsy With Nonlocalizing Scalp EEG and Interesting Semiologies

Denise Li, Irina Podkorytova, Marisara Dieppa, et al.

Neurology 2022;99;437-441 Published Online before print June 28, 2022

DOI 10.1212/WNL.0000000000200993

This information is current as of June 28, 2022

Updated Information & Services	including high resolution figures, can be found at: http://n.neurology.org/content/99/10/437.full
References	This article cites 15 articles, 1 of which you can access for free at: http://n.neurology.org/content/99/10/437.full#ref-list-1
Subspecialty Collections	This article, along with others on similar topics, appears in the following collection(s): All Epilepsy/Seizures http://n.neurology.org/cgi/collection/all_epilepsy_seizures EEG http://n.neurology.org/cgi/collection/eeg_ Epilepsy semiology http://n.neurology.org/cgi/collection/epilepsy_semiology Epilepsy surgery http://n.neurology.org/cgi/collection/epilepsy_surgery_ Intracranial electrodes http://n.neurology.org/cgi/collection/intracranial_electrodes
Permissions & Licensing	Information about reproducing this article in parts (figures, tables) or in its entirety can be found online at: http://www.neurology.org/about/about_the_journal#permissions
Reprints	Information about ordering reprints can be found online: http://n.neurology.org/subscribers/advertise

Neurology® is the official journal of the American Academy of Neurology. Published continuously since 1951, it is now a weekly with 48 issues per year. Copyright © 2022 American Academy of Neurology. All rights reserved. Print ISSN: 0028-3878. Online ISSN: 1526-632X.

