

Future of Neurology & Technology: Stereoelectroencephalography in Presurgical Epilepsy Evaluation

Guillermo Delgado-Garcia, MD, MSc, and Birgit Frauscher, MD, PD

Neurology® 2022;98:e437-e440. doi:10.1212/WNL.0000000000013088

Correspondence

Dr. Frauscher
birgit.frauscher@mcgill.ca

Abstract

Stereoelectroencephalography (SEEG) is not only a sophisticated and highly technological investigation but a new and better way to conceptualize the spatial and temporal dynamics of epileptic activity. The first intracranial investigations with SEEG were performed in France in the mid-twentieth century; however, its use in North America is much more recent. Given its significantly lower risk of complications and its ability to sample both superficial and deep structures and both hemispheres simultaneously, SEEG has become the preferred method to conduct intracranial EEG monitoring in most comprehensive epilepsy centers in North America. SEEG is an invasive neurophysiologic methodology used for advanced presurgical workup in the 20% of drug-resistant patients with more complex focal epilepsy in whom noninvasive investigations do not allow to decide on surgical candidacy. SEEG uses stereotactically implanted depth electrodes to map the origin and propagation of epileptic seizures by creating a 3-dimensional representation of the abnormal electrical activity in the brain. SEEG analysis takes into account the background, interictal, and ictal activity, as well as the results of cortical electrical stimulation procedures, to reliably delineate the epileptogenic network. By means of a clinical vignette, this article will walk general neurologists, but especially neurology trainees through the immense potential of this methodology. In summary, SEEG enables to accurately identify the epileptogenic zone in patients with drug-resistant focal epilepsy who otherwise would be not amenable to surgical treatment. In this patient population, SEEG is the best way to improve seizure control and achieve seizure freedom.

From the Department of Clinical Neurosciences (G.D.-G.), Cumming School of Medicine, University of Calgary, Canada; Centro de Investigación y Desarrollo en Ciencias de La Salud (G.D.-G.), Universidad Autónoma de Nuevo León, Monterrey, Mexico; and Analytical Neurophysiology Lab & Epilepsy Program (B.F.), Montreal Neurological Institute and Hospital, McGill University, Canada.

Go to [Neurology.org/N](https://www.neurology.org/N) for full disclosures. Funding information and disclosures deemed relevant by the authors, if any, are provided at the end of the article.

At least 1 in 10 patients with epilepsy will fail 2 well-tolerated and appropriately chosen antiseizure medications, and this is even more common in focal epilepsy.¹ Surgery revolutionized the management of patients with drug-resistant focal epilepsy and, for them, represents the best way to improve seizure control and sometimes even result in seizure freedom (SF).² These patients should be timely referred to epilepsy centers to determine surgical amenability. Presurgical evaluation has the goal of identifying the epileptogenic zone (EZ, i.e., the minimum cortical area whose removal is necessary for SF).

A phase 1 (noninvasive) workup includes prolonged scalp video-EEG monitoring, structural and functional neuroimaging, and neuropsychological assessment. Magnetoencephalography, high-density EEG (HD-EEG), and combined EEG/MRI are additional auxiliary investigations. The exact combination of studies varies depending on the individual patient's needs.

Some epilepsies are more complex than others and may therefore require invasive investigations (phase 2). This is the case in patients with inconclusive brain MRI, discordant findings in phase 1 workup, or close vicinity of the assumed EZ to eloquent cortex. In patients with such features, a phase 2 evaluation is needed to determine surgical candidacy. Phase 2 investigations are defined by their invasiveness and include electrocorticography, subdural electrodes (SDE, i.e., strips and grids), and stereoelectroencephalography (SEEG). Nowadays, SEEG has become the principal method for intracranial EEG monitoring in most epilepsy centers in North America.³ This article will introduce general neurologists, but especially neurology trainees to the potential of SEEG.

a sensation involving her entire body, similar to a wave starting in the middle of the stomach and going up and down and then tactile hypersensitivity, restlessness, and anxiety. Sometimes, this evolved into left arm stiffening and, more rarely, to left leg shaking and then impaired awareness. These seizures started at age 12 years. Epilepsy risk factors were negative. She failed 4 antiseizure medications and was having 10 seizures per month. Her prolonged scalp video-EEG monitoring captured only late ictal EEG changes over the right central midline region. The interictal EEG was noncontributory. A 3-Tesla MRI showed a suspicious sulcus in the right posterior cingulate with subtle transmantle sign (Figure, A and B). An unusual sulcogyral morphology was also seen in the right anterior cingulate. The rest of the phase 1 investigations (i.e., neuropsychology, functional neuroimaging, magnetoencephalography, and HD-EEG) were noncontributory.

SEEG was proposed. The main hypothesis was a right hemispheric, midline close, deep seated EZ in the parietal lobe in keeping with the potential MRI lesion. Alternatively, a mesiofrontal generator and an anterior insula generator with rapid mesiofrontal propagation were considered. To test these hypotheses, 16 depth electrodes were implanted over the right hemisphere (Figure, C). Ictal recordings demonstrated that all seizures originated from the right midline parietal region (i.e., the presumed focal cortical dysplasia [FCD] seen on MRI) with rapid spread to the ipsilateral supplementary motor area (Figure, main panel and B). This patient underwent a selective right posterior cingulate cortical resection, and histopathology revealed FCD type 2a. No seizure recurrence has occurred since surgery 3 years ago.

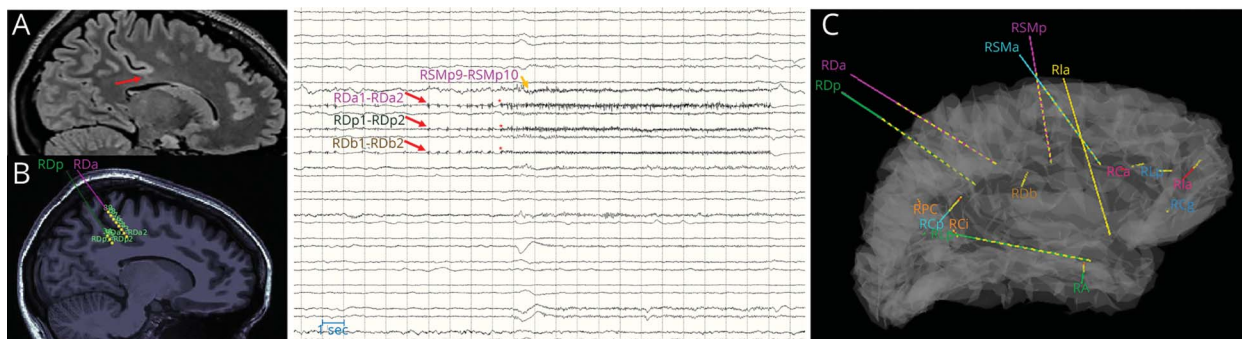
Clinical Vignette

A 25-year-old right-handed woman presented with sleep-related focal aware seizures characterized by an arousal due to

SEEG: The What and the How

SEEG is an advanced invasive neurophysiologic methodology that uses multicontact intracerebral depth electrodes to

Figure Implantation Scheme and SEEG Ictal Findings



(A) Subtle transmantle sign in the right posterior cingulate gyrus (red arrow). Courtesy of Neda Bernasconi, MD, PhD, and Andrea Bernasconi, MD (MNI). (B) Intracranial trajectories of 2 depth electrodes targeting the suspected focal cortical dysplasia (FCD). Courtesy of Chifaou Abdallah, MD (MNI). Main panel: Spontaneous ictal SEEG recording showing a midline parietal onset with a build-up of polyspikes (red arrows), followed by low-voltage fast activity (red asterisks), and then spread to the ipsilateral supplementary motor area (yellow arrow). Postictal suppression was seen on the channels involved at seizure onset. (C) Sixteen depth electrodes implanted in the right hemisphere; they were chosen to answer the main hypothesis and 2 alternative hypotheses described in the text. For electrodes' names, the main panel and panel C share the same color code. A written authorization was obtained from the patient to reproduce these images.

record from superficial and deep brain structures to obtain 3-dimensional representations of the seizure-onset zone (SOZ, i.e., the brain region where seizures are seen to start in the EEG) and epileptogenic network. This method has advanced considerably since its inception in the mid-twentieth century by Jean Talairach (1911–2007) and Jean Bancaud (1921–1993).⁴ It now also allows for not only tailoring resection to the minimum amount needed to achieve SF, but it also can be used to conduct (or guide) therapeutic procedures such as radiofrequency thermocoagulation, thermoablation, and responsive neurostimulation.

Interdisciplinary collaboration is a critical component of SEEG, and neurologists with subspecialization in epileptology or clinical neurophysiology play a key role during the entire process, including implantation planning, interpretation, and finally resection planning. Human SEEG recordings are already used in experimental neuroscience,⁴ and in the very near future, SEEG clinical applications will likely expand and impact on medical domains outside of epileptology such as neuropsychiatry and cognitive neurology.

SEEG uses stereotactically implanted electrodes to map the epileptogenic network through the analysis of spatiotemporal dynamics of ictal and interictal discharges. SEEG relies on Bancaud analytical framework termed anatomo-electro-clinical correlation. This term refers to the way how we correlate the onset and evolution of abnormal electrical brain activity with brain anatomy and clinical manifestations. SEEG is a hypothesis-driven process, and to overcome the issue of a limited coverage—a limitation inherent to SEEG but also all other methods of intracranial EEG recording—one main hypothesis with 1 or 2 alternative hypotheses is typically assessed. Seizure semiology is the driving force of hypothesis generation that is then further complemented by results from phase 1 investigations. As the risk of complications increases with the number of implanted electrodes,⁵ the implantation should be planned to answer predefined hypotheses, and therefore, no standard schemes are recommended.

SEEG signal data are then acquired using a system with capacity for at least 128 channels, preferably at a higher sampling rate. Synchronized video recording is essential for SEEG explorations to allow for a reliable anatomo-electro-clinical correlation. Background, interictal, and ictal activity, as well as data derived from cortical electrical stimulation (CES), is then assessed by an SEEG-trained neurologist or neurophysiologist. The main indications of CES are mapping of cortical functioning (e.g., language function) and reproducing habitual seizures, which has shown to add relevant information to the presurgical workup.⁶

After capturing enough intracranial data to postulate the anatomic location of the SOZ, surgical candidacy is determined by a multidisciplinary team that interprets SEEG findings in consideration of the whole armamentarium obtained during the complete presurgical evaluation.

SEEG is considered to be the safest intracranial EEG recording modality with complication rates of 0.6%–2%, including asymptomatic—and considerably less frequent symptomatic—intracerebral hemorrhages and transient postsurgical nonhemorrhagic neurologic deficits.⁵ Admissions for SEEG exceeding 4 weeks are not recommended due to patient-related factors and a higher risk of infectious complications.⁵ In addition, SEEG is the only intracranial EEG option to sample deep regions, delineate epileptogenic networks, and also safely conduct bilateral explorations, as in suspected bitemporal epilepsy.⁴

Until very recently, SDE was the mainstay of intracranial EEG monitoring in North America.³ Although SDE spatial coverage is often thought to be superior in the neocortex, this is only true for gyri, but not sulci.⁷ Regarding surgical outcomes, SEEG is at least noninferior to SDE: slightly lower surgical resections (76.9 vs 81.6%) are outbalanced by better SF outcomes (61.0 vs 56.4%).⁸ In contrast to SDE, SEEG is better tolerated⁹ and also associated with lower morbidity (4.8 vs 15.5%) and mortality (0.2 vs 0.4%).⁸

Training Opportunities

SEEG training is recommended for the whole team involved in this procedure. For neurologists, some authors have suggested either a minimum of a 6-month training or participation in at least 10 SEEGs in a center with a minimum of 5 years of experience.¹⁰ At present, there are no clinical fellowship programs specifically focused on SEEG. However, this training is available at some epilepsy centers in North America as a part of epilepsy or clinical neurophysiology fellowships, especially for second-year or advanced fellows.

The Grenoble-Lyon-Milan alliance¹¹ and Cleveland Clinic offer introductory courses on SEEG. Although these courses do not intend to replace a formal training in an experienced center, they are a great starting point. An additional educational initiative is the Montreal Neurological Institute (MNI) Open Intracranial EEG Atlas, a freely available online resource illustrating brain activity during both wakefulness and sleep across 38 different cortical regions.¹²

Research Opportunities

SEEG is a flourishing field for epilepsy research and research on experimental neurophysiology.⁴ Within epilepsy, new computerized approaches for EZ localization based on ictal or interictal data are currently in development. The aim of these algorithms is to improve localization accuracy, reduce functional deficits and the time needed for presurgical evaluation, and predict reliably the probability of SF after surgery. Hopefully, in the near future, these new techniques will inform clinical decisions during presurgical epilepsy workup. Human SEEG-derived data are also increasingly used by neuroscientists.⁴ For instance, the Functional Brain Tractography international project aims to improve our knowledge on large-scale human brain connectivity using low-frequency CES

in patients with epilepsy who are surgical candidates.¹³ SEEG-derived data have also contributed extensively to elucidate the local aspects of human sleep.¹⁴ These findings may soon have a clinical translation to different fields including neuropsychiatry, cognitive neurology, and sleep medicine.

Conclusions

In summary, SEEG is an invasive neurophysiologic methodology originally proposed to map the SOZ, and it is currently used for advanced presurgical workup in patients with complex focal epilepsies. Research opportunities in this area are multiple and not only related to epilepsy. For neurologists, SEEG provides a unique possibility for subspecialization given the rise of SEEG procedures in North America.

Acknowledgment

The authors thank Dr. Chifaou Abdallah (MNI), Dr. Andrea Bernasconi (MNI), and Dr. Neda Bernasconi (MNI) for sharing their images with them. These images are reproduced with authorization.

Study Funding

No targeted funding reported.

Disclosure

G. Delgado-Garcia is an editorial team member of the *Neurology Resident & Fellow Section*. He also sits on the editorial boards of *Neurology Clinical Practice* and *Brain & Life en Español*. B. Frauscher received honoraria for speaking engagements and advisory board meetings from/with UCB Pharma and Eisai. These engagements are not related to the current work. Go to Neurology.org/N for full disclosures.

Appendix Authors

Name	Location	Contribution
Guillermo Delgado-García, MD, MSc	University of Calgary	Designed and conceptualized the study; analyzed the data; interpreted the data; and drafted the manuscript for intellectual content
Birgit Frauscher, MD, PD	Montreal Neurological Institute and Hospital	Analyzed the data; interpreted the data; and revised the manuscript for intellectual content

References

1. Sultana B, Panzini MA, Veilleux Carpentier A, et al. Incidence and prevalence of drug-resistant epilepsy: a systematic review and meta-analysis. *Neurology*. 2021;96(17):805-817.
2. Wiebe S, Blume WT, Girvin JP, Eliasziw M. A randomized, controlled trial of surgery for temporal-lobe epilepsy. *N Engl J Med*. 2001;345(5):311-318.
3. Gavvala J, Zafar M, Sinha SR, Kalamangalam G, Schuele S. Stereotactic EEG practices: a survey of United States tertiary referral epilepsy centers. *J Clin Neurophysiol*. 2020. doi: 10.1097/WNP.0000000000000794. Epub 2020 Nov 10.
4. Lhatoo SD, Kahane PK, Lüders HO. *Invasive Studies of the Human Epileptic Brain: Principles and Practice*. Oxford University Press; 2018.
5. McGovern RA, Ruggieri P, Bulacio J, Najm I, Bingaman WE, Gonzalez-Martinez JA. Risk analysis of hemorrhage in stereo-electroencephalography procedures. *Epilepsia*. 2019;60(3):571-580.
6. Cuello Oderiz C, von Ellenrieder N, Dubeau F, et al. Association of cortical stimulation-induced seizure with surgical outcome in patients with focal drug-resistant epilepsy. *JAMA Neurol*. 2019;76(9):1070-1078.
7. Frauscher B, von Ellenrieder N, Zelmann R, et al. Atlas of the normal intracranial electroencephalogram: neurophysiological awake activity in different cortical areas. *Brain*. 2018;141(4):1130-1144.
8. Yan H, Katz JS, Anderson M, et al. Method of invasive monitoring in epilepsy surgery and seizure freedom and morbidity: a systematic review. *Epilepsia*. 2019;60(9):1960-1972.
9. Kim LH, Parker JJ, Ho AL, et al. Contemporaneous evaluation of patient experience, surgical strategy, and seizure outcomes in patients undergoing stereoelectroencephalography or subdural electrode monitoring. *Epilepsia*. 2021;62(1):74-84.
10. Isnard J, Taussig D, Bartolomei F, et al. French guidelines on stereoelectroencephalography (SEEG). *Neurophysiol Clin*. 2018;48(1):5-13.
11. The SEEG International Course. Accessed November 29, 2021. <https://seegcourse.com/>.
12. McGill Centre for Integrative Neuroscience (MCIN). Open Intracranial EEG Atlas. Accessed November 29, 2021. <https://mni-open-ieegatlas.research.mcgill.ca/>.
13. Olivier D, Saubat-Guigui C. Functional Brain Tractography Project. Accessed December 22, 2020. f-tract.eu/.
14. Frauscher B, Gotman J. Sleep, oscillations, interictal discharges, and seizures in human focal epilepsy. *Neurobiol Dis*. 2019;127:545-553.

Neurology®

Future of Neurology & Technology: Stereoelectroencephalography in Presurgical Epilepsy Evaluation

Guillermo Delgado-Garcia and Birgit Frauscher
Neurology 2022;98:e437-e440 Published Online before print November 19, 2021
DOI 10.1212/WNL.0000000000013088

This information is current as of November 19, 2021

Updated Information & Services	including high resolution figures, can be found at: http://n.neurology.org/content/98/4/e437.full
References	This article cites 10 articles, 1 of which you can access for free at: http://n.neurology.org/content/98/4/e437.full#ref-list-1
Subspecialty Collections	This article, along with others on similar topics, appears in the following collection(s): All Epilepsy/Seizures http://n.neurology.org/cgi/collection/all_epilepsy_seizures Cortical localization http://n.neurology.org/cgi/collection/cortical_localization EEG http://n.neurology.org/cgi/collection/eeg Epilepsy monitoring http://n.neurology.org/cgi/collection/epilepsy_monitoring Intracranial electrodes http://n.neurology.org/cgi/collection/intracranial_electrodes Other Education http://n.neurology.org/cgi/collection/other_education Status epilepticus http://n.neurology.org/cgi/collection/status_epilepticus
Permissions & Licensing	Information about reproducing this article in parts (figures, tables) or in its entirety can be found online at: http://www.neurology.org/about/about_the_journal#permissions
Reprints	Information about ordering reprints can be found online: http://n.neurology.org/subscribers/advertise

Neurology® is the official journal of the American Academy of Neurology. Published continuously since 1951, it is now a weekly with 48 issues per year. Copyright © 2021 American Academy of Neurology. All rights reserved. Print ISSN: 0028-3878. Online ISSN: 1526-632X.

