

# Brainstem Infarction and Vertebral Artery Vasculopathy After Ramsay Hunt Syndrome

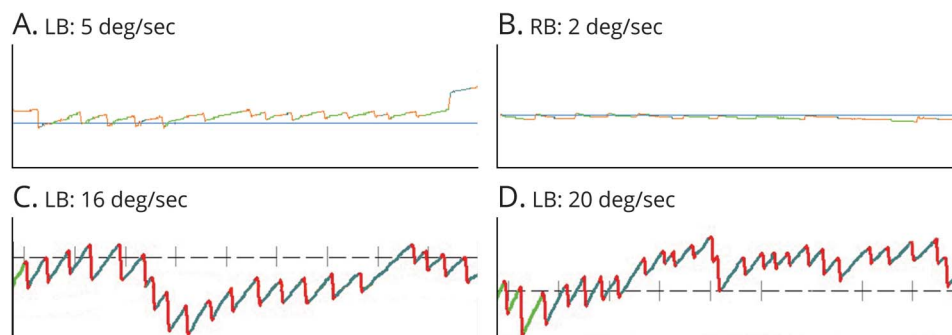
Huiying Sun, MD,\* Hui You, MD,\* and Haiyan Wu, MD

*Neurology*® 2022;98:890-891. doi:10.1212/WNL.0000000000200522

**Correspondence**

Dr. Wu  
ywjwhy@sina.com

**Figure 1** Nystagmus at the Initial Visit



(A) Leftward nystagmus when gazing left. (B) Rightward nystagmus when gazing right. (C) Leftward nystagmus after shaking the head. (D) Enhanced leftward head-shaking nystagmus when tilting the head forward. LB = left beat; RB = right beat.

A 45-year-old man presented with right auricle rash, facial weakness, otalgia, deafness, and transient dizzy spells. He had leftward spontaneous, bidirectional gaze-evoked and unsuppressed leftward head-shaking nystagmus in head-shaking tilt suppression test (Figure 1). MRI results showed a subacute infarct on the right dorsolateral pons and medulla oblongata and incomplete flow void in the right vertebral artery. After acyclovir and dexamethasone therapy, the ischemic lesion and vascular narrowing on MRI vanished and the patient's symptoms disappeared (Figure 2). Concomitant intracranial vasculopathy and brainstem stroke may occur in Ramsay Hunt syndrome,<sup>1,2</sup> which could be easily missed but possibly detected by careful eye movement assessments.

## Study Funding

This work was supported by the Beijing Natural Science Foundation (7222313).

## Disclosure

The authors report no disclosures relevant to the manuscript. Go to [Neurology.org/N](http://Neurology.org/N) for full disclosures.

## Publication History

Received by *Neurology* November 17, 2021. Accepted in final form February 28, 2022. Submitted and editor reviewed. The handling editor was Editor-in-Chief José Merino, MD, MPhil.

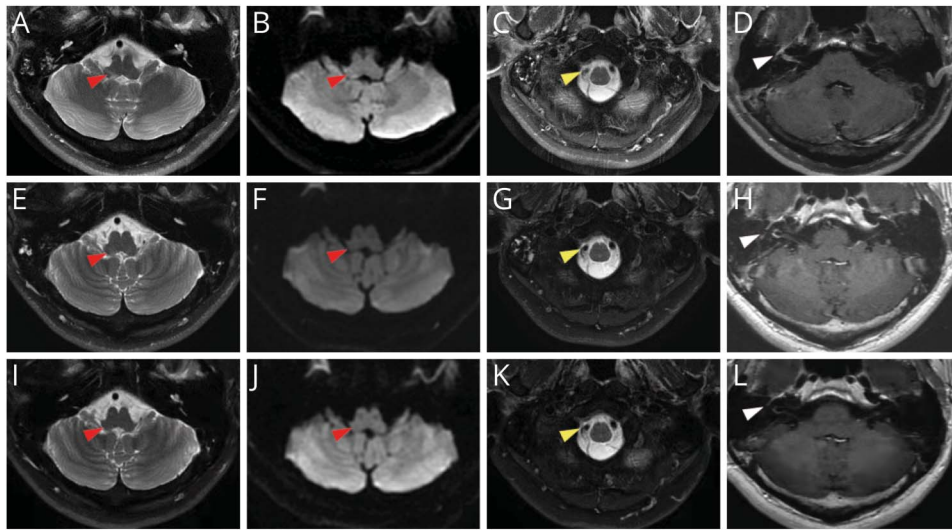
\*These authors contributed equally to this work.

From the Departments of Otorhinolaryngology (H.S., H.W.) and Radiology (H.Y.), Peking Union Medical College Hospital, Chinese Academy of Medical Sciences and Peking Union Medical College, Beijing, China.

Go to [Neurology.org/N](http://Neurology.org/N) for full disclosures.

This is an open access article distributed under the terms of the Creative Commons Attribution-NonCommercial-NoDerivatives License 4.0 (CC BY-NC-ND), which permits downloading and sharing the work provided it is properly cited. The work cannot be changed in any way or used commercially without permission from the journal.

**Figure 2** Head MRI



(A) Patchy shadow on right dorsolateral pons and medulla oblongata. (B) Hyperintense signal on diffusion-weighted imaging. (C) Incomplete flow void in right vertebral artery. (D) Enhanced facial nerve. (E-H) Lesions improved at 6-week follow-up. (I-L) Lesions disappeared at 1.5-year follow-up.

**Appendix** Authors

Name	Location	Contribution
<b>Huiying Sun, MD</b>	Department of Otorhinolaryngology, Peking Union Medical College Hospital, Chinese Academy of Medical Sciences and Peking Union Medical College, Beijing, China	Drafting/revision of the manuscript for content, including medical writing for content
<b>Hui You, MD</b>	Department of Radiology, Peking Union Medical College Hospital, Chinese Academy of Medical Sciences and Peking Union Medical College, Beijing, China	Major role in the acquisition of data

**Appendix** (continued)

Name	Location	Contribution
<b>Haiyan Wu, MD</b>	Department of Otorhinolaryngology, Peking Union Medical College Hospital, Chinese Academy of Medical Sciences and Peking Union Medical College, Beijing, China	Study concept or design

**References**

- Gilden D, Cohrs RJ, Mahalingam R, Nagel MA. Varicella zoster virus vasculopathies: diverse clinical manifestations, laboratory features, pathogenesis, and treatment. *Lancet Neurol.* 2009;8(8):731-740.
- Ortiz GA, Koch S, Forteza A, Romano J. Ramsay Hunt syndrome followed by multifocal vasculopathy and posterior circulation strokes. *Neurology.* 2008;70(13):1049-1051.

**Call for Voices: Lived Experiences**

The Editor of the *Neurology* specialty section Inclusion, Diversity, Equity, Anti-racism, & Social Justice (IDEAS) encourages you to submit short first-person accounts (1,000 words or less) of experiences lived within the realm of IDEAS with the goal of informing and enlightening our community on these critical issues. Some topics to consider include, but are not limited to:

- Descriptions of personal experiences that shaped your views of IDEAS.
- Reflections on the intersection between personal identity and career.
- Discussions at the intersection of IDEAS and neurology patient care, research, education, advocacy, or policy.

Submit your contributions to [journal@neurology.org](mailto:journal@neurology.org) and include “Voices Submission” in the subject line.

# Neurology®

## Brainstem Infarction and Vertebral Artery Vasculopathy After Ramsay Hunt Syndrome

Huiying Sun, Hui You and Haiyan Wu

*Neurology* 2022;98:890-891 Published Online before print March 29, 2022

DOI 10.1212/WNL.0000000000200522

**This information is current as of March 29, 2022**

<b>Updated Information &amp; Services</b>	including high resolution figures, can be found at: <a href="http://n.neurology.org/content/98/21/890.full">http://n.neurology.org/content/98/21/890.full</a>
<b>References</b>	This article cites 2 articles, 1 of which you can access for free at: <a href="http://n.neurology.org/content/98/21/890.full#ref-list-1">http://n.neurology.org/content/98/21/890.full#ref-list-1</a>
<b>Subspecialty Collections</b>	This article, along with others on similar topics, appears in the following collection(s): <b>Clinical neurology examination</b> <a href="http://n.neurology.org/cgi/collection/clinical_neurology_examination">http://n.neurology.org/cgi/collection/clinical_neurology_examination</a> <b>Infarction</b> <a href="http://n.neurology.org/cgi/collection/infarction">http://n.neurology.org/cgi/collection/infarction</a> <b>MRI</b> <a href="http://n.neurology.org/cgi/collection/mri">http://n.neurology.org/cgi/collection/mri</a> <b>Viral infections</b> <a href="http://n.neurology.org/cgi/collection/viral_infections">http://n.neurology.org/cgi/collection/viral_infections</a>
<b>Permissions &amp; Licensing</b>	Information about reproducing this article in parts (figures, tables) or in its entirety can be found online at: <a href="http://www.neurology.org/about/about_the_journal#permissions">http://www.neurology.org/about/about_the_journal#permissions</a>
<b>Reprints</b>	Information about ordering reprints can be found online: <a href="http://n.neurology.org/subscribers/advertise">http://n.neurology.org/subscribers/advertise</a>

*Neurology*® is the official journal of the American Academy of Neurology. Published continuously since 1951, it is now a weekly with 48 issues per year. Copyright © 2022 The Author(s). Published by Wolters Kluwer Health, Inc. on behalf of the American Academy of Neurology. All rights reserved. Print ISSN: 0028-3878. Online ISSN: 1526-632X.

