

Clinical Reasoning: A 73-Year-Old Woman With Episodic Dysarthria and Horizontal Binocular Diplopia

Aaron S. Bower, MD, Adeniyi Fisayo, MD, Joachim M. Baehring, MD, and Bhaskar Roy, MD

Neurology® 2022;98:767-772. doi:10.1212/WNL.000000000200347

Correspondence

Dr. Roy
bhaskar.roy@yale.edu

Abstract

A 73-year-old woman presented with transient episodes of dysarthria and horizontal diplopia. She had stereotactic radiosurgery 18 years prior for a retroclival meningioma. Neurologic examination was notable for right-sided tongue deviation, tongue fasciculations, and intermittent impaired abduction of the right eye. MRI ruled out recurrence or progression of the retroclival meningioma. EEG failed to reveal electrographic seizures. EMG showed spontaneous depolarizations in bursts that sounded like “marching soldiers” in the right hemitongue, consistent with myokymia. Focal myokymia is an unusual EMG finding that is usually seen in demyelinating disorders, after radiation, or in neoplastic/inflammatory conditions. The clinical presentation and EMG findings were most consistent with delayed radiation-induced myokymia. Similar cases of transient dysarthria and tongue myokymia from radiation have been infrequently reported in the literature; however, this case uniquely exhibited additional episodes of transient horizontal diplopia, which was possibly from ocular myokymia or neuromyotonia. Although there are limited data, sodium channel inhibitors (e.g., carbamazepine, oxcarbazepine, and lacosamide) have shown some success to provide symptomatic relief, most likely secondary to their ability to inhibit underlying peripheral nerve hyperexcitability. Our patient was started on lacosamide 50 mg twice a day with a notable decrease in symptom frequency. This case illustrates the importance of detailed clinical and electrodiagnostic studies in making the diagnosis of delayed radiation-induced myokymia with episodic dysarthria and provides guidance on potential therapeutics.

MORE ONLINE

 Video

From the Department of Neurology (A.S.B., A.F., J.M.B., B.R.), Department of Ophthalmology (A.F.), Department of Neurosurgery (J.M.B.), Yale School of Medicine, New Haven, CT. Go to [Neurology.org/N](https://www.neurology.org/N) for full disclosures. Funding information and disclosures deemed relevant by the authors, if any, are provided at the end of the article.

Section 1

A 73-year-old woman presented with transient episodes of slowing and slurring of her speech over the past year. The episodes were brief, lasting for approximately 20–30 seconds before resolving. Initially, they were occurring 1–2 times a week, but the frequency had increased to 10–15 times a week at the time of first evaluation. Episodes could occur at any time of the day without any specific preceding triggers. She also reported transient episodes of horizontal double vision, which would occur independently from her episodes of dysarthria, resolved with closure of 1 eye, and worsened with rightward gaze. She denied any associated fevers, weight loss, headache, dyspnea on exertion, dysphagia, focal weakness, sensory changes, or word-finding difficulties.

She had a retroclival meningioma and went through suboccipital craniectomy, resection, and stereotactic radiosurgery 18 years ago. She also had a left sphenoid meningioma that is being managed conservatively. On examination (Video 1), she had rightward tongue deviation on protrusion with right-sided tongue fasciculations. There was intermittent right eye abduction impairment without nystagmus or ptosis. The rest of the cranial nerves were intact. She had full strength throughout with normal reflexes, and sensory examination was normal. She did not have dysmetria or intention tremor, and gait was normal.

Questions for Consideration:

1. What is the localization for this presentation?
2. What are the differential diagnoses?

GO TO SECTION 2

Section 2

The patient in this vignette presented with recurrent, transient episodes of dysarthria and horizontal diplopia with evidence of right-sided tongue deviation, tongue fasciculations, and impaired abduction of the right eye. The tongue deviation points toward a lesion of the right cranial nerve (CN) XII, and associated fasciculations would favor lower motor neuron involvement. The intermittent impaired abduction of the right eye without any other associated abnormalities of extraocular movements or concomitant facial weakness is suggestive of a focal peripheral lesion of cranial nerve VI. Taken together, these findings suggest multiple cranial neuropathies within the brainstem or subarachnoid space, neuromuscular junction disorder, or myopathy. The intermittent nature of her symptoms raises the possibility of peripheral hyperexcitability as opposed to a fixed structural problem.

When considering the differentials for multiple cranial neuropathies within the brainstem, a single brainstem lesion causing isolated compression of just the right CN VI and XII without additional CN involvement at the same level would be unusual. A treatment effect, such as entrapment of nerve in a surgical scar, or ionizing radiation–induced peripheral hyperexcitability should also be considered.

Multiple cranial neuropathies from extramedullary lesions have wide differential diagnoses, including infectious, inflammatory, and neoplastic etiologies.¹ Relatively chronic presentation, lack of involvement of other cranial nerves, absence of fever, or meningismus made an infectious etiology unlikely. Sarcoidosis and amyloidosis could present with multiple cranial neuropathies, and the slowly progressive presentation could fit with a neuroinvasive process. However, neurologically isolated amyloidosis and sarcoidosis are rare, and there was no suggestion for additional systemic

involvement to support these diagnoses. Similarly, a connective tissue disorder or vasculitis appeared to be unlikely given relatively gradual progression, lack of other CN involvement, and absence of associated systemic features. A neoplastic process affecting the skull base or clivus should be a consideration, particularly with her history of retroclival meningioma; however, as mentioned before, the intermittent nature of symptoms suggested against a fixed structural lesion.^{1,2}

Disorders of the neuromuscular junction were unlikely in the absence of any other symptoms, such as ptosis, proximal weakness, dysphagia, shortness of breath, or autonomic instability. There was no fatigability, and unilateral tongue involvement is also unusual for a neuromuscular junction disorder.

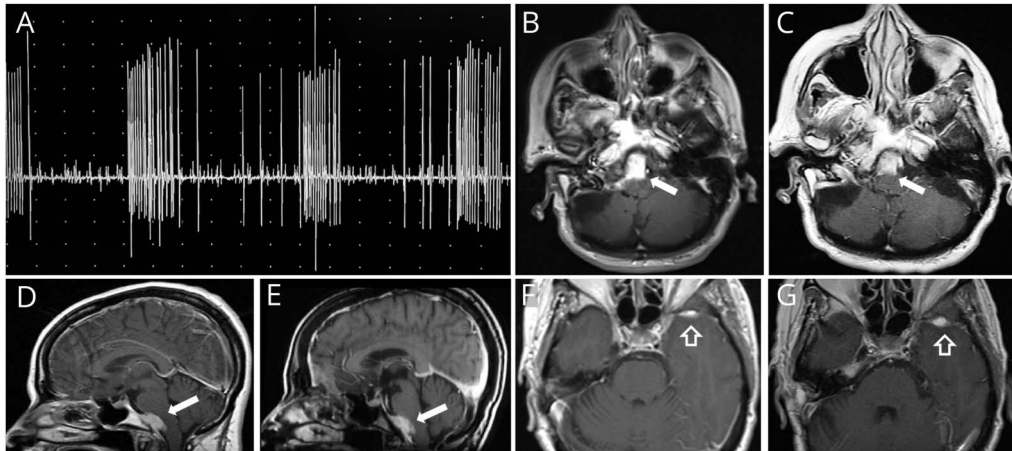
Motor neuron diseases, such as amyotrophic lateral sclerosis (ALS), can present with bulbar predominant findings, but diplopia and episodic symptoms are atypical in ALS. Furthermore, there was no motor weakness or suggestion of upper motor neuron involvement on clinical examination. Although some myopathic processes could present with ophthalmoplegia, isolated dysarthria is unusual in such cases.

Other central causes including transient ischemia, focal seizure, or a migraine with basilar aura were considered but favored to be less likely. Although the patient does have a history of migraine, the frequency of the episodes, brief duration, and lack of associated headache would be less consistent with this diagnosis.

Question for Consideration:

1. What investigations can help to narrow the differential?

GO TO SECTION 3



(A) EMG showing involuntary grouped repetitive discharges of a single motor unit from the right hemitongue, consistent with myokymia. (B–E) Axial and sagittal view of the retroclival meningeioma (white arrow) and (F–G): the left sphenoid meningeioma (blank white arrow) showing stability over 10 years [all MR images are T1-weighted postcontrast images. B, D, and F from 2010; C, E, and G from 2020].

Section 3

The patient underwent MRI of her brain with and without contrast that showed the stability of her left sphenoid meningeioma and right retroclival meningeioma with mild mass effect on the brainstem (Figure, B–G). There was no evidence of acute intracranial infarction, hemorrhage, or meningeal involvement. Magnetic resonance angiography (MRA) of the head and neck did not demonstrate any hemodynamically significant stenosis, occlusion, dissection, or a structural basis for a vascular compression syndrome. EEG did not show electrographic evidence for seizures or epileptiform discharges.

EMG showed spontaneous depolarizations in bursts at rest with a characteristic sound of “marching soldiers” in the right hemitongue, consistent with myokymia (Video 1, Figure, A). The left side of the tongue was normal. Myokymia is a clinical phenomenon characterized by brief bursts of single motor unit potentials firing at rates of 5–150 Hz that may appear as doublets, triplets, or multiplets.³ This burst activity can occur at regular or irregular intervals with a variable interburst

frequency on EMG. The audio description of myokymia has classically been described as “soldier’s marching on snow”. Clinically, myokymia will appear as a wave-like rippling of the muscles on examination.

The causes of focal myokymia include Guillain-Barre syndrome, multiple sclerosis, radiation neuropathy, pontine tumors, neoplastic/inflammatory meningoradiculitis, anoxic/ischemic rhombencephalopathy, syringobulbia, basilar invaginations, and subarachnoid hemorrhage.³ The pathophysiology of peripheral nerve hyperexcitability is thought to be due to ectopic discharges arising from motor neuron axons with compromised myelin sheath integrity.⁴ Given these findings, our patient’s presentation of episodic dysarthria was felt to be most consistent with delayed radiation-induced myokymia. The episodes of diplopia were possibly related to underlying ocular myokymia or neuromyotonia.

Question for Consideration:

1. How would you manage this patient?

GO TO SECTION 4

Section 4

For delayed radiation-induced myokymia, there are limited data available on therapy given the rarity of the syndrome. However, some case reports have noted therapeutic benefit from anti-convulsant medications. Specifically, sodium channel inhibitors (e.g, carbamazepine, oxcarbazepine, and lacosamide) have been used with success largely because of their ability to inhibit the underlying peripheral nerve hyperexcitability.^{5,6} Sodium channel blockers can also be effective in treating ocular myokymia/neuromyotonia.^{7,8}

Our patient was started on low-dose lacosamide, 50 mg twice a day, with notable improvement in the frequency of her symptoms, now occurring only briefly once or twice a month.

Discussion

Transient dysarthria and tongue myokymia from prior radiation have been infrequently reported in the literature. This case was unique with additional concurrent intermittent horizontal diplopia related to lateral rectus myokymia or ocular neuromyotonia.^{4,5,7-13}

Tongue myokymia from previous radiation can have a varied presentation, and symptoms can range from cramping, a sensation of abnormal movements, dysarthria, or dysphagia. The onset of symptoms after radiation treatment can vary between several months to 29 years. Similar to radiation-induced brachial plexopathy, the prior treatment is felt to bring about nerve damage through a combination of nerve fibrosis and localized microvascular ischemic disease.¹⁴ Generally, patients have a moderate response to anticonvulsant medications; however, symptoms are expected to gradually progress over years to decades.⁶

Intermittent episodes of diplopia lasting for seconds to minutes have been reported after cranial radiation either from ocular myokymia or from ocular neuromyotonia.¹³ Ocular myokymia is common in superior oblique muscle, has been reported in inferior oblique muscle, and can be associated with oscillopsia.¹⁵ Ocular neuromyotonia is usually induced by sustained eccentric gaze, with a slower tempo, and mild paresis of affected muscle between episodes is common.^{8,13} In this case, her episodes of diplopia were not triggered by sustained extreme gaze, and there was no fixed paresis of the right lateral rectus between episodes. With the concomitant presence of myokymia in her tongue, ocular myokymia was likely. However, electrodiagnostic characterization was not explicitly performed on the right external rectus, and ocular neuromyotonia remains in the differential. From a pathophysiologic standpoint, both ocular myokymia and neuromyotonia are along the spectrum of neuronal hyperexcitability from ephaptic transmission. Furthermore, ocular myokymia sometimes can transition to ocular neuromyotonia.^{8,13} Electrodiagnostically, the 2 entities are similar; however, the discharges in neuromyotonia occur at

a significantly higher frequency (150–300 Hz) compared with myokymia (5–150 Hz) and may have a degree of waning in amplitude.³ Given similar pathophysiology, both of these conditions can be successfully treated with sodium channel blockers.^{7,13}

Late-onset cranial neuropathies manifesting as myokymia after exposure to ionizing radiation represent challenging neurologic problems. A thorough clinical evaluation serves as the basis for an accurate diagnosis. Detailed electrodiagnostic studies are indispensable for understanding the underlying pathophysiology and devising a treatment plan. Although there is no approved therapy, lacosamide or other sodium channel–modulating anticonvulsants may be beneficial in the appropriate clinical context.

Study Funding

The authors report no targeted funding.

Disclosure

The authors report no disclosures relevant to the manuscript. Go to Neurology.org/N for full disclosures.

Publication History

Received by *Neurology* September 2, 2021. Accepted in final form February 21, 2022. Submitted and externally peer reviewed. The handling editor was Anthony Amato, MD, FAAN.

Appendix Authors

Name	Location	Contribution
Aaron S. Bower, MD	Department of Neurology, Yale School of Medicine, New Haven, CT	Drafting/revision of the manuscript for content, including medical writing for content
Adeniyi Fisayo, MD	Departments of Neurology and Ophthalmology, Yale School of Medicine, New Haven, CT	Drafting/revision of the manuscript for content, including medical writing for content; Major role in the acquisition of data
Joachim M. Baehring, MD	Departments of Neurology and Neurosurgery, Yale School of Medicine, New Haven, CT	Drafting/revision of the manuscript for content, including medical writing for content; Major role in the acquisition of data
Bhaskar Roy, MD	Department of Neurology, Yale School of Medicine, New Haven, CT	Drafting/revision of the manuscript for content, including medical writing for content; Major role in the acquisition of data; Analysis or interpretation of data

References

1. Carroll CG, Campbell WW. Multiple cranial neuropathies. *Semin Neurol*. 2009;29(1):53-65.
2. Probasco JC, Munchel AT, McArthur JC, Blakeley JO. Clinical Reasoning: multiple cranial neuropathies in a young man. *Neurology*. 2013;80(6):e60-6.
3. Gutmann L, Gutmann L. Myokymia and neuromyotonia 2004. *J Neurol*. 2004;251(2):138-142.
4. Tiftikcioglu BI, Bulbul I, Ozcelik MM, Piskin-Demir G, Zorlu Y. Tongue myokymia presenting twelve years after radiation therapy. *Clin Neurophysiol Pract*. 2016;1:41-42.

5. Gerald T, Alemany M, Lozano A, Velasco R. Hypoglossal myokymia presenting as paroxysmal dysarthria following head and neck radiotherapy. *J Neurol Neurosurg Psychiatry*. 2017;88(8):709.
6. Glenn SA, Ross MA. Delayed radiation-induced bulbar palsy mimicking ALS. *Muscle Nerve*. 2000;23(5):814-817.
7. Strupp M, Dieterich M, Brandt T, Feil K. Therapy of vestibular paroxysmia, superior oblique myokymia, and ocular neuromyotonia. *Curr Treat Options Neurol*. 2016;18(7):34.
8. Zhang M, Gilbert A, Hunter DG. Superior oblique myokymia. *Surv Ophthalmol*. 2018;63:507-517.
9. Leupold D, Schilg L, Felbecker A, Kim OC, Tettenborn B, Hundsberger T. Unilateral tongue myokymia - a rare topodiagnostic sign of different clinical conditions. *J Clin Neurosci*. 2017;45:132-133.
10. Liu LH, Chen CW, Chang MH. Post-irradiation myokymia and neuromyotonia in unilateral tongue and mentalis muscles: report of a case. *Acta Neurol Taiwan*. 2007;16(1):33-36.
11. Rison RA, Beydoun SR. Teaching Video NeuroImages: tongue myokymia following head and neck radiotherapy for nasopharyngeal carcinoma. *Neurology*. 2009;72(14):e65.
12. Poncelet AN, Auger RG, Silber MH. Myokymic discharges of the tongue after radiation to the head and neck. *Neurology*. 1996;46(1):259-260.
13. Roper-Hall G, Chung SM, Cruz OA. Ocular neuromyotonia: differential diagnosis and treatment. *Strabismus*. 2013;21:131-136.
14. Warade AC, Jha AK, Pattankar S, Desai K. Radiation-induced brachial plexus neuropathy: a review. *Neurol India*. 2019;67:S47-S52.
15. Chinsky ND, Cornblath WT. Inferior oblique myokymia: a unique ocular motility disorder. *JAMA Ophthalmol*. 2013;131(3):404-405.

Manage Your Career | Recruit Top Talent

The AAN's Neurology Career Center is the largest job site specifically for neurologists. Visit careers.aan.com to find your next hire or search from hundreds of open positions in neurology.

Share Your Artistic Expressions in Neurology 'Visions'

AAN members are urged to submit medically or scientifically related artistic images, such as photographs, photomicrographs, and paintings, to the "Visions" section of *Neurology*®. These images are creative in nature, rather than the medically instructive images published in the NeuroImages section. The image or series of up to six images may be black and white or color and must fit into one published journal page. Accompanying description should be 100 words or less; the title should be a maximum of 140 characters including spaces and punctuation.

Please access the Author Center at Npub.org/authors for full submission information.

Disputes & Debates: Rapid Online Correspondence

The editors encourage comments on recent articles through Disputes & Debates:

Access an article at Neurology.org/N and click on "MAKE COMMENT" beneath the article header.

Before submitting a comment to Disputes & Debates, remember the following:

- Disputes & Debates is restricted to comments about articles published in *Neurology* within 6 months of issue date, but the editors will consider a longer time period for submission if they consider the letter a significant addition to the literature
- Read previously posted comments; redundant comments will not be posted
- Your submission must be 200 words or less and have a maximum of 5 references; the first reference must be the article on which you are commenting
- You can include a maximum of 5 authors (including yourself)

Neurology®

Clinical Reasoning: A 73-Year-Old Woman With Episodic Dysarthria and Horizontal Binocular Diplopia

Aaron S. Bower, Adeniyi Fisayo, Joachim M. Baehring, et al.
Neurology 2022;98:767-772 Published Online before print March 9, 2022
DOI 10.1212/WNL.0000000000200347

This information is current as of March 9, 2022

Updated Information & Services	including high resolution figures, can be found at: http://n.neurology.org/content/98/18/767.full
References	This article cites 15 articles, 4 of which you can access for free at: http://n.neurology.org/content/98/18/767.full#ref-list-1
Subspecialty Collections	This article, along with others on similar topics, appears in the following collection(s): All Neuromuscular Disease http://n.neurology.org/cgi/collection/all_neuromuscular_disease Diplopia (double vision) http://n.neurology.org/cgi/collection/diplopia_double_vision EMG http://n.neurology.org/cgi/collection/emg Radiation therapy-tumor http://n.neurology.org/cgi/collection/radiation_therapytumor
Permissions & Licensing	Information about reproducing this article in parts (figures, tables) or in its entirety can be found online at: http://www.neurology.org/about/about_the_journal#permissions
Reprints	Information about ordering reprints can be found online: http://n.neurology.org/subscribers/advertise

Neurology® is the official journal of the American Academy of Neurology. Published continuously since 1951, it is now a weekly with 48 issues per year. Copyright © 2022 American Academy of Neurology. All rights reserved. Print ISSN: 0028-3878. Online ISSN: 1526-632X.

